

Antioxidant and Anti-inflammatory effect of Graptophyllum pictum (L.) Griff extract Study on SOD and COX-2 serum of experimental hemorrhoids

by Eriawan Agung Nugroho

Submission date: 10-Mar-2022 07:56AM (UTC+0700)

Submission ID: 1780655986

File name: document.docx (76.12K)

Word count: 2669

Character count: 14306



Original Article

Antioxidant and Anti-inflammatory effect of *Graptophyllumpictum* (L.) Griff extract Study on SOD and COX-2 serum of experimental hemorrhoids

Ignatius Riwanto, Eriawan Agung Nugroho, Neni Susilaningsih, Yan Wisnu Prajoko,
Parish Budiono, Sigit Adi Prasetyo, Abu Azhar

Division of Digestive Surgery, Dr. Kariadi General Hospital/Medical Faculty Diponegoro University, Semarang Indonesia

Abstract

p-ISSN: 2301-4369 e-ISSN: 2685-7898
<https://doi.org/10.36408/mhjcm.v7i2.515>

Diajukan: 31 Desember 2019
Diterima: 11 Februari 2020

Afiliasi Penulis:
Divisi Bedah Digestif,
RSUP Dr. Kariadi
Semarang

Korespondensi Penulis:
Abu Azhar
Jl. Dr. Sutomo No. 16, Semarang,
Jawa Tengah 50244,
Indonesia

E-mail:
abuazhar23dr@gmail.com

Background : The 1st, 2nd and small 3rd degree hemorrhoids are non-operatively treated by using anti-inflammatory and plebotonic medicines, high fiber diet and changing lifestyle. *Graptophyllumpictum* (L.) Griff (GP) is potential to be a hemorrhoid medicine (anti-inflammatory and plebotonic medicine) since its anti-inflammatory effect may be related to antioxidant property. The objectives of this study was to elaborate the anti-inflammatory and anti-oxidant effect of GP on experimental hemorrhoid in male Wistar rats.

Methods : A Randomized Controlled Trial Post-test only design in hemorrhoid-like rats using croton oil induced into the anus for 30 seconds each day for 3 consecutive days. 14 Wistar rats were randomly allocated into 2 groups. Group 1 got normal saline solution, while group 2 treated with GPE 100mg/Kg bw for 5 consecutive days. On the 9th experimental day, the blood was drawn for Elisa examination of COX-2 and SOD levels. As COX-2 and SOD normally distributed, pool t-test and product moment correlation was used for statistical analysis.

Results : All of Wistar rats were still alive. COX-2 levels (ng/ml) in the GPE group was 266.28±158.47, was significantly lower compared to control (595.21±68.92) ($p=0.000$). Serum SOD levels (ng/ml) in the GPE was 77.00±11.0, and was significantly higher than the control 28.00±4.00 ($p=0.02$). Correlation between COX-2 and SOD serum level was significantly strong negative correlation ($p=0.000$ and $r=-0.842$)

Conclusion : GPE at a dose of 100 mg/kg bw has antioxidant and anti-inflammatory effects on artificial hemorrhoids through decreased COX-2 levels, and elevated SOD levels. There is a strong negative correlation between SOD and COX-2 serum level.

Keywords : Graptophyllumpictum, hemorrhoids, Croton oil, COX-2, SOD

INTRODUCTION

Hemorrhoid is dilation and prolapse of anal cushion that provide complaints.¹ The main complaints of hemorrhoids are bleeding, the presence of anal lumps, itching and pain.² In Indonesia epidemiological data on hemorrhoids has never been reported.

Hemorrhoid treatment is very much determined by its degree. First, 2nd and small 3rd degrees are managed non-operatively, with high fiber intake, drinking of plenty water and medical treatment.¹⁻⁴ The medical treatment is drug that has anti-inflammatory and plebotonic effects. Micronized purified flavonoid fraction (MPFF) has already been proven to be effective to reduce the hemorrhoid symptoms.^{1,5,6} MPFF has been used extensively worldwide and already exist in Indonesia, but is not included in the national formulary yet.^{7,8}

Review by Singh et al, showed that purple leaf extract is useful as a stimulus for uterine contractions, has alkaline phosphatase enzyme activity against cell culture MC3T3E1 as a marker of osteoblast cell differentiation, inhibits plaque growth in teeth, anti-inflammatory activity, protection activities kidney and anti-diabetes.⁹ However, from above review, it is not mentioned the study regarding the benefits of purple leaves in the treatment of hemorrhoids.^{7,10,11}

Method to produce hemorrhoid in experimental Wistar rat has been done by several authors by using croton oil induction to the anus.^{12,13} By inducing croton oil, there will be an inflammatory processes which will cause increasing of serum COX-2.

This study aims to prove whether purple leaf extract has an antioxidant effect in terms of serum SOD levels and anti-inflammatory effects in terms of COX-2 serum in Wistar rats which were induced by croton oil.

METHODS

This experimental study was used a Randomized Controlled Trial Post-test only design in male Wistar rats that were induced to develop hemorrhoids-like conditions with induction of croton oil on their anus. The animal experimental was done in "Laboratorium Pengkajian dan Penerapan Teknologi"/LPPT (Research and applied technology Laboratory) of University of Gajahmada, Yogyakarta, Indonesia. The Wistar rat provided standard chow diet and housed in each groups at a room temperature (20°C degree) and treatment was conducted in accordance with the Guide for the Care and Use of Laboratory Animals. The animal experimental protocol was approved by Ethical Committee of Faculty of medicine, University of Diponegoro, Dr. Kariadi hospital Semarang Indonesia on September 25th 2017.

The croton oil was provided on line from Sigma Aldrich Company, catalog number C6719-10G. Croton oil for anal application was prepared by mixing

deionized water, pyridine, diethyl ether, and 6% croton oil in diethyl ether at a ratio of 1: 4: 5: 10. Male Wistar rat weight around 200 gr, were divided into 2 groups (each of 7), group I (control) anus was induced with 6% croton oil, 1.5 cm from the anal verge for 30 seconds per day for 3 consecutive days, then given a placebo (physiological saline) on day 4th for 5 consecutive days. Group II (group of purple leaves) induced with 6% croton oil, the same way with the control groups, but after that was given GPE at a dose of 100 mg / kgbw orally, on the day 4th for 5 consecutive days. GPE was prepared by the herbal medicine company, PT Sido Muncul, from purple leaf tree planted in the PT Sido Muncul Farm. On day 9th, blood were taken from retro-orbital and then Wistars were terminated. Blood then directly sent to LPPT for measuring levels of serum COX-2 (ng/ml) and levels of SOD (ng/ml) by means of Elisa. COX-2 and SOD serum were measured by the Elisa method using a ratio measurement scale. All data were ratio-scale and normally distributed so that the analysis carried out was the t-test and Pearson correlation.

RESULTS

Research had been carried out on 14 male Wistar rats, which were divided into 2 treatment groups; control and the group that was given GPE 100 mg / kg bw, each group of 7 rats, and still in good health until the end of the study. The mean (\pm SD) of body weight (gr) of control group was 173.84 (\pm 13.37) and the treatment group was 171.70 (\pm 13.10), and there was no significant differences ($p=0.833$). The COX-2 serum in the GPE group at a dose of 100 mg / kgbw was 266.28 (\pm 158.47) ng/ml, and it was significantly lower in comparison to control group 595.21 (\pm 68.92) ng/ml ($p=0.000$) (Fig. 1).

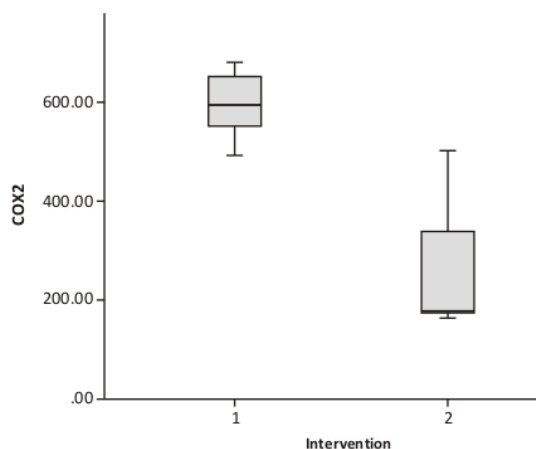


Figure 1. The mean (\pm SD) of COX-2 serum in the GPE group (group 2) was 266.28 (\pm 158.47) and in the control group (group 1) was 595.21 (\pm 68.92) ($p=0.000$)

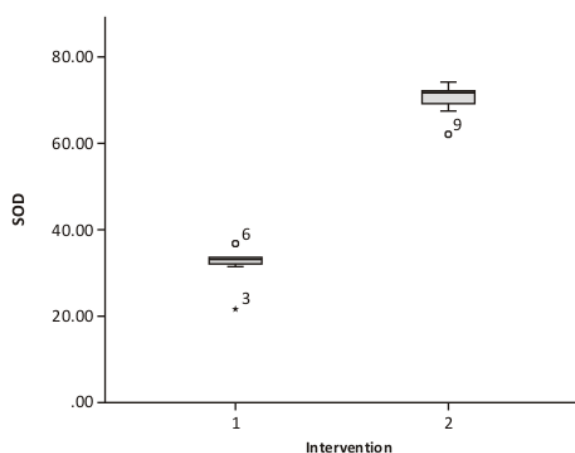


Figure 2. The mean (\pm SD) of SOD serum in the GPE group (group 2) was 77.00 (\pm 11.0), and it controls (group 1) was 28.00 (\pm 4.00) ($p=0.02$)

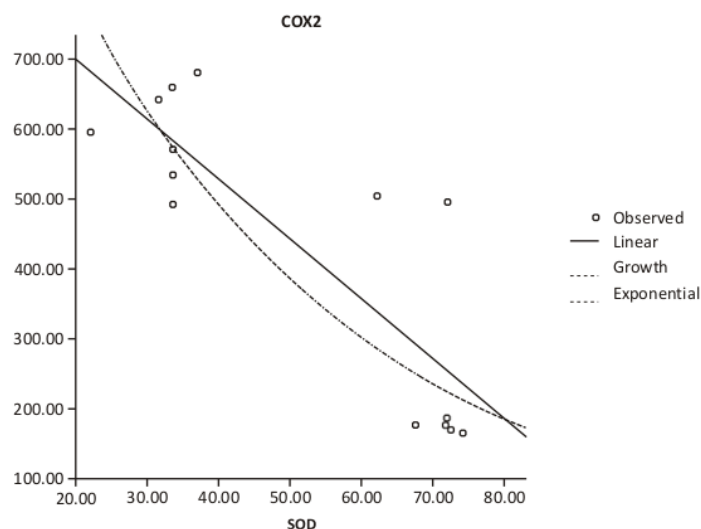


Figure 3. Correlation of COX-2 and SOD serum levels. Pearson correlation $r = -0.842, p = 0.000$

The SOD serum in the GPE group at doses of 100 mg / kgbw (group 2) was 77.00 (\pm 11.0) ng/ml, and it was significantly higher than controls (group 1) 28.00 (\pm 4.00)ng/ml ($p=0.02$) (Fig.2). Assessment of the relationship between COX-2 serum and serum SOD levels was carried out using the Pearson correlation test. The Pearson test revealed a strong negative correlation between COX-2 and SOD serum ($r = -0.842, p=0.000$). Because the value of $p < 0.05$, it was concluded that there was a significant correlation between COX-2 and SOD serum. (Fig3)

DISCUSSION

The phytochemical screening of the leaves of *Graptophyllum pictum* (L.) Griff was carried out using the standard procedures which revealed the presence of flavonoids, steroids, tannins, coumarins, saponins, anthraquinones, phenolics and sugars.¹⁴ Phenolic compounds are known to possess the ability to reduce oxidative damage acting as antioxidants. They can trap the free radicals directly or scavenge them through a series of coupled reactions with antioxidant enzymes.¹⁵

TABEL 1
The percentage yield, total phenolic and flavonoid contents of different fractions of *G. pictum* (L.) Griff. leaves^a

Fractions	%yield (%w/w)	Total phenolic contents (mg GAE/g extract)*	Total flavonoid contents (mg QE/g extract)**
Hexane	36,67	1,69 ± 0,09	28,21 ± 0,04
Ethylacetate	1,36	102,57 ± 0,19	22,45 ± 0,02
Butanolic	31,73	45,33 ± 0,23	9,02 ± 0,04
Aqueous	14,13	16,51 ± 0,16	2,02 ± 0,02

Note : *GAE: gallic acid equivalent, **QE: quercetin equivalent, Values are expressed as means of triplicate determinations ± SD

The phenolics and flavonoids of medicinal herbs contribute to the antioxidant activities of plants, and act as anti-inflammatory agents.¹⁶ Total phenolic and flavonoid levels can be seen in the table below (Table 1).¹⁴ Flavonoids have been evidently used to treat hemorrhoids because it can suppress the progressive symptoms and reduce the pain and inflammation as well as bleedings.¹⁷

The experimental induction of hemorrhoid in Wistar, has already been reported in previous studies by inducing of anus using croton oil.^{12,13} The inflammation is severe in the anorectal area and can be observed, both macroscopically and microscopically. In the control group, the anal area is relatively normal and healthy when compared to animals that receive croton oil which has anorectal bleed and necrosis.¹² In the inflammatory process, secretion from cytokines and growth factors occurs such as changes in beta growth factor, TNF- α , IL-1, IL-6, and Nuclear Factor kappa-light-chain-enhancer of activated B cells (NFkB). Secretion from cytokines and growth factors is a strong COX-2 inducer. During the initial inflammatory process, COX-2 acts as a vasodilator that causes swelling, edema, and pyrogenic effects.¹⁸ COX-2 is a pro-inflammatory enzyme and is the main target in the management of inflammatory diseases.¹⁵ In cases of inflammation that subside, serum COX-2 will also decrease. COX-2 expression was significantly higher in hemorrhoidal tissue than normal rectal mucosa and sub-mucosa.¹⁰ In this study the administration of purple leaf extract at a dose of 100 mg/kg bw was able to reduce serum COX-2 levels significantly lower than positive controls (Figure 1). This shows that the 100 mg/kg bw Purple Leaf Extract has anti-inflammatory effects through COX-2 inhibition.

In the inflammatory process, the tissue need for oxygen will increase, and if not fulfilled there will be a lot of superperoxide (a free radical product) be produced. To overcome the amount of superperoxide the body compensates by increasing the production of SOD which is an antioxidant enzyme that repairs cells and reduces the number of superoxide damage. SOD activity

experienced a significant decrease in recto-anal tissue in animals induced by croton oil.¹² In this study GPE administration at a dose of 100 mg/kgbw was able to increase serum SOD levels significantly higher than controls (Figure 2). This shows that GPE 100 mg/kg body weight has an antioxidant effect through increasing levels of SOD. This is consistent with research conducted by Gurel et al 2013 in Wistar rats using herbal cream (fig leaves + artichoke leaves + walnut skin + chestnut fruit).¹²

In hemorrhoids induced by croton oil there will be an inflammatory process¹² which will cause serum COX-2 which is a pro-inflammatory enzyme to increase.¹⁹ In addition to the increase in serum COX-2, inflammation will cause the formation of free radicals where superperoxide is a free radical that commonly occurs in the human body. With the formation of superperoxide, the body will compensate with the production of SOD. SOD is an enzyme that is antioxidant that repairs cells and decreases the number of damage caused by superoxide. In the inflammatory process, the formation of SOD will increase to accelerate the repair of the inflammatory process.¹² In this study found a strong negative correlation between serum COX-2 and serum SOD levels (Figure 3).

In the study of Faujdar, et al (2018), it shows that the hydroxy alcoholic extract of the skin of *Acacia ferruginea* DC which contains flavonoids and phenol can function as an anti-inflammatory in hemorrhoids induced with croton oil, and also functions as an antioxidant.²⁰

CONCLUSION

Purple Leaf Extract with a dose of 100 mg/kg bw provides an anti-oxidant and anti-inflammatory effect on artificial hemorrhoids which was carried out by anal induction of rats with crotonoil through decreasing COX-2 levels, and increasing SOD levels. There was also found a strong negative correlation between serum levels of SOD and COX-2.

REFERENCE

1. Margetis N. Pathophysiology of internal hemorrhoids. *Annals of Gastroenterology*. 2019;32(3): 264–72
2. Sun Z, Migaly J. Review of Hemorrhoid Disease: Presentation and Management. *Clinics in Colon and Rectal Surgery*. 2016;29(1):22–9
3. Becheanu G. Hemorrhoid. *Pathology of the Gastrointestinal Tract*. 2017; pp.341–344. doi: 10.1007/978-3-319-40560-5_1482
4. Coello A, Mills E, Ansdell H, Yarto L, Zhou Q, Johanson JF, et al. Fiber for the treatment of hemorrhoids complications: a systematic review and meta-analysis. *World J Gastroenterol*. 2016;101(1): 181–8
5. Aziz Z, Huin WK, Hisham B, Tang WL, Yaacob S. Efficacy and tolerability of micronized purified flavonoid fractions (MPFF) for haemorrhoids: A systematic review and meta-analysis. *World J Gastroenterol*. 2018; 19(11): 152–1
6. Brown SR. Haemorrhoids: an update on management. *Chronic Disease*. 2017;8(10): 141–7
7. Puspitasari. Pengaruh pemberian ekstrak daun wungu (*Graptophyllum pictum* GRIFT) dan Pegagan (*Centella asiatica* L) pada penderita wasir di desa Payaman Solokuro Lamongan. Skripsi Program Studi D4 pengobat tradisional, Fakultas Vokasi Universitas Airlangga. 2016 [cited 25 June 25th 2018]. Available from: <http://repository.unair.ac.id/30804/>
8. Hilmarni, Yohana Y, Rosi DH. Uji Toksisitas Ekstrak Daun Wungu (*Graptophyllum pictum*) Terhadap Profil Hematologi Mencit Putih. 2016; 10(4): 225–35
9. Singh P, Khosa RL, Mishra G, Tahseen MA. A phytopharmacological review on *Justicia picta* (Acanthaceae): A well-known tropical folklore medicinal plant. (Review article) *Journal of Coastal Life Medicine*. 2015;3(12):1000–2
10. Sanchez C, Chinn BT. Hemorrhoids. *Clinic In Colon and Rectal Surgery*. 2011 March; 24(1): 5–13
11. Weber D, O'Brien K. Cancer and Cancer-Related Fatigue and the Interrelationships With Depression, Stress, and Inflammation. *Journal of Evidence-Based Complementary & Alternative Medicine*. 2017 Jul; 22(3): 502–12
12. Hashempur MH, Khademi F, Rahmanifard M, Zarshenas MM. An Evidence-Based Study on Medicinal Plants for Hemorrhoids in Medieval Persia. *Journal of Evidence-Based Complementary & Medicine*. 2017 Oct; 22(4): 969–81
13. Koca U, Aka C. Plants used in anatolian traditional medicine for the treatment of hemorrhoid. *Records of Natural Products*. 2017 Jan; 11(3): 235–50
14. Jiangseubchatveera N, Liawruangrath S, Santiarworn D, Pyne SG. Phytochemical screening, phenolic and flavonoid contents, antioxidant and cytotoxic activities of *Graptophyllum pictum* (L.) Griff. *Chiang Mai Journal of Science*. 2017; 44 (1): 193–202.
15. Ruiz-Ruiz JC, Matus-Basto AJ, Acereto-Escoffie P, Segura-Campos MR. Antioxidant and anti-inflammatory activities of phenolic compounds isolated from *Melipona beecheii* honey. *Food Agriculture Immunology*. 2017. doi: 10.1080/09540105.2017.1347148
16. Nile SH, Keum YS, Jalde SS, Patel RV. Antioxidant, anti-inflammatory, and enzyme inhibitory activity of natural plant flavonoids and their synthesized derivatives. *J Biochem Mol Toxicol*. 2018; 32(1)
17. Hashempur MH, Khademi F, Rahmanifard M, Zarshenas MM. An Evidence-Based Study on Medicinal Plants for Hemorrhoids in Medieval Persia. *J Evid Based Complementary Altern Med*. 2017; 22(4): 969–81.
18. Tingting Y, Lao X, Zheng H. Influencing COX-2 Activity by COX Related Pathways in Inflammation and Cancer. *Mini-Reviews in Medicinal Chemistry*. 2016; 16(15): 1230–43
19. Ungaro F, Rubbino F, Danese S. Actors and Factors in the Resolution of Intestinal Inflammation: Lipid Mediators As a New Approach to Therapy in Inflammatory Bowel Diseases. *Front Immunol*. 2017; 8: 1331
20. Faujdar S, Sati B, Sharma S, Pathak AK, Paliwal SK. Phytochemical Evaluation and Anti-Hemorrhoidal Activity of Bark of *Acacia Ferruginea* DC. *J Tradit Complement Med*. 2018; <https://doi.org/10.1016/j.jtcme.2018.02.003>

Antioxidant and Anti-inflammatory effect of Graptophyllum pictum (L.) Griff extract Study on SOD and COX-2 serum of experimental hemorrhoids

ORIGINALITY REPORT

15%

SIMILARITY INDEX

13%

INTERNET SOURCES

9%

PUBLICATIONS

4%

STUDENT PAPERS

PRIMARY SOURCES

1	ro.uow.edu.au Internet Source	4%
2	jcol.elsevier.es Internet Source	3%
3	www.ncbi.nlm.nih.gov Internet Source	3%
4	Mohammad Hashem Hashempur, Fatemeh Khademi, Maryam Rahmanifard, Mohammad M. Zarshenas. "An Evidence-Based Study on Medicinal Plants for Hemorrhoids in Medieval Persia", Journal of Evidence-Based Complementary & Alternative Medicine, 2017 Publication	1%
5	Tingting Yu, Xingzhen Lao, Heng Zheng. "Influencing COX-2 Activity by COX Related Pathways in Inflammation and Cancer", Mini-Reviews in Medicinal Chemistry, 2016 Publication	1%

6	cmjournal.biomedcentral.com Internet Source	1 %
7	digilib.unimus.ac.id Internet Source	1 %
8	opus.lib.uts.edu.au Internet Source	1 %
9	phcogj.com Internet Source	1 %
10	Pradeep Singh, Ratan Lal Khosa, Garima Mishra, Mohd Adil Tahseen. "A phytopharmacological review on Justicia picta (Acanthaceae): A well known tropical folklore medicinal plant", Journal of Coastal Life Medicine, 2015 Publication	<1 %

Exclude quotes On

Exclude matches Off

Exclude bibliography On

Antioxidant and Anti-inflammatory effect of Graptophyllum pictum (L.) Griff extract Study on SOD and COX-2 serum of experimental hemorrhoids

GRADEMARK REPORT

FINAL GRADE

/0

GENERAL COMMENTS

Instructor

PAGE 1

PAGE 2

PAGE 3

PAGE 4

PAGE 5
