

Total occlusion of coronary artery without ST-segment elevation a case series of 'de Winter' electrocardiogram pattern

by Pipin Ardhianto

Submission date: 31-Dec-2021 03:25PM (UTC+0700)

Submission ID: 1736612912

File name: total_oclu_balimed.pdf (821.02K)

Word count: 2023

Character count: 11559

Total occlusion of coronary artery without ST-segment elevation a case series of 'de Winter' electrocardiogram pattern



Destrian Ekoputro Wismiyarso¹, Carina Adriana¹, Arjatya Pramadita Mangkoesoebroto¹, Arman Christiawan¹, Aldila Nila Sulma¹, Lita Hati Dwi Purnami Effendi¹, Pipin Ardhiyanto^{2*}

ABSTRACT

Background: A 'STEMI equivalent' electrocardiogram (ECG) pattern describes an acute thrombotic occlusion of a large coronary artery without ST-segment elevation. This pattern must be recognized and treated with emergent reperfusion therapy. DeWinter syndrome is a special ECG pattern reflecting acute occlusion in the proximal segment of LAD (left anterior descending) coronary artery and a primary percutaneous coronary intervention (PCI) should be performed as early as possible.

Case illustration: We present two patients admitted to the emergency department with symptoms of chest pain. Their ECGs revealed de-Winter T waves and then coronary angiography was performed. Total occlusion in the proximal segment of the LAD coronary artery was observed in both patients, and stents were implanted to the culprit lesion. Both ECG patients show an up-sloping ST-segment depression (STD, >1 mm) starting from the J-point, with symmetrical, tall and significant T-waves in the precordial leads. This ECG pattern indicates a LAD coronary artery obstruction. The 'de Winter' ECG pattern is not mentioned in the ESC guidelines, but it is essential to recognize this rare ECG pattern as the STEMI equivalent, and it must be treated with prompt revascularization therapy.

Conclusion: The 'de Winter' ECG pattern, as other 'STEMI equivalent', must be recognized promptly and treated as soon as possible with emergent reperfusion by percutaneous coronary intervention.

Keywords: De Winter, STEMI equivalent, occlusion, ST-segment depression.

Cite This Article: Wismiyarso, D.E., Adriana, C., Mangkoesoebroto, A.P., Christiawan, A., Sulma, A.N., Effendi, L.H.D.P., Ardhiyanto, P. 2021. Total occlusion of coronary artery without ST-segment elevation a case series of 'de Winter' electrocardiogram pattern. *Bali Medical Journal* 10(1): 347-350. DOI: 10.15562/bmj.v10i1.2166

¹Faculty of Medicine, Universitas Diponegoro, Semarang, Indonesia.

²Department of Cardiology and Vascular Medicine, Faculty of Medicine, Universitas Diponegoro – Dr. Kariadi Central General Hospital Semarang, Indonesia.

*Corresponding author:

Pipin Ardhiyanto;
Department of Cardiology and Vascular Medicine, Faculty of Medicine Diponegoro University – Dr. Kariadi Central General Hospital Semarang, Indonesia;
pipin.ardhiyanto@gmail.com

Received: 2021-01-12

Accepted: 2021-04-20

Published: 2021-04-30

BACKGROUND

A 'STEMI equivalent' electrocardiogram (ECG) pattern describes an acute thrombotic occlusion of a large coronary artery without ST-segment elevation. This pattern must be recognized and treated with emergent reperfusion therapy. De Winter syndrome is a special ECG pattern reflecting acute occlusion in the proximal segment of LAD (left anterior descending) coronary artery and a primary percutaneous coronary intervention (PCI) should be performed as early as possible.¹

CASE ILLUSTRATION

Case 1

A 57-year-old male patient without cardiac disease history was admitted to referral hospital for acute onset of chest pain. Patient's risk factor for coronary artery

disease is hypertension. ECG at 30-minute after symptom onset (Figure 1) showed significant ST-segment depression at the J point in leads V4-V6 with tall, positively symmetrical T waves and slight ST-segment elevation (0.1 mm) in the aVR lead. The patient developed ventricular fibrillation and managed by defibrillation in the first medical contact hospital. The patient was referred to our hospital for primary percutaneous coronary intervention (PCI). When the patient arrived in our hospital, he was hemodynamically stable and physical examination revealed no abnormalities. Serial ECG showed normal sinus rhythm with normalization of the ST depression. Urgent coronary angiography showed total occlusion in the proximal LAD coronary artery (Figure 2). The percutaneous coronary intervention was performed with three drug-eluting stents

resulted from TIMI-2 graded flow. No complication after the procedure and he was discharged five days later.

Case 2

A 54-year-old former smoker known for hypertension was admitted to our emergency department with acute typical chest pain. Physical exam and vital signs were normal. The ECG performed 4 hours after the onset of the chest pain showed tall symmetric T waves in the precordial leads with ST-segment depression in lead V3-V6 and ST elevation 1mm in aVR (Figure 3). Total occlusion in proximal LAD can be seen from the urgent coronary angiography (Figure 4). One drug-eluting stent was implanted in the culprit lesion during percutaneous coronary intervention and it has resulted from TIMI-3 graded flow. No complication developed in the hospital

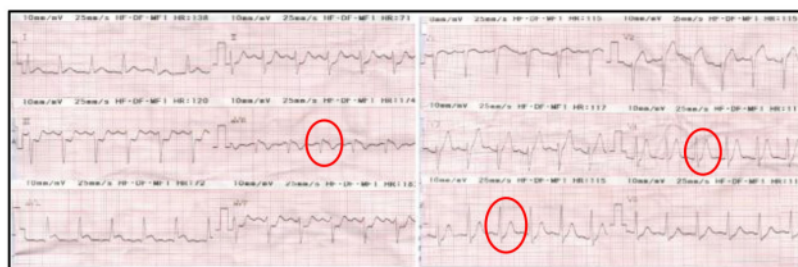


Figure 1. De Winter ECG pattern in the 1st case.

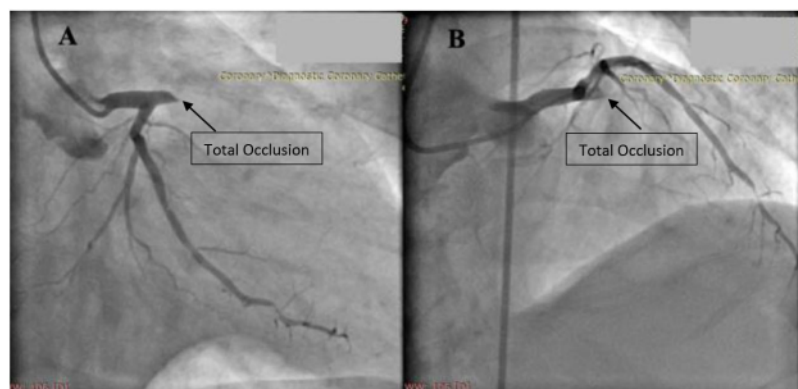


Figure 2. Proximal left anterior descending coronary artery occlusion in right oblique anterior caudal view (A) and cranial view (B).

after the procedure and the patient was discharged seven days later.

DISCUSSION

The acute coronary syndrome can occur even though the ECG is totally normal. The patient's symptoms such as severe chest pain are more critical than ECG findings.² De Winter, in 2008, identified specific T waves in ECG which were almost always reflected a proximal LAD occlusion. According to this definition, de Winter T waves were defined as "up-sloping ST depression and symmetrical long and distinct T waves starting from J-point in precordial leads".³ Both ECG's patients showed an up-sloping ST-segment depression (STD, >1 mm) starting from the J-point, with symmetrical, long and significant T-waves in the precordial leads. This ECG pattern indicates a left anterior descending (LAD) artery obstruction.³

The explanation for total occlusion in LAD without ST-segment elevation because the area of transmural ischemia

was very large, such that no injury currents were generated towards the precordial leads, it only directed upwards to standard lead aVR. Theoretically, the described ECG pattern could have resulted from an anatomical variant of the Purkinje fibers with endocardial conduction delay. An alternative explanation may be related to the lack of activation of sarcolemma adenosine triphosphate (ATP)-sensitive potassium (KATP) channels by ischemic ATP depletion.⁴

However, the most probably pathophysiologic background of the de Winter pattern because there is regional subendocardial ischemia with myocardial protection through collateral circulation or ischemic preconditioning or existing forward flow. The up-sloping STD as well as the tall, peaked T waves are physiologically attributed to a—hypoxia-driven—alteration in ATP-dependent potassium channel. It results in a repolarization delay in the subendocardial region, with a change in the transmembrane action

potential shape.⁵

Based on the behavior of the subendocardial action potentials (AP) compared to the subepicardial AP and subendocardial localization of the ischemia, an explanation of this ECG pattern is offered (Figure 5). From the left panels, the normal situation of activation of the anteroapical area before the posterolateral part of the left ventricle. It produces an rS configuration of the QRS complex (upper and lower panel). The differences in AP of the subendocardial and subepicardial (middle panel) explains QRS complex, ST segment, and T wave configurations. The subendocardial AP starts earlier and ends later than the epicardial AP, resulting in voltage differences, explaining the QRS complex and T wave in the surface ECG (lower panel). The lack of voltage difference during the plateau phase of the AP results in isoelectric ST segment.⁶

From the right panels, ischemic changes result in (1) a positive shift of the baseline, leading to apparent ST depression due to the recording mode of an A-C coupled amplifier; (2) QS wave and a notch due to conduction slowing over the subendocardial with initial activation of the opposite wall and late activation of the anterior subepicardial. It was depicted as positive interruption of the negative deflection; (3) negative voltage difference between the subendocardial and subepicardial AP during the plateau phase leading to ST depression; and (4) shorter time duration between subendocardial and subepicardial repolarization leading to a peaked T wave (a similar amount of tissue being repolarized within a shorter period of time).⁶

Both patients examined here displayed a typical de Winter ECG pattern. This ECG pattern may present in approximately 2% of patients with acute anterior myocardial infarction.⁴ This ECG pattern is always associated with a culprit vessel located in the proximal segment of the LAD artery. Therefore, these patients should be treated immediately with reperfusion therapy, preferably with primary PCI.⁷

There are several conditions in which an urgent revascularization therapy should be done without ST-segment elevation in ECG. These include the newly developed

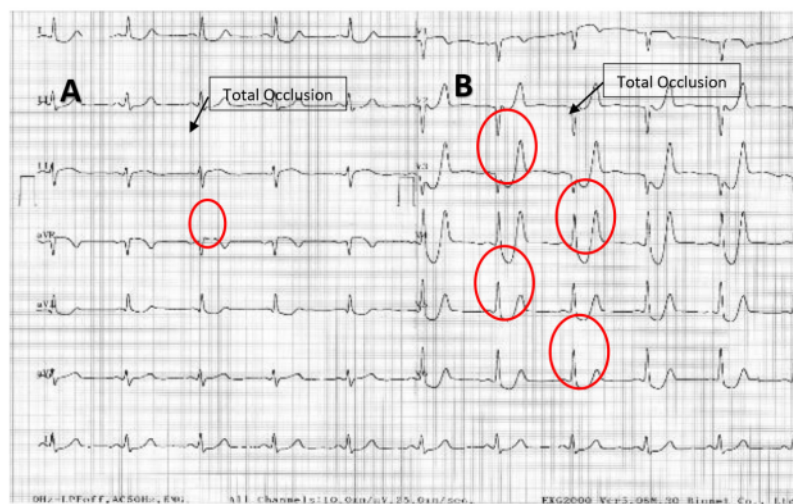


Figure 3. De Winter ECG pattern in the 2nd case.

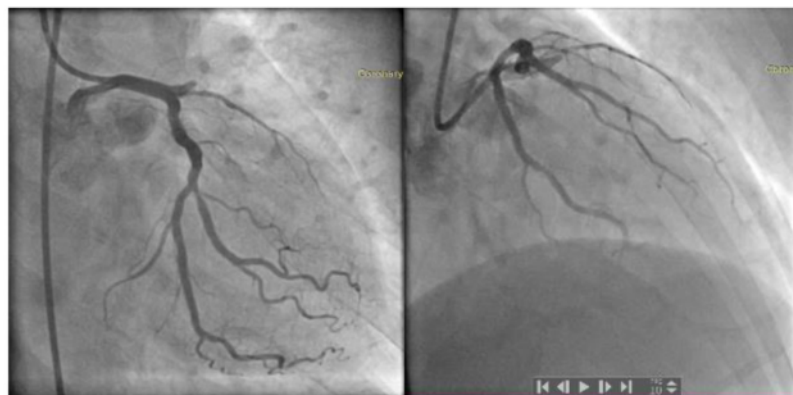

Figure 4. Proximal left anterior descending coronary artery occlusion in right oblique anterior caudal view (A) and cranial view (B).

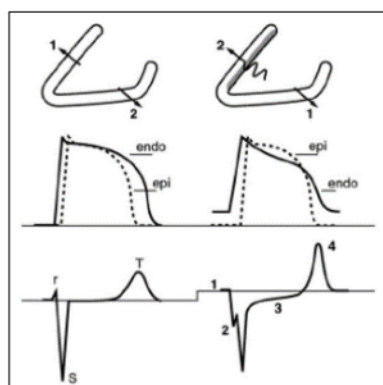


Figure 5. Diagrams explaining the ECG behavior during normal and subendocardial located ischemic conditions.⁶

left bundle branch block (LBBB), old LBBB patient with the presence of Sgarbossa criteria, ST depression in 6 or more derivations and ST elevation in aVR due to left main coronary artery occlusion, Wellens syndrome, and de-Winter T waves.³

In patients presenting with anginal syndrome, ST-segment depression and peaked T waves, combined with the absence of classic ST-segment elevation in the precordial leads of the 12-lead ECG, suggest that this patient has a significant occlusion in LAD coronary. It is important to identify this distinct ECG pattern; timely investigation and revascularization of the LAD coronary artery are then possible.⁸ The de Winter ECG pattern

is not mentioned in the ESC guidelines, but it is important to recognize this rare ECG pattern that needs to be treated, as other STEMI equivalent, with prompt revascularization therapy.¹

CONCLUSION

The de Winter ECG pattern, as other STEMI equivalent, must be recognized promptly and treated as soon as possible with emergent reperfusion by percutaneous coronary intervention.

DISCLOSURE

This report has been presented on 29th Annual Scientific Meeting of Indonesian Heart Association (ASMIHA) in 23-25 October 2020 and included in the proceeding abstract.

FUNDING

None.

CONFLICT OF INTEREST

The author declares there is no conflict of interest regarding publication of the case report.

ETHICAL CONSIDERATION

All patients had received signed informed consent regarding publication of their respective medical data in medical journal.

AUTHOR CONTRIBUTION

All author had contribute equally for writing the original draft and agreed for the final version of the manuscript for publication.

REFERENCES

1. Iglesias JF, Degrauwe S, Tessitore E. The 'de Winter' electrocardiogram pattern as a ST-elevation myocardial infarction equivalent: a case report. *Eur Heart J*. 2019;3(4):1-5. doi:10.1093/ehjcr/ytz210
2. Addison D, Grady KL, Green LA, Jurgens CY. AHA/ACC Clinical Performance and Quality Measures for Adults With ST-Elevation and Non - ST-Elevation Myocardial Infarction. *J Am Coll Cardiol*. 2017;70:2048-2090.
3. Emin M, Turgay Ö, Acar N, Ugur K. Evaluation of acute anterior myocardial infarction cases with de-Winter T waves

- by coronary angiography images. Turkish J Emerg Med. 2019;19:83–86.
4. Verouden NJ, Koch KT, Peters RJ, Henriques JP, Baan J, van der Schaaf RJ, Vis MM, Tijssen JG, Piek JJ, Wellens HJ, Wilde AA, de Winter RJ. Persistent precordial “hyperacute” T-waves signify proximal left anterior descending artery occlusion. Heart. 2009;95:1701-1706. doi:[10.1136/hrt.2009.174557](https://doi.org/10.1136/hrt.2009.174557).
 5. Zhan ZQ, Li MS, Han MS, Nikus KC, Birnbaum Y, Baranchuk A. The de Winter ECG pattern: Distribution and morphology of ST depression. 2009. Ann Noninvasive Electrocardiol. 2020;25:e12783. doi:[10.1111/anec.12783](https://doi.org/10.1111/anec.12783).
 6. Gorgels AP. Explanation for the electrocardiogram in subendocardial ischemia of the anterior wall of the left ventricle. J Electrocardiol. 2009;42(3):248-9. doi: [10.1016/j.jelectrocard.2009.01.002](https://doi.org/10.1016/j.jelectrocard.2009.01.002).
 7. Dai X, Kaul P, Smith SC Jr, Stouffer GA. Predictors, treatment, and outcomes of STEMI occurring in hospitalized patients. Nat Rev Cardiol. 2016;13(3):148-54. doi: [10.1038/nrcardio.2015.165](https://doi.org/10.1038/nrcardio.2015.165).
 8. Goktas MU, Sogut O, Yigit M, Kaplan O. A Novel Electrocardiographic Sign of an ST-Segment Elevation Myocardial Infarction-Equivalent: De Winter Syndrome. Cardiol Res. 2017;8(4):165-168. doi: [10.14740/cr576w](https://doi.org/10.14740/cr576w).



This work is licensed under a Creative Commons Attribution

Total occlusion of coronary artery without ST-segment elevation a case series of 'de Winter' electrocardiogram pattern

ORIGINALITY REPORT

1 %	0 %	1 %	0 %
SIMILARITY INDEX	INTERNET SOURCES	PUBLICATIONS	STUDENT PAPERS

PRIMARY SOURCES

1	Samadov, Fuad, Dursun Akaslan, Altug Cincin, Kursat Tigen, and Ibrahim Sari. "Acute proximal left anterior descending artery occlusion with de Winter sign", The American Journal of Emergency Medicine, 2013.	1 %
	Publication	
2	P J Sheridan. "Critical review of unstable angina and non-ST elevation myocardial infarction", Postgraduate Medical Journal, 2002	<1 %
	Publication	

Exclude quotes	Off	Exclude matches	Off
Exclude bibliography	Off		

Total occlusion of coronary artery without ST-segment elevation a case series of 'de Winter' electrocardiogram pattern

GRADEMARK REPORT

FINAL GRADE

/0

GENERAL COMMENTS

Instructor

PAGE 1

PAGE 2

PAGE 3

PAGE 4