

F1000Research Topical Coconut Oil

by Niken Safitri Dyan Kusumaningrum

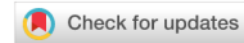Submission date: 24-Mar-2022 09:25AM (UTC+0700)

Submission ID: 1791443525

File name: Topical_Ozonized_Coconut_Oil.pdf (3.67M)

Word count: 12553

Character count: 66513



RESEARCH ARTICLE

REVISED Topical ozonated virgin coconut oil improves wound healing and increases HSP90 α , VEGF-A, EGF, bFGF, and CD34 in diabetic ulcer mouse model of wound healing [version 3; peer review: 1 approved with reservations, 1 not approved]

Renni Yuniati ¹, Prasetyowati Subchan¹, Wibi Riawan², Matthew Brian Khrisna³, Maryam Restiwijaya⁴, Niken Safitri Dyan Kusumaningrum ⁵, Muhammad Nur ⁴

¹Department of Dermatology and Venereology, Faculty of Medicine, Diponegoro University, Semarang, Central Java, 50275, Indonesia

²Department of Biochemistry, Faculty of Medicine, Brawijaya University, Malang, East Java, 65145, Indonesia

³Faculty of Medicine, Diponegoro University, Semarang, Central Java, 50275, Indonesia

⁴Center of Plasma Research, Faculty of Science and Mathematics, Diponegoro University, Semarang, Central Java, 50275, Indonesia

⁵Department of Nursing, Faculty of Medicine, Diponegoro University, Semarang, Central Java, 50275, Indonesia

V3 First published: 09 Jun 2020, 9:580
<https://doi.org/10.12688/f1000research.22525.1>

Second version: 06 May 2021, 9:580
<https://doi.org/10.12688/f1000research.22525.2>

Latest published: 23 Sep 2021, 9:580
<https://doi.org/10.12688/f1000research.22525.3>

Abstract

Background: Diabetes is a disease that affects people worldwide, including in Indonesia. The prevalence of diabetes in Indonesia is increasing from year to year. One of the most devastating complications of diabetes mellitus is diabetic ulcers, which is a limb-threatening complication. Over the past few decades, ozone generated using plasma medical technology has been investigated as an agent that helps wound healing. This study aims to evaluate the effects of topical ozonated virgin coconut oil (VCO) in a diabetic wound mouse model.

Methods: This study was an experimental study with a post-test control design. An ulcer wound model was made in 50 diabetic male Wistar mice, divided into five groups, and a control group of 10 non-diabetic mice. The control groups were given conventional therapy only and the treatment groups were also given topical ozonated VCO with different flow durations (0 min, 90 min, 7 h, 14 h). Macroscopic appearance and wound contraction were observed. HSP90 β , VEGF-A, EGF, bFGF, and CD34 levels were measured from the immunostained slices of wound margins.

Results: The reduction of wound length was proportionally related to the duration of ozone flow. Ozonated VCO with a longer duration of ozone flow healed the wound more quickly and had the shortest

Open Peer Review

Reviewer Status ? X

Invited Reviewers

1

2

version 3

(revision)
23 Sep 2021

version 2

(revision)
06 May 2021

?

report

X

report

↑

version 1

09 Jun 2020

?

report

1. Gamal Badr , Assiut University, Assiut, Egypt

2. Rekha Raghuveer Shenoy , Manipal Academy of Higher Education, Manipal, India

Any reports and responses or comments on the article can be found at the end of the article.


wound length. VCO with ozone flow for 14 hours (16837.10 μm) had the biggest reduction in wound length compared to other groups. The wounds treated with ozonated VCO showed an increase in HSP90 β , VEGF-A, EGF, bFGF, and CD34 levels that correlated to improved wound healing. A longer period of treatment resulted in higher levels of wound healing biomarkers compared to shorter therapeutic durations.

Conclusions: Topical ozonated VCO improved the wound healing process in a diabetic ulcer mouse model by improving macroscopic wound appearance and increasing levels of wound healing biomarkers.

Keywords

diabetic ulcer, ozone, virgin coconut oil, full-thickness wound, delayed wound healing, HSP90 α , VEGF-A, EGF, bFGF, CD34

Corresponding author: nni Yuniati (renniyuniati@yahoo.com)

Author roles: **Yuniati R:** Conceptualization, Data Curation, Methodology, Project Administration, Supervision, Validation, Writing – Review & Editing; **Subchan P:** Conceptualization, Data Curation, Formal Analysis, Investigation, Methodology, Project Administration, Resources, Supervision, Validation, Writing – Review & Editing; **Riawan W:** Data Curation, Investigation, Methodology, Supervision, Validation; **Khrisna MB:** Data Curation, Investigation, Validation, Writing – Original Draft Preparation, Writing – Review & Editing; **Restiwijaya M:** Data Curation, Formal Analysis, Investigation, Project Administration, Resources, Validation, Visualization; **Dyan Kusumaningrum NS:** Conceptualization, Data Curation, Formal Analysis, Investigation, Methodology, Project Administration, Visualization; **Nur M:** Conceptualization, Data Curation, Formal Analysis, Investigation, Methodology, Project Administration, Resources, Supervision, Validation 

Competing interests: No competing interests were disclosed.

Grant information: The author(s) declared that no grants were involved in supporting this work.

Copyright: © 2021 Yuniati R *et al.* This is an open access article distributed under the terms of the [Creative Commons Attribution License](#), which permits unrestricted use, distribution, and reproduction in any medium, provided the original work is properly cited.

How to cite this article: Yuniati R, Subchan P, Riawan W *et al.* Topical ozonated virgin coconut oil improves wound healing and increases HSP90 α , VEGF-A, EGF, bFGF, and CD34 in diabetic ulcer mouse model of wound healing [version 3; peer review: 1 approved with reservations, 1 not approved] F1000Research 2021, 9:580 <https://doi.org/10.12688/f1000research.22525.3>

First published: 09 Jun 2020, 9:580 <https://doi.org/10.12688/f1000research.22525.1>

REVISED Amendments from Version 2

Revised grammar, wording and punctuations

Revised "Animals" section

Revised methods (Incision)

Revised Results related to the number of rats that died before the end of the study

Any further responses from the reviewers can be found at the end of the article**Introduction**

Diabetes is a non-communicable disease that has become a worldwide burden. In 2014, the number of people with diabetes in the world reached 8.5% of the total world population. According to a WHO report, the prevalence of diabetes has kept increasing steadily for the last three decades, especially in low-income and middle-income countries such as Indonesia¹. In 2013, the prevalence of diabetes mellitus among productive-age citizens of Indonesia was 4.6%². In line with the WHO report, the International Diabetes Federation found that in 2017, the prevalence of diabetes mellitus among adults in Indonesia had increased to 6.7%.

Diabetes is a risk factor and cause of several other diseases, including blindness, kidney failure, diabetic neuropathy, diabetic vasculopathy, and diabetic ulcers. Of those diabetic patients, 15% of them will develop a diabetic ulcer. If the diabetic ulcer is not managed properly, it can develop into gangrene, thus increasing the likelihood of amputation. 12–24% of patients who have diabetic ulcers end up requiring amputation^{3–6}.

Diabetic ulcers are a serious complication in patients with diabetes⁷. A diabetic ulcer is defined as the presence of a full-thickness lesion located distally relative to the ankle. Diabetic ulcers are caused by a combination of several risk factors, including neuropathy, peripheral arterial occlusive disease, and previous ulcerations^{7,8}. Of all diabetic patients worldwide, 6.3% are affected by diabetic ulcers⁹. Diabetic ulcers are limb-threatening conditions that can potentially result in the amputation of a limb^{1,7}.

The management of diabetic ulcers needs a holistic approach, taking into consideration systemic conditions, complications of neuropathy or atherosclerosis, and classification of injuries. Treatment of diabetic ulcer wounds involves three stages, consisting of cleansing, debridement, and dressing. Besides, pressure control and infection control are also needed. Ulcers can become an area of bacterial growth that must be treated with antibiotics according to the results of bacterial culture^{13–15}.

Virgin coconut oil (VCO) is a product of coconut that is produced by processing fresh coconuts at a low temperature. This processing method keeps important substances in the coconut oil intact and ensures they do not degrade. VCO mainly contains 90% saturated fatty acids and 10% unsaturated

fatty acids. VCO contains antioxidants such as tocopherol and beta carotenes and has properties to enhance moisturization of the skin¹⁶. VCO has been shown to increase wound contraction rate in chronic wounds that exhibited delayed wound healing, and have the potential to increase wound healing biomarker levels in a full-thickness wound mouse model^{17,18}.

Ozone is an inorganic triatomic molecule composed of three oxygen atoms and is highly soluble^{19,20}. Ozone is known to have a role in protecting the ecological balance of the earth and can interact at a basic level with industrial pollutants. Ozone also has a unique biological ability that has the potential to be used in the medical field. Medical uses of ozone use ozone dissolved in water (ozonated water), ozonated oils, and ozone in gas form²¹. Previous studies found that ozone acts as an agent that helps ulcer wound healing in patients with diabetes mellitus. Ozone interactions with skin tissue can: cause inactivation of bacteria, viruses, and fungi; stimulate antioxidant production; reduce blood and plasma viscosity; increase erythrocyte membrane fluidity; loosen tissue; stimulate hemoglobin activity and increase oxygen absorption and release; improve blood circulation to tissues; induce tissue collagen formation; activate the formation of granulation tissue; accelerate epithelialization; and increase the phagocytic activity and activation of fibroblasts. Ozone also supports the treatment of diabetes mellitus through decreasing blood sugar levels and increasing oxygen supply into the tissues^{24–26}.

Heat shock protein 90 (HSP90) is a protein chaperone released and upregulated from pancreatic beta cells under inflammatory conditions²⁷. HSP90 is a member of the heat shock protein superfamily and itself consists of HSP90 α and HSP90 β ²⁸. HSP90 is excreted when normal cells are injured and heat shock proteins, especially HSP90 α , are essential for the early phase of wound healing because they promote keratinocyte differentiation, re-epithelialization, dermal cell recruitment, and also protect tissues from further injury^{29–31}. Vascular endothelial growth factor (VEGF) has an important role in the coordination of wound healing³². VEGF-A exhibited misregulation in diseases with microvascular disorders³³. Diabetes causes reduced VEGF signaling, alongside impaired angiogenesis and decreased collateral blood vessel formation³⁴. Besides causing microvascular and macrovascular disorders, this impaired angiogenesis also has a significant role in the pathogenesis of diabetic wound healing³⁵. Increased VEGF-A is beneficial in diabetic wound healing by increased angiogenesis, vessel diameter, re-epithelialization, and wound closure³⁶. Epidermal growth factor (EGF) plays an important role in wound healing through stimulation, proliferation, and migration of several types of cells, such as keratinocytes, epithelial cells, endothelial cells, and fibroblasts, thus facilitating dermal regeneration^{37,38}. EGF is synthesized in the pancreas, and its levels are decreased in diabetic animal models³⁸. Increased EGF levels might have several benefits for wound healing in diabetic wounds and ulcers by increasing granulation tissue formation in diabetic wounds^{39–41}. Basic fibroblast growth factor (bFGF) aids in wound healing⁴². bFGF influences chemotaxis, cell differentiation, cell proliferation, and tissue regeneration, and was found to increase epithelial wound healing

in an early study^{43,44}. CD34⁺ is a biomarker that can be used to predict the healing of diabetic wounds. CD34⁺ levels are decreased in subjects with diabetes compared to subjects with normal glucose tolerance, and lower levels of CD34⁺ are also correlated with a significantly higher risk of diabetes^{46,47}. Levels of sphingosylphosphorylcholine (SPC) in the bloodstream can be used to predict the healing of diabetic neuropathic wounds, which might show its significance in improving the healing of diabetic wounds⁴⁸.

Currently, there are limited studies of ozone treatment in animal models of diabetic ulcers and a lack of clinical trials concerning the efficacy of ozone treatment for ulcers in patients with diabetes mellitus, especially in Indonesia. We used VCO as the ozone carrier liquid in this study. This study aims to evaluate the effect of topical ozonated VCO using a diabetic wound rat model, assessed by macroscopic wound improvement and immunohistochemical staining parameters.

Methods

Ethical statement

This study is an experimental study with a post-test control design. This research was approved and declared ethically feasible by the Ethics Commission of the Public Health Faculty, Diponegoro University Semarang with ethical clearance number 078/EC/FKM/2018. All efforts were made to ameliorate harm to animals by administering anesthesia to all of the study animals before full-thickness wound model creation, keeping the animals in a well-maintained cage, and ensuring graceful termination of animals (using cervical dislocation procedure) before we took tissue samples for a histopathology examination.

Animals

The animals used in this study were male adult laboratory rats (Wistar strain). The rat was three months in age with a mean weight of 250 ± 50 grams. We obtained the rat from a local laboratory-grade rat breeder, with a pure-breeding status. The rat included in this study fulfilled the inclusion criteria for healthy conditions (active movement), and exhibited no signs that met our exclusion criteria: behavioral changes (activities seemed weak and lazy). The choice of rat strain and size is related to the wound model creation; the large size of the Wistar rats enables us to have an ample area on the rat back to create the full-thickness wound model. The rats were kept in stainless-steel laboratory-grade mouse cages at a constant room temperature of $28.0 \pm 2.0^\circ\text{C}$, which was monitored with a digital thermometer. The rat was kept in our laboratory mouse room in cages with wood shavings as the bedding material, which was changed once a week. Each cage was inhabited by two to three rats according to the cage size. We did not mix rats from different groups in one cage. Fluorescent lighting was turned on for 12 hours per day between 9.00 AM to 9.00 PM, with adequate *ad libitum* food supply (BioFeed pellets, manufactured by *Karunia Kasih Abadi*, Klaten, Indonesia) and water supply (clean drinkable water). We routinely assessed the clinical and behavioral status of the rat every day during routine checks to prevent any clinical or behavioral changes in the laboratory rat. No rats were found dead, having decreased

appetite/growth, or exhibited behavioral changes during the study period.

In the diabetic group, we induced type 1 diabetes in the rat by injecting a single dose of 40mg/kg body weight streptozotocin, dissolved in a buffer solution of 50 mM citrate with a pH of 4.5 to obtain a final concentration of 40 mg/ml. We assessed the blood glucose level before streptozotocin injection as a baseline value and repeated 10 days after streptozotocin injection to determine whether the diabetic induction was successful or not. The measurements of blood glucose levels were done using glucose oxidase phenol 4-aminoantipyrine (GOD-PAP) obtained from Diagnostic Systems International. The diagnosis of type 1 diabetes was made if blood glucose levels reached more than 200 mg/dl (11.1 mmol/liter) 10 days after streptozotocin injection, or if blood glucose levels reached twice the baseline blood sugar noted at the time of injection. The average blood glucose in the diabetic rats measured before the wound infliction was 245 mg/dl.

1

Production of ozonated VCO

The manufacture and testing of ozonated VCO were carried out at the Plasma Research Center (PRC), Diponegoro University, Indonesia. The tools used for making ozonated oil were ozone generators (ozone generator manufactured in-house by Plasma Research Center, Diponegoro University) and magnetic stirrers. The ozone outlet is connected to an anti-oxidation hose with a diffuser, which served to increase the effectiveness of ozone absorption in the oil. Magnetic stirrers were used to facilitate the ozone dissolving process into the oil. The oil used in this study was VCO. Ozone was dissolved into VCO with a volume of 100 ccs in each cycle and an oxygen flow rate of 0.1 liters/minute with an ozone concentration of 3360 ppm. We varied the duration of the ozonation process to create several concentrations of ozonated oil. The duration of ozonation was 90 minutes, 7 hours, and 14 hours.

Experimental procedure

The full-thickness wound model, treatment application, and observation were done simultaneously on all study groups; however, the diabetic induction was conducted 10 days earlier before the wound model creation to make sure all rats were ready to undergo wound model creation simultaneously in their final state (diabetic or non-diabetic according to the group). The research process began by inducing the diabetic ulcers in the Wistar rat in the diabetic group. We soaked cotton with 0.05ml of chloroform and put the cotton into a glass beaker containing a mouse. This allowed us to carry out aerosol administration of anesthesia in a similar manner to anesthesia aerosol gas administration in humans who underwent surgery, which we applied for two minutes. The administration of anesthesia was carried out directly before we excised the wounds, at our laboratory mouse surgery table, which was cleaned and sanitized before the process began to minimize the risk of contamination from the surgical field or surgical apparatus. After hypoesthesia was achieved (measured by loss of muscular tone, loss of righting and palpebral reflexes, decreased rate of respiration, and loss of response to painful stimulation), the hair in the

region of the spine at the top of the back (thoracolumbar area) was shaved⁴⁹. Then we made four incisions, each with a diameter of 6 mm, separated by the median line. The full-thickness skin incision was done using punch biopsy with a depth of 1 mm.

A total of 60 rats were used in this research. The sample was then divided into six groups randomly (achieved by simple randomization), where each group consisted of 10 rats. The minimum sample size for this study was obtained according to the Frederer sample size calculation formula: $(t-1)(n-1) \geq 15$; where t = number of groups and n = number of replications/number of minimum samples per group. There are six groups in this study; therefore, the formula was $(6-1)(n-1) \geq 15$, which results in $5n \geq 20$. We added more rats (twice the sample amount) due to the need to obtain three rats for every histopathology examination, which was done three times during the study (explained in the next section). These groups were: the negative control group (C-), a control group of rat with negative diabetes mellitus status that received conventional treatment such as washing the wound with normal saline and gentamycin antibiotic ointment (Kimia Farma pharmaceutical industry, Indonesia); the positive control group (C+), a control group with positive diabetes mellitus status that received similar conventional treatment to the negative control group, such as washing the wound with normal saline and gentamycin antibiotic ointment (Kimia Farma pharmaceutical industry, Indonesia); the first treatment group (P1), which received normal saline wound wash and non-ozonated VCO treatment; the second treatment group (P2), which received normal saline wound wash and 90-minute ozonated VCO oil therapy; the third treatment group (P3), which received normal saline wound wash and 7-hours ozonated VCO oil therapy; and the fourth treatment group (P4), which received normal saline wound wash and 14-hours ozonated VCO oil therapy.

We applied the oils (ozonated VCO or regular VCO according to the group) to the wound once a day in the morning (approximately 8 a.m or 9 a.m) for fourteen consecutive days, thinly covering the entire wound surface with each treatment. The rat was first taken out of the cage, received the treatment at our mouse surgical table (which was cleaned and sanitized beforehand), and then returned to the cage. The wound was left open and not covered with any kind of covering. For the macroscopic wound contraction measurement, we measured the wound contraction length using a digital measurement caliper (0,01 mm measurement scale, 150mm maximum length) on the first day, the third day, the fifth day, the seventh day, and the fourteenth day before we applied the ozonated VCO each day, and recorded it in a follow-up table for further analysis.

Immunohistochemistry

For the immunohistochemistry staining, we analyzed the wound three times during the study period: on the first day, on the third day, and on the seventh day. We sacrificed three rats each period according to the standard operational procedure for immunohistochemistry staining⁵⁰. The anesthesia was administered by aerosol chloroform, similar to the method we used earlier when we created the wound model. We did not use

injectable anesthesia due to our concern that the injectable anesthesia might disturb the histopathological appearance of the tissues. The rat was first anesthetized using ether gas before we took samples from the wound margin. Afterward, we fixed the slices using 10% neutral buffered formalin for 24 hours, embedded it into a paraffin block, and thinly sliced it. We then measured the immunohistochemistry levels using specific staining for each of the biomarkers. The immunohistochemistry interpretation was done by pathology experts and was done blindly to make sure there was no subjectivity bias. The inclusion of each mouse in each immunohistochemistry period was randomized to prevent any bias. The remaining rat was terminated according to animal ethics by cervical dislocation.

Data analysis

Data analysis was done using SPSS version 16.0, using a single animal as the unit of analysis. We used one-way ANOVA to compare the means between the control group and the diabetic group. Data were considered as significant if $p < 0.05$.

Results

During the research, none of the 60 rats used in this study died before the research process ended and there were no observed adverse effects in the animals used in this study.

The measurements of wound length on day 1 to 14 (Table 1) as an indicator of wound healing shows a better wound healing process for the VCO with a longer duration of ozone flow. The reduction of wound length is directly proportional to the duration of ozone flow. The greatest to smallest wound length reduction is found in the VCO with ozone flow for 14 hours group (P4), followed by the 7 hours ozonated VCO group (P3), 90 minutes ozonated VCO group (P2), non-ozonated VCO group (P1), and the diabetic wound without VCO group (C-). The P4 group, which received VCO with ozone flow for 14 hours shows the greatest reduction in wound length (16837.10 μm)⁵¹. The smallest reduction in wound length was found in the C+ group (6370.77 μm), as expected. The results can be seen in Table 1 and Figure 1.

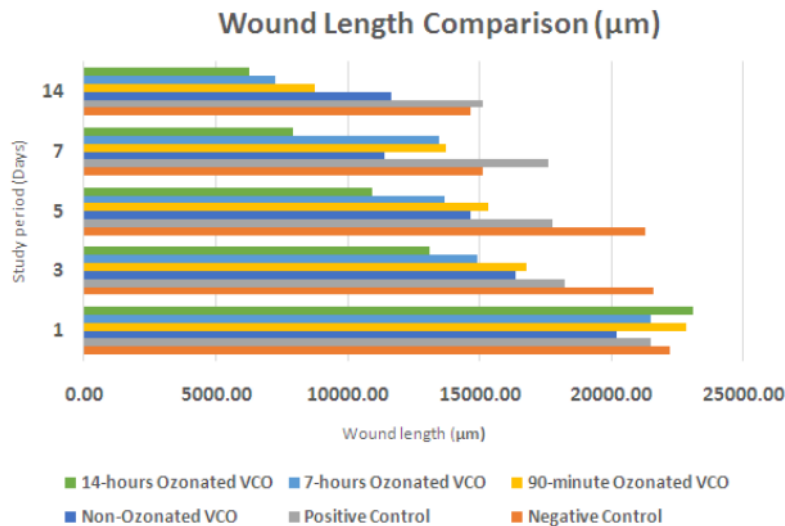
Figure 2 shows the macroscopic wound morphology comparison of wound healing between the study groups. As shown in the picture, the wounds in the treatment groups healed much faster compared to the positive control group without any treatment. The fastest wound healing was found among the P4 group, which had almost closed completely on the 14th day, where at the same time the wound on the positive control group had still barely healed. The P3 group had a similar wound healing result, although the wound length is still greater than that of the P4 group, signifying that the P4 group achieved the best wound healing result compared to all other therapeutic groups. Therefore, these results suggest that topical application of ozonated VCO can improve wound healing in diabetic rats, as shown by the improved wound contraction length compared to the diabetic positive control group without any treatment.

Descriptive measurements of HSP90A levels are shown in Table 2. The lowest HSP90A levels were obtained in the C+ group and the highest HSP90A levels were obtained in the P4

Table 1. Mean wound length comparison between study groups on day 1, 3, 5, 7 and 14.

Day	Wound length (μm)					
	C-	C+	P1	P2	P3	P4
1	22229.13	21496.31	20212.90	22825.82	21486.29	23079.71
3	21576.44	18243.73	16380.89	16762.67	14925.40	13126.56
5	21307.52	17760.51	14672.56	15342.78	13666.57	10939.59
7	15151.54	17590.09	11382.99	13730.39	13466.64	7940.71
14	14675.47	15125.54	11680.91	8753.86	7276.65	6242.61
Delta day 1–14	7553.66	6370.77	8531.99	14071.96	14209.64	16837.10

C-, negative control group with negative diabetic status; C+, positive control group with positive diabetic status; P1, non-ozonated VCO therapeutic group; P2, 90-minute ozonated VCO therapeutic group; P3, 7-hours ozonated VCO therapeutic group; P4, 14-hours ozonated VCO therapeutic group; VCO, virgin coconut oil.

**Figure 1.** Wound length comparison between study groups in the 1st, 3rd, 5th, 7th and 14th day. VCO, virgin coconut oil.

group throughout the measurement period. The histopathological images of HSP90a-stained cells are shown in Figure 3. One-way ANOVA showed a significant difference for all three measurement days. For the first day measurement, both the P3 group and P4 group exhibited significantly higher HSP90A levels compared to the C+ group. No group showed significantly higher HSP90A levels as compared to the C- group for the first-day measurement. For the third day measurement, all therapeutic groups exhibited significantly higher HSP90A levels compared to the C+ group, with P2, P3 and P4 groups showing significantly higher HSP90A levels compared to the C- group. Results for the seventh-day measurement were similar to the third-day measurement, where all therapeutic groups exhibited significantly higher HSP90A levels than to the C+ group, with

P3 and P4 groups showing significantly higher HSP90A levels compared to the C- group.

Descriptive measurements of VEGF-A levels are shown in Table 3. The lowest VEGF-A levels were obtained in the C+ group and the highest VEGF-A levels were obtained in the P4 group throughout the measurement period. The histopathological images of VEGF-stained cells are shown in Figure 4. One-way ANOVA showed a significant difference for all three measurement days. For the first day measurement, significantly higher VEGF-A levels were found for P2, P3 and P4 groups as compared to the C+ group, with P3 and P4 groups showing significantly higher VEGF-A levels compared to the C- group. For the third-day measurement, P2, P3 and P4 groups exhibited

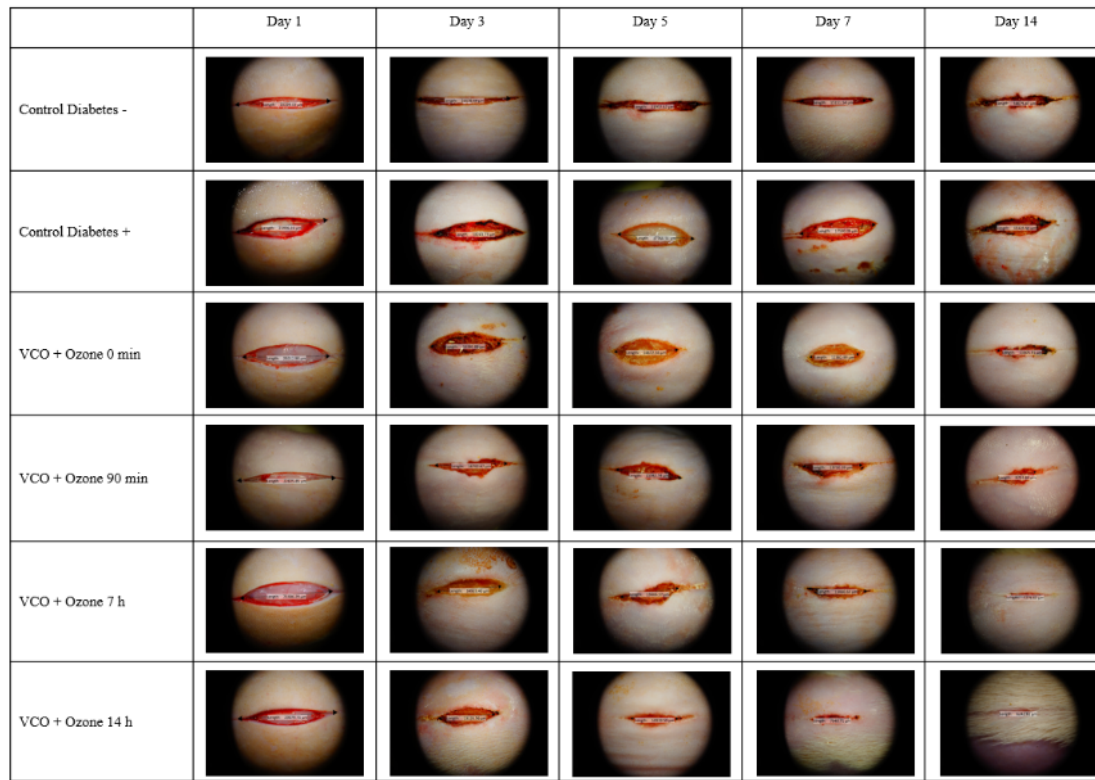


Figure 2. Macroscopic wound healing comparison between the study groups. The wound for the 14-hours ozonated VCO group healed faster and better compared to the control group. VCO, virgin coconut oil.

Table 2. HSP90A measurement results.

Group	1 st day		3 rd day		7 th day		Average	
	Mean	± SD	Mean	± SD	Mean	± SD	Mean	± SD
C-	6.7500	0.50000	6.8500	0.60622	9.9500	0.78102	7.8500	0.45044
C+	2.7500	1.08972	2.7267	1.57176	3.2500	1.75000	2.9100	1.08503
P1	5.5833	2.84312	8.8333	1.75594	9.7500	1.63936	8.0567	1.92149
P2	5.6667	2.18422	11.6667	2.12623	13.4633	2.82773	10.2667	1.76517
P3	9.2500	1.63936	12.2500	2.16506	17.6767	1.14019	13.0600	0.58000
P4	11.0833	2.56580	16.1867	0.73112	17.9167	1.66458	15.0633	1.40863

C-, negative control group with negative diabetic status; C+, positive control group with positive diabetic status; P1, non-ozonated VCO therapeutic group; P2, 90-minute ozonated VCO therapeutic group; P3, 7-hours ozonated VCO therapeutic group; P4, 14-hours ozonated VCO therapeutic group; VCO, virgin coconut oil.

significantly higher VEGF-A levels compared to the C+ group, with only the P4 group showing significantly higher VEGF-A levels compared to the C- group. Results for the seventh-day measurement shows similar results to the first- and third-day measurements, where P2, P3 and P4 groups

exhibited significantly higher VEGF-A levels compared to both C+ and C- groups.

Descriptive measurements of EGF levels are shown in Table 4. The lowest EGF levels were obtained in the C+ group

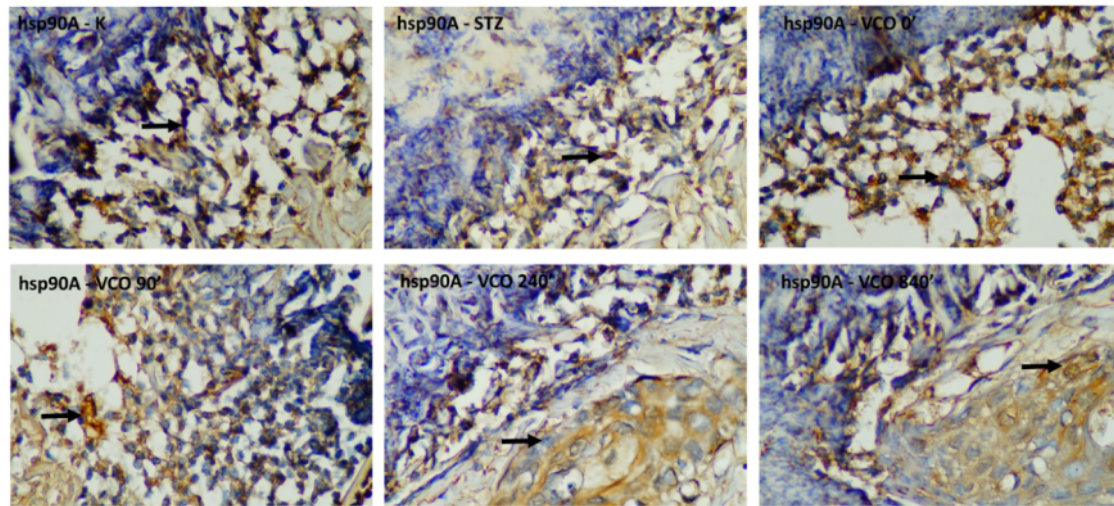


Figure 3. HSP90 α cells stained using immunohistochemistry under a microscope. Top row, from left to right: negative control group with negative diabetic status; positive control group with positive diabetic status; non-ozonated VCO therapeutic group. Bottom row, from left to right: 90-minute ozonated VCO therapeutic group; 7-hour ozonated VCO therapeutic group; 14-hour ozonated VCO therapeutic group. The size bar indicates 20 μ m. VCO, virgin coconut oil.

Table 3. VEGF-A measurement results.

Group	1 st day		3 rd day		7 th day		Average	
	Mean	\pm SD	Mean	\pm SD	Mean	\pm SD	Mean	\pm SD
C-	3.7500	0.66144	7.5833	1.18145	7.6667	1.25831	6.3333	0.52042
C+	1.9167	0.76376	2.6667	1.01036	4.0833	1.60728	2.8900	0.77544
P1	5.2500	1.39194	7.0000	3.30719	9.5333	2.83564	7.2633	0.92338
P2	7.8333	2.12623	11.2500	1.80278	14.7500	3.04138	11.2767	1.38059
P3	9.5833	1.46487	13.2567	1.64092	15.0833	1.52753	12.6400	0.46119
P4	11.7700	1.90284	15.1133	1.73339	17.5833	2.51661	14.8233	1.50134

C-, negative control group with negative diabetic status; C+, positive control group with positive diabetic status; P1, non-ozonated VCO therapeutic group; P2, 90-minute ozonated VCO therapeutic group; P3, 7-hours ozonated VCO therapeutic group; P4, 14-hours ozonated VCO therapeutic group; VCO, virgin coconut oil.

and the highest EGF levels were obtained in the P4 group throughout the measurement period. The histopathological images of EGF-stained cells are shown in Figure 5. One-way ANOVA showed a significant difference for all three measurement days. For the first day measurement, significantly higher EGF levels were found for P2, P3 and P4 groups compared to the C+ group, with no group showing significantly higher EGF levels compared to the C- group. For the third day measurement, all therapeutic groups exhibited significantly higher EGF levels compared to the C+ group, with the P3 group showing significantly higher EGF levels compared to the C- group. Results for the seventh-day measurement show that all therapeutic groups exhibited significantly higher EGF levels compared to the

C+ group, with P2, P3 and P4 groups showing higher EGF levels compared to C- group.

Descriptive measurements of bFGF levels are shown in Table 5. The lowest bFGF levels were obtained in the C+ group and the highest bFGF levels were obtained in the P4 group throughout the measurement period. The histopathological images of bFGF-stained cells are shown in Figure 6. One-way ANOVA showed a significant difference for all three measurement days. For the first day measurement, significantly higher bFGF levels were found for P2, P3 and P4 groups compared to the C+ group, with only P4 showing significantly higher bFGF levels compared to the C- group. For the third day measurement,

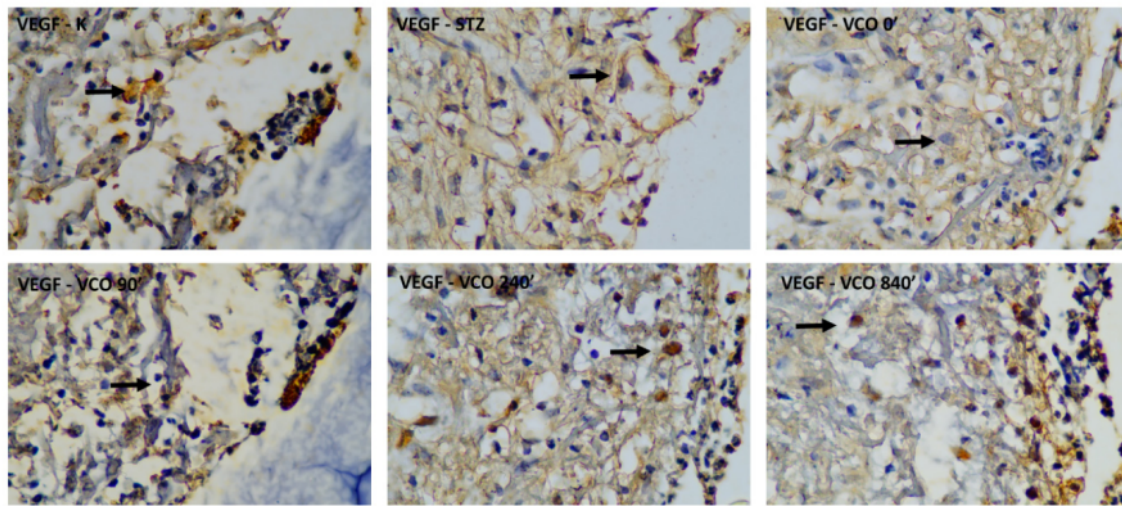


Figure 4. VEGF-A cells stained using immunohistochemistry under a microscope. Top row, from left to right: negative control group with negative diabetic status; positive control group with positive diabetic status; non-ozonated VCO therapeutic group. Bottom row, from left to right: 90-minute ozonated VCO therapeutic group; 7-hours ozonated VCO therapeutic group; 14-hours ozonated VCO therapeutic group. Size bar indicates 20 µm. VCO, virgin coconut oil.

Table 4. EGF measurement results.

Group	1 st day		3 rd day		7 th day		Average	
	Mean	± SD	Mean	± SD	Mean	± SD	Mean	± SD
C-	4.8333	1.37689	6.8333	1.50693	10.0000	1.63936	7.2233	0.21127
C+	1.9167	1.52753	2.0833	0.38188	2.9167	1.12731	2.3033	0.96028
P1	6.4167	2.00520	9.0000	2.50000	10.4167	0.76376	8.6100	0.62554
P2	9.0000	2.00000	11.6667	1.37689	13.4467	0.48583	11.3700	1.24531
P3	10.1667	1.60728	12.6667	2.67317	14.4867	0.87922	12.4400	1.16116
P4	10.5333	4.18947	14.2500	1.80278	17.2500	0.60324	14.0100	1.30767

C-, negative control group with negative diabetic status; C+, positive control group with positive diabetic status; P1, non-ozonated VCO therapeutic group; P2, 90-minute ozonated VCO therapeutic group; P3, 7-hours ozonated VCO therapeutic group; P4, 14-hours ozonated VCO therapeutic group; VCO, virgin coconut oil.

all therapeutic groups exhibited significantly higher bFGF levels compared to the C+ group, with P2, P3, and P4 groups showing significantly higher bFGF levels compared to the C- group. Similar to the third day, results for the seventh-day measurement show that all therapeutic groups exhibited significantly higher bFGF levels compared to the C+ group, with P2, P3 and P4 groups showing higher bFGF levels compared to the C- group.

Descriptive measurements of CD34 levels are shown in Table 6. The lowest CD34 levels were obtained in the C+ group and the highest CD34 levels were obtained in the P4 group

throughout the measurement period. The histopathological images of CD34-stained cells are shown in Figure 7. One-way ANOVA showed a significant difference for all three measurement days. For the first day measurement, significantly higher CD34 levels were only found for the P4 group compared to both C+ and C- groups. For the third day measurement, all therapeutic groups exhibited significantly higher CD34 levels compared to the C+ group, with P2, P3 and P4 groups showing significantly higher CD34 levels compared to the C- group. Similar to the third day, results for the seventh-day measurement show that all therapeutic groups exhibited significantly higher CD34 levels compared to the C+ group, with only the P4 group

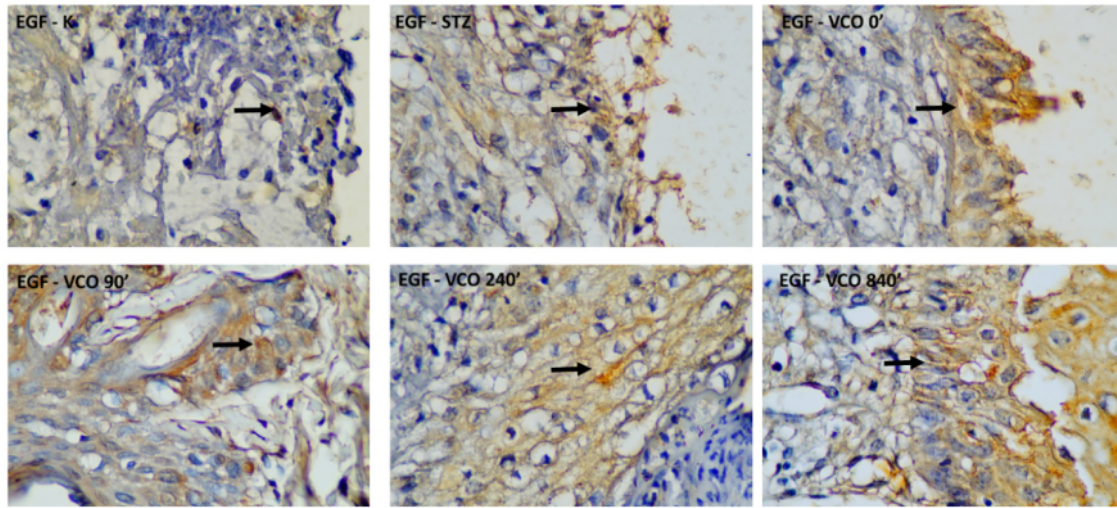


Figure 5. EGF cells stained using immunohistochemistry under a microscope. Top row, from left to right: negative control group with negative diabetic status; positive control group with positive diabetic status; non-ozonated VCO therapeutic group. Bottom row, from left to right: 90-minute ozonated VCO therapeutic group; 7-hour ozonated VCO therapeutic group; 14-hour ozonated VCO therapeutic group. Size bar indicates 20 µm. VCO, virgin coconut oil.

Table 5. bFGF measurement results.

Group	1 st day		3 rd day		7 th day		Average	
	Mean	± SD	Mean	± SD	Mean	± SD	Mean	± SD
C-	4.6667	1.01036	5.0000	2.04634	6.5000	0.90139	5.3900	0.74586
C+	2.0833	0.62915	2.3333	1.15470	3.6733	0.09292	2.6967	0.59719
P1	5.9100	2.30365	8.7833	1.22317	9.0333	1.12305	7.9067	0.80065
P2	7.9167	0.94648	10.2700	1.11969	11.9400	1.34078	10.0433	0.60682
P3	8.0033	2.02073	11.9700	2.42050	16.3067	0.71150	12.0900	0.59632
P4	9.8333	0.87797	15.9167	1.50693	19.8033	2.62413	15.1833	0.98399

C-, negative control group with negative diabetic status; C+, positive control group with positive diabetic status; P1, non-ozonated VCO therapeutic group; P2, 90-minute ozonated VCO therapeutic group; P3, 7-hour ozonated VCO therapeutic group; P4, 14-hour ozonated VCO therapeutic group; VCO, virgin coconut oil.

showing higher CD34 levels compared to the C- group. Therefore, the P4 group most consistently had higher levels of all growth factors and biomarkers measured in this study.

Discussion

VCO can be produced from fresh coconut or coconut milk, which is rich in medium-chain triglycerides and lauric acid. Lauric acid is a precursor of monolaurin, which can modulate immune cell proliferation. If a wound occurs, the inflammation process commences and immune cell activity increases^{52,53}.

Previous research found that VCO caused a significant reduction in ear edema, claw edema and granuloma formation in Sprague Dawley rats⁵⁴. VCO has been shown to have significant antioxidant effects including increased levels of the superoxide dismutase enzyme in the wound tissue of normal rats^{17,53}. In the case of chronic human skin conditions such as xerosis and atopic dermatitis, VCO shows a significant healing effect⁵⁵. VCO is also efficacious as a therapy for wound healing and angiogenesis. VCO showed a significant effect on the wound healing of diabetic rats through increased wound closure

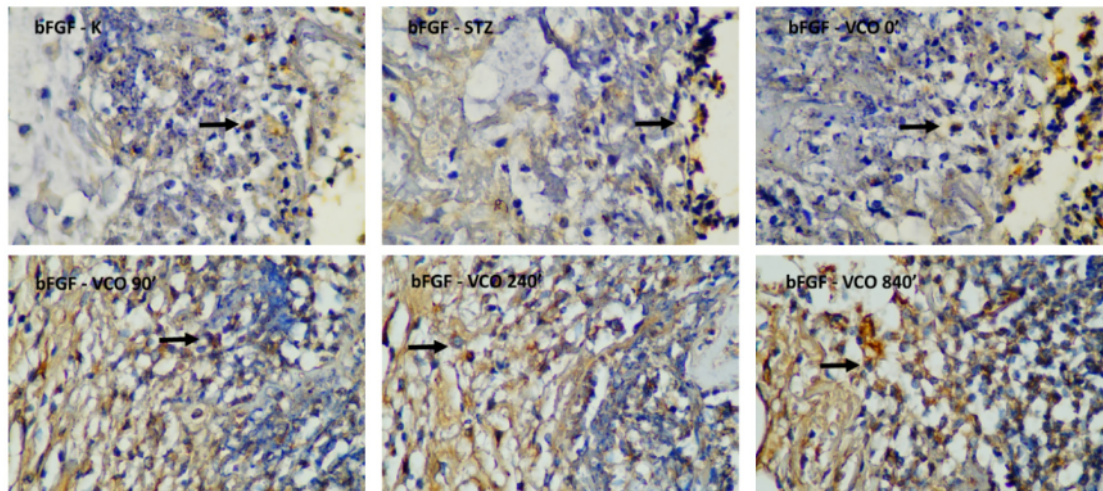


Figure 6. bFGF cells stained using immunohistochemistry under a microscope. Top row, from left to right: negative control group with negative diabetic status; positive control group with positive diabetic status; non-ozonated VCO therapeutic group. Bottom row, from left to right: 90-minute ozonated VCO therapeutic group; 7-hour ozonated VCO therapeutic group; 14-hour ozonated VCO therapeutic group. The size bar indicates 20 μ m. VCO, virgin coconut oil.

Table 6. CD34 measurement results.

Group	1 st day		3 rd day		7 th day		Average	
	Mean	\pm SD	Mean	\pm SD	Mean	\pm SD	Mean	\pm SD
C-	3.5000	0.66144	4.5833	1.66458	7.2167	0.62517	5.1000	0.33601
C+	1.4667	0.20207	1.5000	0.25000	2.5100	0.40509	1.8233	0.17214
P1	7.8267	5.23604	8.1333	0.76376	9.3167	1.69214	8.4267	2.29053
P2	6.7867	2.56535	10.1933	0.80755	11.0000	2.35425	9.3267	1.14129
P3	6.9167	1.37689	10.2500	2.22205	12.0833	1.46487	9.7500	1.38434
P4	12.9167	2.51661	15.4167	3.01386	19.9167	2.75379	16.0833	1.85263

C-, negative control group with negative diabetic status; C+, positive control group with positive diabetic status; P1, non-ozonated VCO therapeutic group; P2, 90-minute ozonated VCO therapeutic group; P3, 7-hour ozonated VCO therapeutic group; P4, 14-hours ozonated VCO therapeutic group; VCO, virgin coconut oil.

rate, total protein content, increased collagen synthesis and re-epithelialization. VCO proved to be significantly better than silver sulphadiazine cream in healing diabetic wounds⁵⁶.

The results of this study show that the application of ozone helps speed up the healing process of a diabetic ulcer. These results are similar to several previous studies. Izadi *et al.* found that ozone therapy shortened the time needed for diabetic wounds to heal¹². A systematic review of several studies reported that ozone therapy reduces the ulcer area and shortens the length of hospitalization compared to control therapies.

Ozone therapy was associated with a greater reduction of ulcer area compared to antibiotic therapy²⁶.

Reis *et al.* reported that ozone provided by a high-frequency device might potentially be useful in the treatment of ulcers, thus contributing to the healing process⁵⁷. This might be promoted by a decrease in bacterial infection, fibroplasia activation and keratinocyte proliferation. Ozone is a powerful oxidant; if ozone comes into contact with body fluids, it will result in the formation of reactive oxygen molecules and lead to several biochemical events that influence cellular metabolism, tissue

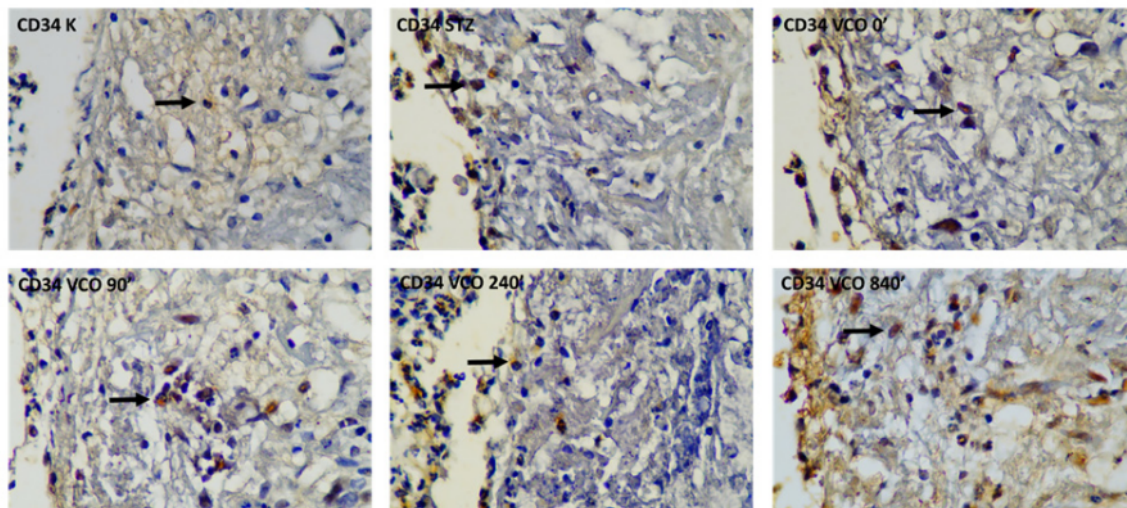


Figure 7. CD34 cells stained using immunohistochemistry under a microscope. Top row, from left to right: negative control group with negative diabetic status; positive control group with positive diabetic status; non-ozonated VCO therapeutic group. Bottom row, from left to right: 90-minute ozonated VCO therapeutic group; 7-hour ozonated VCO therapeutic group; 14-hour ozonated VCO therapeutic group. The size bar indicates 20 μ m. VCO, virgin coconut oil.

repair and ²microbial infection. Ozone has the potential to promote the activation of transcription factor NF- κ B, regulating inflammatory responses, and release of platelet-derived growth factor and transforming growth factor β 1 from platelets^{22,58,59}.

The previous study conducted by Kim *et al.* found an increased intensity of collagen fibers and a greater number of fibroblasts in an acute cutaneous wound for ²ozone group⁶⁰. Furthermore, during a systematic review of the therapeutic use of ozone in wounds, the authors discovered that most of the studies analyzed in their research found stimulation of the healing process (62.2%), followed by improvement in wound appearance (43.5%) and a decrease in pain (17.4%). The mechanism of how ozone improved wound healing might be related to its effect on the growth factors, activation of the antioxidant system, and activation of superoxide dismutase^{61,62}. Besides its effect on the wound healing process, ozone also improves the diabetic condition itself by improving glycemic control, preventing oxidative stress and normalizing organic peroxides, aside from activation of superoxide dismutase as explained above⁶¹. This condition might be beneficial to the wound healing process² due to the improved condition of diabetes itself. The authors concluded that ozone could be an important treatment option for wounds and may bring numerous benefits to patients⁶¹.

In terms of immunohistochemistry parameters, our study found that 14-hours ozonated VCO treatment increased HSP90 α , VEGF-A, EGF, bFGF and CD34 levels as measured in our study. Ozone has the potential to increase wound healing by reducing the wound area infection, controlling wound contamination

and reducing wound healing time^{20,63}. Ozone has also been found to increase granulation tissue formation, which also increases wound healing speed²². Zhang *et al.* showed that ozone increases the expression of several wound healing biomarkers, such as VEGF, transforming growth factor- β and platelet-derived growth factor. They also found that ozone improves wound healing in diabetic foot ulcers with a higher wound size reduction in the ozone-treated group²⁵.

As far as we know, there have been no other studies that show any therapeutic modalities, except the direct application of HSP90, that alters the wound healing result⁶⁴. HSP90 α helped to accelerate wound healing by recruiting both epidermal and dermal cells, promoting dermal cell migration, and was able to override the inhibitory effects of hyperglycemia on cell migration in diabetes⁶⁵. Several studies have found that topically applied HSP90 α protein improves wound healing in several kinds of wounds, especially diabetic wounds^{31,64–66}. The main pathology of diabetes is chronic hyperglycemia, which causes destabilization of a key regulator of the HSP90 α protein, hypoxia-inducible factor 1- α (HIF-1 α)^{30,64}. The HIF-1 α pathway is involved in wound healing by helping human dermal fibroblast migration; this is one of the causes of diabetic wound pathology^{64,66}. HSP90 α improves wound healing by mediating hypoxia-stimulated human dermal fibroblast motility under normal glycemic conditions and “jumpstarts” cell migration under hyperglycemia conditions^{31,64}. Therefore, HSP90 α helps diabetic wound healing by by-passing downregulation of HIF-1 α and helps to “rescue” the migration of hyperglycemic cells that otherwise do not respond properly to the environmental hypoxia⁶⁴. Cheng *et al.* found that HSP90 α can promote

wound healing in diabetic rat in a more effective manner⁶⁵. The middle domain of HSP90 α contains the F5 fragment, which acts as a pro-motility factor that affects all three human skin cell types. This HSP90 α fragment promotes dermal and epidermal cell migration through LRP-1 or CD91 surface receptors^{64,65}.

Most complications that arise from diabetes are related to vascular alterations caused by diabetes. The pathology of diabetic wound healing is tightly associated with insufficient angiogenesis and reduced VEGF signaling^{34,35}. Seitz *et al.* found that diabetic rat have decreased VEGF-A levels compared to normal rat⁶⁷. The low VEGF tissue levels in diabetes patients might be caused by the inability of diabetes patients to appropriately upregulate VEGF expression in response to hypoxia^{68,69}. Galiano *et al.* found that VEGF-A treated diabetic rat showed accelerated cutaneous wound closure compared to untreated rat. The mechanism of how VEGF facilitates tissue repair is by both increasing vascular permeability, which allows inflammatory cells to enter into the site of injury, and also increasing the migration and proliferation of pre-existing endothelial cells. In the VEGF-A treated diabetic wound model, there is a lot of abundantly vascularized granulating tissue on the wound bed, which causes the wound bed to become very hyperemic. When the VEGF-A treated wounds are almost completely healed, the control wounds were just starting to grow granulating tissue, and the granulation itself did not exhibit hyperemia and vascularization as the VEGF-A treated diabetic wounds did. VEGF treatment also induces neovascularization and cell proliferation in diabetic wounds⁶⁸.

Diabetes also causes EGF synthesis to be diminished, as shown in diabetic animal models³⁸. EGF is an important factor for wound healing, as it increases the stimulation, proliferation, and migration of several cells related to wound healing, such as keratinocytes, endothelial cells and fibroblasts, facilitates better dermal regeneration, and accelerates the level of wound contraction related to collagen deposition and proliferation of myofibroblasts^{37,70}. Degradation of several growth factors, including EGF, might result in refractory diabetic ulcer wounds. Several studies have shown the benefits of EGF therapy in diabetic wound models. Zhang *et al.* found that EGF improved diabetic wound healing by: increasing the formation of granulation tissue, collagen uniformity and the extracellular matrix; increasing the number of fibroblasts and improving fibroblast morphology; and also increasing the number of capillaries in the wound. EGF can also induce the migration of inflammatory cells away from the wound, which results in improvement of the wound microenvironment and tissue nutritional status³⁹. EGF also has the potential to enhance wound healing and reduce wound healing time, as found by Tsang *et al.* and Singla *et al.*^{40,41}

This study found an increase in bFGF levels in wounds treated with ozonated oil compared to nontreated wounds. Re *et al.* found that ozone increases the basal concentration of bFGF in ozone-incubated platelet-rich plasma⁷¹. An early study

showed that bFGF improves diabetic wound healing in a diabetic rat model by increasing the rate of cellular infiltration and capillary ingrowth, which might be related to the ability of bFGF to induce angiogenesis in wound healing^{42,72}. bFGF is the primary promoter for cell proliferation⁷³. bFGF contributes to wound healing by inducing angiogenesis, fibroblast proliferation and endothelial cell migration⁷⁴. A recent study using bioinspired hydrogels with bFGF done by Zhang *et al.* found that bFGF enhances cell proliferation, re-epithelialization, collagen deposition, and wound contraction in the full-thickness wound healing model. Chronic wound healing is also benefited by the increase of bFGF⁷³.

This study found an increase in CD34 levels in wounds treated with ozonated oil compared to nontreated wounds. CD34 has been used to improve wound healing in diabetic wound models using a CD34 injection direct to the wound itself or systemic injection of CD34 cells. Sivan-Loukianova *et al.* found that CD34 cells decreased diabetic wound size, accelerated epidermal healing, and rapidly accelerated neovascularization in diabetic wounds, as shown by an increase in blood vessel numbers and diameter⁷⁵. Cil *et al.* found that direct application of human umbilical-derived CD34 to the wound margins improves diabetic wound healing by decreasing inflammatory reactions and increasing wound revascularization⁷⁶. A recent study conducted by Kanji *et al.* also found that systemically-injected CD34 cells accelerate wound healing in streptozotocin-injected rat. CD34 cells improved re-epithelialization, increased neovascularization, improved granulation tissue formation and increased collagen and myofibroblasts deposition⁷⁷. Diabetic wounds have decreased angiogenesis and increased matrix metalloproteinases (MMPs), which inhibits proper wound healing in patients with diabetes³⁵. CD34 cells decreased the pro-inflammatory activity of NF- κ B, which therefore also reduced the level of MMP-1 expression by inhibiting the recruitment of NF- κ B to the MMP-1 promoter site. Therefore, CD34 can reverse the delayed wound healing factors in patients with diabetes. Besides healing effects, the measurement of CD34 cells in the wound margin can predict the healing of diabetic wounds. Thom *et al.* found that the number of CD34 cells in stained epidermis taken from the wound margin of diabetic wounds from diabetic patients was positively correlated with wound healing itself. Therefore, CD34 measurement in the early weeks of the diabetic wound provides insight into how well the diabetic wound will respond and can be used to predict the healing result of diabetic wounds⁴⁸.

There are several limitations in this study. First, we only measured macroscopic wound contraction length without analyzing the histological and biochemistry aspects of the wounds themselves. The comparison of wound healing histological events and biochemistry profiles between diabetic control rat and therapeutic group rat might enable further explanation on a mechanistic basis of how ozone improved wound healing in diabetic wounds. Moreover, we only analyzed the wounds until the seventh day and did not measure the events that happened until the wound successfully closed, as the end-result of the wound healing is the restoration of the wound itself. In addition,

insufficient literature about bFGF and CD34 in wound healing, especially diabetic wound healing, also leads to difficulty in determining the exact action of bFGF and CD34 in diabetic wound healing and the relation between its increase and its effect in the wound healing process. These could be considered to seek a better understanding of how ozone improved the wound healing process.

As ozonated VCO treatment can increase the levels of several wound healing biomarkers, such as HSP90 α , VEGF-A, EGF, bFGF and CD34 levels, its increase might potentially aid the wound healing process. This study is a preliminary study in animals (in this case Wistar rat). Rat can be used as an animal model for several skin diseases, including wound healing. Therefore, we hope that this research can be utilized as a basis for further research on the usage of ozonated VCO in human wounds⁷⁸.

Conclusions

Ozonated VCO has the potential to increase immunohistochemistry wound healing parameters in a diabetic wound rat model, as shown by the increase of HSP90 α , VEGF-A, EGF, bFGF and CD34 levels. The improvement of the wound healing process was proportional to the duration of ozone flow in VCO. A longer treatment period and a longer VCO ozonation duration

resulted in higher levels of biomarkers. Further research should be done to improve the application of ozonated oil treatment for diabetic ulcers in everyday practice.

Data availability

Underlying data

Open Science Framework: Topical ozonated virgin coconut oil improves wound healing and increases HSP90 α , VEGF-A, EGF, bFGF and CD34 in diabetic ulcer mouse model of wound healing. <https://doi.org/10.17605/OSF.IO/89FQC>⁵¹.

This project contains the following underlying data:

- Data Tables (raw data in XLSX format)
- Images (original unedited histopathology image files in JPG format)

Data are available under the terms of the [Creative Commons Attribution 4.0 International license](#) (CC-BY 4.0).

Acknowledgments

The authors would like to express our gratitude to the Department of Dermatology and Venereology, and Center Plasma Research (CPR), Diponegoro University, Semarang.

References

1. World Health Organization: **Global Report on Diabetes**. World Health Organization; 2019.
2. Miharja L, Soetrisno U, Soegondo S: **Prevalence and clinical profile of diabetes mellitus in productive aged urban Indonesians**. *J Diabetes Investig*. 2014; 5(5): 507–12.
[PubMed Abstract](#) | [Publisher Full Text](#) | [Free Full Text](#)
3. Khardori R: **Type 2 Diabetes Mellitus: Practice essentials, background, pathophysiology**. *Medscape*. 2019.
[Reference Source](#)
4. Jain AK: **A New Classification Of Diabetic Foot Complications: A Simple And Effective Teaching Tool**. *J Diabet Foot Complicat*. 2012; 4(1): 1–5.
[Reference Source](#)
5. Rowe VL: **Diabetic Ulcers: Practice essentials, background, pathophysiology**. *Medscape*. 2019.
6. Kruse I, Edelman S: **Evaluation and Treatment of Diabetic Foot Ulcer**. *Clin Diabetes*. 2006; 24(2): 91–3.
[Publisher Full Text](#)
7. Younis BB, Shahid A, Arshad R, et al.: **Frequency of foot ulcers in people with type 2 diabetes, presenting to specialist diabetes clinic at a Tertiary Care Hospital, Lahore, Pakistan**. *BMC Endocr Disord*. 2018; 18(1): 53.
[PubMed Abstract](#) | [Publisher Full Text](#) | [Free Full Text](#)
8. Volmer-Thole M, Lobmann R: **Neuropathy and Diabetic Foot Syndrome**. *Int J Mol Sci*. 2016; 17(6): 917.
[PubMed Abstract](#) | [Publisher Full Text](#) | [Free Full Text](#)
9. Zhang P, Lu J, Jing Y, et al.: **Global epidemiology of diabetic foot ulceration: a systematic review and meta-analysis**. *Ann Med*. 2017; 49(2): 106–16.
[PubMed Abstract](#) | [Publisher Full Text](#)
10. Sari Y, Purnawan I, Taufik A, et al.: **Quality of Life and Associated Factors in Indonesian Diabetic Patients with Foot Ulcers**. *Nurse Media J Nurs*. 2018; 8(1): 13.
[Reference Source](#)
11. Santoso M, Yuliana M, Mujono W, et al.: **Pattern of diabetic foot at Koja Regional General Hospital, Jakarta, from 1999 to 2004**. *Acta Med Indones*. 2005; 37(4): 187–9.
[PubMed Abstract](#)
12. Soewondo P, Ferrario A, Tahapary DL: **Challenges in diabetes management in Indonesia: a literature review**. *Global Health*. 2013; 9: 63.
[PubMed Abstract](#) | [Publisher Full Text](#) | [Free Full Text](#)
13. Desalu OO, Salawu FK, Jimoh AK, et al.: **Diabetic foot care: self reported knowledge and practice among patients attending three tertiary hospital in Nigeria**. *Ghana Med J*. 2011; 45(2): 60–5.
[PubMed Abstract](#) | [Publisher Full Text](#) | [Free Full Text](#)
14. Mahfud MU, Widyatmoko S, Hidayat N: **Hubungan Perawatan Kaki Pasien Diabetes Mellitus Tipe 2 Dengan Kejadian Ulkus Diabetik Di RSUD Dr. Moewardi**. Universitas Muhammadiyah Surakarta; 2012.
[Reference Source](#)
15. Ismiarto Y: **Aspek bedah penanganan luka diabetes**. In: Kariadi S, Arifin A, Adhiarta I, Permana H, Soetedjo N editors. *Naskah Lengkap Forum Diabetes Nasional V*. 2011.
16. Harlinanda SN: **Optimasi Formulasi Krim Antioksidan Vitamine (DL-ALFA TOKO FEROL ASETAT) Dengan VCO (Virgin Coconut Oil) (Variasi Kadar VCO 15%, 30%, dan 45% dalam Basis Cold Cream)**. Universitas Muhammadiyah Malang; 2017.
[Reference Source](#)
17. Nevin KG, Rajamohan T: **Effect of Topical Application of Virgin Coconut Oil on Skin Components and Antioxidant Status during Dermal Wound Healing in Young Rats**. *Skin Pharmacol Physiol*. 2010; 23(6): 290–7.
[PubMed Abstract](#) | [Publisher Full Text](#)
18. Soliman AM, Lin TS, Ghafar NA, et al.: **Virgin coconut oil and diabetic wound healing: histopathological and biochemical analysis**. *Eur J Anat*. 2018; 22(2): 135–44.
[Reference Source](#)
19. Elvis AM, Ekta JS: **Ozone therapy: A clinical review**. *J Nat Sci Biol Med*. 2011; 2(1): 66–70.
[PubMed Abstract](#) | [Free Full Text](#)
20. Borges GA, Elias ST, da Silva SM, et al.: **In vitro evaluation of wound healing and antimicrobial potential of ozone therapy**. *J Craniomaxillofac Surg*. 2017; 45(3): 364–70.
[PubMed Abstract](#) | [Publisher Full Text](#)
21. Saini R: **Ozone Therapy in Dentistry: A Strategic Review**. *J Nat Sci Biol Med*. 2011; 2(2): 151–3.
[PubMed Abstract](#) | [Free Full Text](#)
22. Travagli V, Zanardi I, Valacchi G, et al.: **Ozone and Ozonated Oils in Skin**

- Diseases: A Review.** *Mediators Inflamm.* 2010; **2010**: 610418.
[PubMed Abstract](#) | [Publisher Full Text](#) | [Free Full Text](#)
23. Nasruddin, Putri IK, Kamal S, et al.: **Evaluation of the effectiveness of combinative treatment of cold plasma jet, Indonesian honey, and micro-well dressing to accelerate wound healing.** *Clin Plasma Med.* 2017; **5**(6): 14–25.
[PubMed Abstract](#) | [Publisher Full Text](#)
 24. Sastroasmoro S: **Terapi Ozon.** Jakarta: HTA Indonesia. 2004; 1–29.
 25. Zhang J, Guan M, Xie C, et al.: **Increased Growth Factors Play a Role in Wound Healing Promoted by Noninvasive Oxygen-Ozone Therapy in Diabetic Patients With Foot Ulcers.** *Oxid Med Cell Longev.* 2014; **2014**: 273475.
[PubMed Abstract](#) | [Publisher Full Text](#) | [Free Full Text](#)
 26. Liu J, Zhang P, Tian J, et al.: **Ozone Therapy for Treating Foot Ulcers in People With Diabetes.** *Cochrane Database Syst Rev.* 2015; **2015**(10): CD008474.
[PubMed Abstract](#) | [Publisher Full Text](#) | [Free Full Text](#)
 27. Ocaña GJ, Sims EK, Watkins RA, et al.: **Analysis of Serum Hsp90 as a Potential Biomarker of β Cell Autoimmunity in Type 1 Diabetes.** *PLoS One.* 2019; **14**(1): e0208456.
[PubMed Abstract](#) | [Publisher Full Text](#) | [Free Full Text](#)
 28. Padmalayam I: **The Heat Shock Response: Its Role in Pathogenesis of Type 2 Diabetes and Its Complications, and Implications for Therapeutic Intervention.** *Discov Med.* 2014; **18**(97): 29–39.
[PubMed Abstract](#)
 29. Atalay M, Oksala N, Lappalainen J, et al.: **Heat Shock Proteins in Diabetes and Wound Healing.** *Curr Protein Pept Sci.* 2009; **10**(1): 85–95.
[PubMed Abstract](#) | [Publisher Full Text](#) | [Free Full Text](#)
 30. Li W, Sahu D, Tsen F: **Secreted Heat Shock protein-90 (Hsp90) in Wound Healing and Cancer.** *Biochim Biophys Acta.* 2012; **1823**(3): 730–41.
[PubMed Abstract](#) | [Publisher Full Text](#) | [Free Full Text](#)
 31. Jayaprakash P, Dong H, Zou M, et al.: **Hsp90 α and Hsp90 β together operate a hypoxia and nutrient paucity stress-response mechanism during wound healing.** *J Cell Sci.* 2015; **128**(8): 1475–80.
[PubMed Abstract](#) | [Publisher Full Text](#) | [Free Full Text](#)
 32. Izadi M, Jafari NJ, Hosseini MS, et al.: **Therapeutic effects of ozone in patients with diabetic foot ulcers: Review of the literature.** *Biomed Res.* 2017; **28**(18): 7846–7850.
[Reference Source](#)
 33. Benjamin LE: **Glucose, VEGF-A, and diabetic complications.** *Am J Pathol.* 2001; **158**(4): 1181–4.
[PubMed Abstract](#) | [Publisher Full Text](#) | [Free Full Text](#)
 34. Li Y, Hazarika S, Xie D, et al.: **In rat with type 2 diabetes, a vascular endothelial growth factor (VEGF)-activating transcription factor modulates VEGF signaling and induces therapeutic angiogenesis after hindlimb ischemia.** *Diabetes.* 2007; **56**(3): 656–65.
[PubMed Abstract](#) | [Publisher Full Text](#)
 35. Okonkwo UA, DiPietro LA: **Diabetes and Wound Angiogenesis.** *Int J Mol Sci.* 2017; **18**(7): 1419.
[PubMed Abstract](#) | [Publisher Full Text](#) | [Free Full Text](#)
 36. Sun N, Ning B, Hansson KM, et al.: **Modified VEGF-A mRNA induces sustained multifaceted microvascular response and accelerates diabetic wound healing.** *Sci Rep.* 2018; **8**(1): 17509.
[PubMed Abstract](#) | [Publisher Full Text](#) | [Free Full Text](#)
 37. Bodnar RJ: **Epidermal Growth Factor and Epidermal Growth Factor Receptor: The Yin and Yang in the Treatment of Cutaneous Wounds and Cancer.** *Adv Wound Care (New Rochelle).* 2013; **2**(1): 24–29.
[PubMed Abstract](#) | [Publisher Full Text](#) | [Free Full Text](#)
 38. Lee HY, Yea K, Kim J, et al.: **Epidermal growth factor increases insulin secretion and lowers blood glucose in diabetic rat.** *J Cell Mol Med.* 2008; **12**(5A): 1593–604.
[PubMed Abstract](#) | [Publisher Full Text](#) | [Free Full Text](#)
 39. Zhang J, Hu W, Diao Q, et al.: **Therapeutic effect of the epidermal growth factor on diabetic foot ulcer and the underlying mechanisms.** *Exp Ther Med.* 2019; **17**(3): 1643–1648.
[PubMed Abstract](#) | [Publisher Full Text](#) | [Free Full Text](#)
 40. Tsang MW, Wong WKR, Hung CS, et al.: **Human epidermal growth factor enhances healing of diabetic foot ulcers.** *Diabetes Care.* 2003; **26**(6): 1856–61.
[PubMed Abstract](#) | [Publisher Full Text](#)
 41. Singla S, Singla S, Kumar A, et al.: **Role of Epidermal Growth Factor in Healing of Diabetic Foot Ulcers.** *Indian J Surg.* 2012; **74**(6): 451–5.
[PubMed Abstract](#) | [Publisher Full Text](#) | [Free Full Text](#)
 42. Choi SM, Lee KM, Kim HJ, et al.: **Effects of Structurally Stabilized EGF and bFGF on Wound Healing in Type I and Type II Diabetic Rat.** *Acta Biomater.* 2018; **66**: 325–334.
[PubMed Abstract](#) | [Publisher Full Text](#)
 43. Mazué G, Bertolero F, Jacob C, et al.: **Prediclinical and Clinical Studies with Recombinant Human Basic Fibroblast Growth Factor.** *Ann NY Acad Sci.* 1991; **638**: 329–40.
[PubMed Abstract](#) | [Publisher Full Text](#)
 44. Kobayashi F, Matsuzaka K, Inoue T: **The effect of basic fibroblast growth factor on regeneration in a surgical wound model of rat submandibular glands.** *Int J Oral Sci.* 2016; **8**(1): 16–23.
[PubMed Abstract](#) | [Publisher Full Text](#) | [Free Full Text](#)
 45. Akita S, Akino K, Hirano A: **Basic Fibroblast Growth Factor in Scarless Wound Healing.** *Adv Wound Care (New Rochelle).* 2013; **2**(2): 44–49.
[PubMed Abstract](#) | [Publisher Full Text](#) | [Free Full Text](#)
 46. Makino H, Miyamoto Y, Kikuchi-Taura A, et al.: **Decreased Levels of Circulating CD34⁺ Cells Are Associated With Coronary Heart Disease in Japanese Patients With Type 2 Diabetes.** *J Diabetes Investig.* 2015; **6**(4): 473–8.
[PubMed Abstract](#) | [Publisher Full Text](#) | [Free Full Text](#)
 47. Zafar N, Krishnasamy SS, Shah J, et al.: **Circulating Angiogenic Stem Cells in Type 2 Diabetes Are Associated With Glycemic Control and Endothelial Dysfunction.** *Rajasingh J, editor. PLoS One.* 2018; **13**(10): e0205851.
[PubMed Abstract](#) | [Publisher Full Text](#) | [Free Full Text](#)
 48. Thom SR, Hampton M, Troiano MA, et al.: **Measurements of CD34⁺/CD45-dim Stem Cells Predict Healing of Diabetic Neuropathic Wounds.** *Diabetes.* 2016; **65**(2): 486–97.
[PubMed Abstract](#) | [Publisher Full Text](#) | [Free Full Text](#)
 49. Gargiulo S, Greco A, Gramanzini M, et al.: **Rat Anesthesia, Analgesia, and Care, Part I: Anesthetic Considerations in Preclinical Research.** *ILAR J.* 2012; **53**(1): E55–69.
[PubMed Abstract](#) | [Publisher Full Text](#)
 50. Kim SW, Roh J, Park CS: **Immunohistochemistry for Pathologists: Protocols, Pitfalls, and Tips.** *J Pathol Transl Med.* 2016; **50**(6): 411–418.
[PubMed Abstract](#) | [Publisher Full Text](#) | [Free Full Text](#)
 51. Khirisa MB: **Topical Ozonated Virgin Coconut Oil Improves Wound Healing and Increases Hsp90 α , VEGF-A, EGF, Bfgf and CD34 in Diabetic Ulcer Mouse Model of Wound Healing.** *OSF Web.* 2020.
 52. Mansor TST, Man C, Afq A, et al.: **Physicochemical properties of virgin coconut oil extracted from different processing methods.** *Int Food Res J.* 2012; **19**(3): 837–845.
[Reference Source](#)
 53. Yeap SK, Beh BK, Ali NM, et al.: **Antistress and antioxidant effects of virgin coconut oil in vivo.** *Exp Ther Med.* 2015; **9**(1): 39–42.
[PubMed Abstract](#) | [Publisher Full Text](#) | [Free Full Text](#)
 54. Intahphuak S, Khonsung P, Panthong A: **Anti-inflammatory, analgesic, and antipyretic activities of virgin coconut oil.** *Pharm Biol.* 2010; **48**(2): 151–7.
[PubMed Abstract](#) | [Publisher Full Text](#)
 55. Evangelista MTP, Abad-Casintahan F, Lopez-Villafuerte L: **The Effect of Topical Virgin Coconut Oil on SCORAD Index, Transepidermal Water Loss, and Skin Capacitance in Mild to Moderate Pediatric Atopic Dermatitis: A Randomized, Double-blind, Clinical Trial.** *Int J Dermatol.* 2014; **53**(1): 100–8.
[PubMed Abstract](#) | [Publisher Full Text](#)
 56. Ibrahim AH, Li H, Al-Rawi SS, et al.: **Angiogenic and wound healing potency of fermented virgin coconut oil: in vitro and in vivo studies.** *Am J Transl Res.* 2017; **9**(11): 4936–44.
[PubMed Abstract](#) | [Free Full Text](#)
 57. Reis FJJ, Correia H, Nagen R, et al.: **The Use of Ozone in High Frequency Device to Treat Hand Ulcers in Leprosy: a Case Study.** *Trop Med Health.* 2015; **43**(3): 195–9.
[PubMed Abstract](#) | [Publisher Full Text](#) | [Free Full Text](#)
 58. Valacchi G, Bocci V: **Studies on the Biological Effects of oOzone: 11. Release of Factors From Human Endothelial Cells.** *Mediators Inflamm.* 2000; **9**(6): 271–6.
[PubMed Abstract](#) | [Publisher Full Text](#) | [Free Full Text](#)
 59. Bocci VA, Zanardi I, Travagli V: **Ozone Acting on Human Blood Yields a Hormetic Dose-Response Relationship.** *J Transl Med.* 2011; **9**: 66.
[PubMed Abstract](#) | [Publisher Full Text](#) | [Free Full Text](#)
 60. Kim HS, Noh SU, Han YW, et al.: **Therapeutic Effects of Topical Application of Ozone on Acute Cutaneous Wound Healing.** *J Korean Med Sci.* 2009; **24**(3): 368–74.
[PubMed Abstract](#) | [Publisher Full Text](#) | [Free Full Text](#)
 61. Martínez-Sánchez G, Al-Dalain SM, Menéndez S, et al.: **Therapeutic Efficacy of Ozone in Patients With Diabetic Foot.** *Eur J Pharmacol.* 2005; **523**(1–3): 151–61.
[PubMed Abstract](#) | [Publisher Full Text](#)
 62. De Oliveira JTC: **Systematic Literature Review about the therapeutic use of the ozone in wounds.** University of Sao Paulo. 2007.
[Reference Source](#)
 63. Zanardi I, Borrelli E, Valacchi G, et al.: **Ozone: A Multifaceted Molecule With Unexpected Therapeutic Activity.** *Curr Med Chem.* 2016; **23**(4): 304–14.
[PubMed Abstract](#) | [Publisher Full Text](#)
 64. Guo J, Chang C, Li W: **The Role of Secreted Heat Shock protein-90 (Hsp90) in Wound Healing - How Could It Shape Future Therapeutics?** *Expert Rev Proteomics.* 2017; **14**(8): 665–75.
[PubMed Abstract](#) | [Publisher Full Text](#) | [Free Full Text](#)
 65. Cheng CF, Sahu D, Tsen F, et al.: **A Fragment of Secreted Hsp90 α Carries Properties That Enable It to Accelerate Effectively Both Acute and Diabetic Wound Healing in Rat.** *J Clin Invest.* 2011; **121**(11): 4348–61.
[PubMed Abstract](#) | [Publisher Full Text](#) | [Free Full Text](#)
 66. Li W, Li Y, Guan S, et al.: **Extracellular Heat Shock protein-90 α : Linking**

- Hypoxia to Skin Cell Motility and Wound Healing.** *EMBO J.* 2007; **26**(5): 1221–33.
[PubMed Abstract](#) | [Publisher Full Text](#) | [Free Full Text](#)
67. Seitz O, Schürmann C, Hermes N, *et al.*: **Wound Healing in Rat With High-Fat Diet- Or *Ob* Gene-Induced Diabetes-Obesity Syndromes: A Comparative Study.** *Exp Diabetes Res.* 2010; **2010**: 476969.
[PubMed Abstract](#) | [Publisher Full Text](#) | [Free Full Text](#)
 68. Galiano RD, Tepper OM, Pelo CR, *et al.*: **Topical Vascular Endothelial Growth Factor Accelerates Diabetic Wound Healing Through Increased Angiogenesis and by Mobilizing and Recruiting Bone Marrow-Derived Cells.** *Am J Pathol.* 2004; **164**(6): 1935–47.
[PubMed Abstract](#) | [Publisher Full Text](#) | [Free Full Text](#)
 69. Lerman OZ, Galiano RD, Armour M, *et al.*: **Cellular Dysfunction in the Diabetic Fibroblast: Impairment in Migration, Vascular Endothelial Growth Factor Production, and Response to Hypoxia.** *Am J Pathol.* 2003; **162**(1): 303–12.
[PubMed Abstract](#) | [Publisher Full Text](#) | [Free Full Text](#)
 70. Kwon YB, Kim HW, Roh DH, *et al.*: **Topical Application of Epidermal Growth Factor Accelerates Wound Healing by Myofibroblast Proliferation and Collagen Synthesis in Rat.** *J Vet Sci.* 2006; **7**(2): 105–9.
[PubMed Abstract](#) | [Publisher Full Text](#) | [Free Full Text](#)
 71. Re L, Martínez-Sánchez G, Perez-Davison G, *et al.*: **Role of Ozone/Oxygen in Fibroblast Growth Factor Activation. Discovering the Facts.** *Int J Ozone Ther.* 2010; **9**: 55–8.
[Reference Source](#)
 72. Greenhalgh DG, Sprugel KH, Murray MJ, *et al.*: **PDGF and FGF Stimulate Wound Healing in the Genetically Diabetic Mouse.** *Am J Pathol.* 1990; **136**(6): 1235–46.
[PubMed Abstract](#) | [Free Full Text](#)
 73. Zhang X, Kang X, Ji L, *et al.*: **Stimulation of Wound Healing Using Bioinspired Hydrogels With Basic Fibroblast Growth Factor (bFGF).** *Int J Nanomedicine.* 2018; **13**: 3897–906.
[PubMed Abstract](#) | [Publisher Full Text](#) | [Free Full Text](#)
 74. Lv C, Wu J, He H: **Experimental Study on the Expression of IL-1 β and bFGF in Wound Healing Process of Rabbit Cutaneous Infective Wound in Liu-He-Dan.** *Evidence-Based Complement Altern Med.* 2017; **2017**: 7230178.
[PubMed Abstract](#) | [Publisher Full Text](#) | [Free Full Text](#)
 75. Sivan-Loukianova E, Awad OA, Stepanovic V, *et al.*: **CD34⁺ Blood Cells Accelerate Vascularization and Healing of Diabetic Mouse Skin Wounds.** *J Vasc Res.* 2003; **40**(4): 368–77.
[PubMed Abstract](#) | [Publisher Full Text](#)
 76. Çil N, Oğuz EO, Mete E, *et al.*: **Effects of Umbilical Cord Blood Stem Cells on Healing Factors for Diabetic Foot Injuries.** *Biotech Histochem.* 2017; **92**(1): 15–28.
[PubMed Abstract](#) | [Publisher Full Text](#)
 77. Kanji S, Das M, Joseph M, *et al.*: **Nanofiber-expanded human CD34⁺ Cells Heal Cutaneous Wounds in Streptozotocin-Induced Diabetic Rat.** *Sci Rep.* 2019; **9**(1): 8415.
[PubMed Abstract](#) | [Publisher Full Text](#) | [Free Full Text](#)
 78. Avci P, Sadasivam M, Gupta A, *et al.*: **Animal Models of Skin Disease for Drug Discovery.** *Expert Opin Drug Discov.* NIH Public Access; 2013; **8**(3): 331–55.
[PubMed Abstract](#) | [Publisher Full Text](#) | [Free Full Text](#)

Open Peer Review

Current Peer Review Status: ? X

Version 2

Reviewer Report 26 July 2021

<https://doi.org/10.5256/f1000research.55943.r85011>

© 2021 Shenoy R. This is an open access peer review report distributed under the terms of the [Creative Commons Attribution License](#), which permits unrestricted use, distribution, and reproduction in any medium, provided the original work is properly cited.

X **Rekha Raghuvveer Shenoy** 

Department of Pharmacology, Manipal College of Pharmaceutical Sciences, Manipal Academy of Higher Education, Manipal, India

1. Authors should define the method of sacrifice instead of stating graceful termination of animals.
2. Why only male rats were taken in this study? Diabetic foot ulcer occurs in women also.
3. The word subjects is not used for experimental animals.
4. Needs a grammatical check in section "Animals".
5. What is the meaning of this sentence, "During the research, none of the 60 rat dropped out"?
6. Blood glucose levels just on the day of wound infliction should be mentioned.
7. Figure 2 does not represent excision wound model. It appears as an incision wound model.
8. Why were standard and VCO alone groups not considered in the study?
9. What is the rationale for having four VCO + ozone groups?
10. Literature reports show similar studies done in Sprague Dawley rats. Why was this study performed in Wistar strain?

Is the work clearly and accurately presented and does it cite the current literature?

Partly

Is the study design appropriate and is the work technically sound?

Partly

Are sufficient details of methods and analysis provided to allow replication by others?

No

If applicable, is the statistical analysis and its interpretation appropriate?

Partly

Are all the source data underlying the results available to ensure full reproducibility?

No source data required

Are the conclusions drawn adequately supported by the results?

Partly

Competing Interests: No competing interests were disclosed.

Reviewer Expertise: Pharmacology of tissue repair, diabetic wounds and inflammatory disorders

I confirm that I have read this submission and believe that I have an appropriate level of expertise to state that I do not consider it to be of an acceptable scientific standard, for reasons outlined above.

Author Response 11 Aug 2021

Matthew Brian Khrisna, Faculty of Medicine, Diponegoro University, Indonesia

Dear Rekha Raghuveer Shenoy,

Thank you very much for the review of this article.

We have uploaded a new version that addresses your concerns according to our article.

Our answers for your comments are marked in *italics*.

1. Authors should define the method of sacrifice instead of stating graceful termination of animals.

The method of sacrifice is cervical dislocation; we have explained it in the Methods section.

2. Why only male rats were taken in this study? Diabetic foot ulcer occurs in women also.

Female rats are more prone to hormonal changes that might affect the diabetic induction process.

3. The word subjects is not used for experimental animals.

We have fixed this in the new version of the article. Thank you.

4. Needs a grammatical check in section "Animals".

We have re-checked the grammar in the new version of the article. Thank you.

5. What is the meaning of this sentence, "During the research, none of the 60 rat dropped out"?

None of the 60 rats died before the end of the study period, which might affect the sample

size per group.

6. Blood glucose levels just on the day of wound infliction should be mentioned.
We have fixed this in the new version of the article. Thank you.
7. Figure 2 does not represent excision wound model. It appears as an incision wound model.
We have fixed this in the new version of the article. Thank you.
8. Why were standard and VCO alone groups not considered in the study?
Control groups and non-ozonated VCO groups have already considered in the study.
9. What is the rationale for having four VCO + ozone groups?
We would like to find which ozonation time provides the best results for the wound healing.
10. Literature reports show similar studies done in Sprague Dawley rats. Why was this study performed in Wistar strain?
Wistar strain has larger size than Sprague-Dawley rats, which enables us to make a larger wound and more easily monitor the healing process.

Competing Interests: No competing interests were disclosed.

Reviewer Report 19 July 2021

<https://doi.org/10.5256/f1000research.55943.r84621>

© 2021 Badr G. This is an open access peer review report distributed under the terms of the [Creative Commons Attribution License](#), which permits unrestricted use, distribution, and reproduction in any medium, provided the original work is properly cited.



Gamal Badr

Laboratory of Immunology, Zoology Department, Faculty of Science, Assiut University, Assiut, Egypt

The authors should also re-revised the manuscript against the following points:

- All the data in the tables must be presented in bars and the authors must revise the statistical analysis using different symbols for significance among the groups.
- The authors should add the data for the time point 14 days-post wounding.

Is the work clearly and accurately presented and does it cite the current literature?

Partly

Is the study design appropriate and is the work technically sound?

Partly

Are sufficient details of methods and analysis provided to allow replication by others?

Partly

If applicable, is the statistical analysis and its interpretation appropriate?

Partly

Are all the source data underlying the results available to ensure full reproducibility?

Partly

Are the conclusions drawn adequately supported by the results?

Partly

Competing Interests: No competing interests were disclosed.

Reviewer Expertise: Immunology.

I confirm that I have read this submission and believe that I have an appropriate level of expertise to confirm that it is of an acceptable scientific standard, however I have significant reservations, as outlined above.

Version 1

Reviewer Report 19 January 2021

<https://doi.org/10.5256/f1000research.24862.r77529>

© 2021 Badr G. This is an open access peer review report distributed under the terms of the [Creative Commons Attribution License](#), which permits unrestricted use, distribution, and reproduction in any medium, provided the original work is properly cited.

? **Gamal Badr** 

Laboratory of Immunology, Zoology Department, Faculty of Science, Assiut University, Assiut, Egypt

In the present manuscript entitled: Topical ozonated virgin coconut oil improves wound healing and increases HSP90α, VEGF-A, EGF, bFGF and CD34 in diabetic ulcer mouse model of wound healing, the authors focused to investigate the effect of ozonated VCO on the healing process of diabetic wounds using STZ-induced a diabetic mouse model. Several points should be seriously taken in consideration for the following reasons:

1. The authors are advised to extensively revise the manuscript against English language errors that are present throughout the manuscript. The manuscript was poorly written and can not be accepted in the current version.

2. The authors should respect the use of abbreviations throughout the manuscript. The abbreviation must be defined at the first appear in the text and then the authors should use the abbreviations throughout the manuscript.
3. The introduction section was too long and should be improved.
4. The most critical point of this study is that the authors used 6 animal groups (10 mice per group) but they investigated the IHC expression of HSP90, VEGF, CD34, FGF and EGF on at 1, 3, 5 and 7 days post-wounding. However, the mice in the 14 days post-wounding time point were terminated. The authors must investigate all the parameters at all time points post-wounding.
5. The statistical analysis should be revised, and a multiple comparison test must be performed.
6. All the data in the tables must be presented in bars figures under the main figures.
7. Figure 1 lacks legend on the X- and Y-axis and also lacks symbols for significance.
8. The authors must present the histopathological alterations throughout the interval time points using H&E staining.

Is the work clearly and accurately presented and does it cite the current literature?

Partly

Is the study design appropriate and is the work technically sound?

No

Are sufficient details of methods and analysis provided to allow replication by others?

Partly

If applicable, is the statistical analysis and its interpretation appropriate?

No

Are all the source data underlying the results available to ensure full reproducibility?

Yes

Are the conclusions drawn adequately supported by the results?

Yes

Competing Interests: No competing interests were disclosed.

Reviewer Expertise: Immunology.

I confirm that I have read this submission and believe that I have an appropriate level of expertise to confirm that it is of an acceptable scientific standard, however I have

significant reservations, as outlined above.

Author Response 08 Apr 2021

Matthew Brian Khrisna, Faculty of Medicine, Diponegoro University, Indonesia

Dear Prof. Gamal Badr,

Thank you very much for your review.

In response to your reservations, we have uploaded a newer version of this article.

Kindly review these new versions as the revised version of this article.

Thank you.

Regards,
Authors

Competing Interests: No competing interests were disclosed.

The benefits of publishing with F1000Research:

- Your article is published within days, with no editorial bias
- You can publish traditional articles, null/negative results, case reports, data notes and more
- The peer review process is transparent and collaborative
- Your article is indexed in PubMed after passing peer review
- Dedicated customer support at every stage

For pre-submission enquiries, contact research@f1000.com

F1000Research

F1000Research Topical Coconut Oil

ORIGINALITY REPORT

4%

SIMILARITY INDEX

2%

INTERNET SOURCES

1%

PUBLICATIONS

3%

STUDENT PAPERS

PRIMARY SOURCES

1

Submitted to Universitas Diponegoro

Student Paper

2%

2

www.jstage.jst.go.jp

Internet Source

1%

3

Submitted to West Coast University

Student Paper

<1%

4

Submitted to Instituto Gulbenkian de Ciencia

Student Paper

<1%

5

Submitted to Barry University

Student Paper

<1%

6

Submitted to University of Arizona

Student Paper

<1%

7

stemcells.alphamedpress.org

Internet Source

<1%

8

Submitted to University of Utah

Student Paper

<1%

9

www.intechopen.com

Internet Source

<1%

Exclude quotes On

Exclude matches

< 5 words

Exclude bibliography On

F1000Research Topical Coconut Oil

GRADEMARK REPORT

FINAL GRADE

/0

GENERAL COMMENTS

Instructor

PAGE 1

PAGE 2

PAGE 3

PAGE 4

PAGE 5

PAGE 6

PAGE 7

PAGE 8

PAGE 9

PAGE 10

PAGE 11

PAGE 12

PAGE 13

PAGE 14

PAGE 15

PAGE 16

PAGE 17

PAGE 18

PAGE 19

PAGE 20

