

# THE EARLY GONADAL DEVELOPMENT

*by* Putut Riyadi

---

**Submission date:** 08-Nov-2020 02:55PM (UTC+0700)

**Submission ID:** 1439406042

**File name:** 7.\_The-Early-Gonadal-Development.pdf (485.74K)

**Word count:** 3046

**Character count:** 15740

# THE EARLY GONADAL DEVELOPMENT OF CULTIVATED FEMALE COBIA FISH (*RACHYCENTRON CANADUM*) AT SOME AGE USING HISTOLOGICAL ANALYSIS

Asmanik, Happy Nursyam, Maheno Sri Widodo, Arning Wilujeng Ekawati, Putut Har Riyadi

**Abstract:** The cobia fish (*Rachycentron canadum*) is gonochoristic and the oocyte development is nonsynchronous. The aim of this study was to analyse the gonadal development of cobia fish (cultivation fish raised in floating netcage) starting from juvenile (3 months old) until 15 months old (estimated gonadal maturation). Samples of blood, gonad, and pituitary of female cobia fish at some ages (3, 6, 9, 12, and 15 months) was taken and than the measurement of several parameters, ie ; body weight, gonad weight, body total length, FSH hormone concentration was commenced, and also the making of histological preparation of gonad and pituitary. As well as observation on the growth of body weight and development of cobia fish oocyte (age 6 – 9 month) which raised in controlled tank. The result of this study is that at age 3 – 8 months the development of oocyte reached the previtellogenic stage, while at age of 9 months, the gonad of cobia cultivated fish start developing to stage of vitellogenesis and maturation (percentage of mature oocyte was  $0,98 \pm 0,37\%$ ).

**Index Terms:** age, cobia-*Rachycentron canadum*, cultivation, Histology, ovary

## 1 INTRODUCTION

Cobia fish (*Rachycentron canadum*) have a good quality white meat [1], so it has economic value as consumption fish. Cobia fish farming activities have been carried out in several countries, among others namely Texas [2], India [3], Vietnam [4], and Australia [5], while Indonesia promotes the cultivation of Cobia fish in 2019 [6]. Cobia fish is gonochoristic species [7,8]. Gonochorists are individuals who develop only as males or females and remain the same sex throughout their life span. Aquaculture activities require methods that can be explored through studies of fish reproduction. Knowledge of reproductive strategies are fundamental to understand, which is useful as a material consideration in preparing steps of administration, handling, and preservation [9]. Therefore knowledge of histological-morpho characteristic gonadal structure is the basic stage for understanding fish reproduction, especially when evaluated from the first stage of life [10]. Research on the biology of reproduction of Cobia fish in nature has been carried out [11, 12, 13, 14, 15,16,17] and about intersex [8]. While information about the development of gonadal of cultivated Cobia fish which starting from juvenile stage has not been done. The aim of this study was to analyze the gonadal development of cultivated Cobia fish which started from juvenile (3 months old) until 15 months old (estimated gonadal maturation), so the information obtained is useful in improving procedures for gonad maturation in aquaculture activities.

## 2 MATERIAL METHODS

- Asmanik is currently pursuing doctors degree program in the faculty fisheries and marine sciences, Brawijaya University, Malang-Indonesia, asmanik2002@yahoo.com
- Happy Nursyam, Maheno Sri Widodo, Arning Wilujeng Ekawati are supervisor in the faculty fisheries and marine sciences, Brawijaya University, Malang-Indonesia.

This study was conducted in Main Center for Marine Aquaculture (MCMA) Lampung-Indonesia. The methods used is as follow:

### 2.1. Taking blood, gonad, and pituitary sample of female Cobia fish of several age.

Morphological differences between male and female Cobia fish is not clear (difficult to distinguish morphologically), so that sample is done by trial and error (cannulation is done first to ensure the sex of the male or female, but if no oocyte or sperm samples are obtained, than a blood sample is taken first, then surgery is performed to check the gonad ). Fish samples were taken from floating net cages of MCMA Lampung, and obtained Cobia fish with ages 3, 6, 9, 12, and 15 months (each ages is taken 3 individuals). Then several parameters are measured, i.e.: weighing body weight and gonad weight, measurement of FSH hormone concentration, and also the making of histological preparation of gonad and pituitary.

### 2.2. Measurement of FSH hormone concentration was carried out by the ELISA method.

The material used is fish follicle-stimulating hormone ELISA kit; Bioassay Technology Laboratory, cat no E0039Fi and blood serum. Blood sampling is done at the base of the fish tail using 5 ml syring (which has been given anticoagulants) and centrifuged 6500 rpm for 5 minutes. The obtained serum is then separatis and stories at temperatures - 80°C for ELISA test use.

### 2.3. Making of gonad and pituitary preparations.

Gonad and pituitary are inserted into neutral buffered formaldehyde solution (BNF) 10%. Then histological preparations were made using hematoxylin and eosin staining [18] for gonad which is done in Fish and Environmental

Laboratory (FEL) MCMA Lampung. Pituitary slice preparations is also carried out in FEL MCMA Lampung while staining with Masson trichrome is done in The Histology Laboratory of The Medical Faculty of Brawijaya University in Malang. Gonadal histology slices are used to observe the percentages of gonad developmental stages, while pituitary histology slices are used to see the presences of  $\beta$  cells (basophil cells). Observation of pituitary slices was carried out using the Olympus brand microscope series XC10/BX51 U-TVIX-2 T2 Tokyo Japan, while observation of gonadal slices was done using the Olympus brand Microscope series DP71/BX51.

#### 2.4. Observation of female Cobia fish oocyte development intensively.

Seedlings of cultivated Cobia fish (comes from the same group time of spawning and age) maintained in floating net cage of size 3 m x 3 m x 3 m a total of four cages with a population of 200 individu per cages. The Seedlings are 50 gr in weight size and are 5 months old. Morphologically it is difficult to distinguish between male and female Cobia fish, so

that selection is done by cannulation to estimate the sex of the fish. If the cannulation hose can be inserted 1.5 - 2 cm in the genital tract, so it is suspected that the fish is female, meanwhile if the hose can not be inserted or can only be inserted 0,5 cm, so it is suspected that the fish is male. From total of 800 seedlings selected, 94 seedlings were suspected of being females. After obtaining female fish seedlings, than the fishes are kept in a series of 2 m<sup>3</sup> size controlled tank with population density of 10 individu per tank, than thinning is carried out to reduce the density. After the fish weight  $\pm$  1.5 kg, the maintenance is carried out in 15 m<sup>3</sup> size tank with a density of 20 individu per tank. During maintenance activities, fish are given commercially made feed until they are full (twice a day in the morning and evening). The parameters observed were body weight growth and oocyte diameter development every month. Oocyte is taken by cannulation than the development and diameter of oocyte are observe (50 oocytes per individu) using Olympus brand microscope, by using magnification of 10 X 10.

### 3. RESULT AND DISCUSSION

The type of oocyte development in Cobia fish is nonsynchronous [11], where there are various phases of oocyte development (the development of oocyte is not uniform). At the ages 3 and 6 months, oocyte development reach a stage of previtellogenic where most of oocytes consist of oocytes perinucleolar [19], in addition there are also presence oocytes at the stage chromatin nucleus and cortical alveoli (Fig. 1a and Fig. 1b). Whereas at the age of 9 months (Fig. 1c), the development of oocytes has reach a stage of vitellogenesis (where there are an increase in oocytes size and the amount of lipid vacuoles and still also the presences of previtellogenic oocytes and a small percentages of mature oocytes). At the ages of 12 and 15 months (Fig. 1d and

Fig.1e) there are mature oocytes and previtellogenic oocytes. While the weight growth of Cobia fish that kept on controlled tank is faster than those which kept in floating net cages. This is allegedly because of the handling in the floating net cages is not as intensive as the handling in a controlled tank. But when viewed from the development of oocytes, at 5 - 8 months old cobia fish are still in the form of previtellogenic (Fig. 1f), and at 9 months age fish start to see oocytes undergoing vitellogenesis (Fig. 1g). Based on the observation above, it is appears that the gonad of the cultivated female Cobia fish begins to progress to the stage of vitellogenesis and maturation at the age of 9 months.

TABLE 1.

DATA OF BODY WEIGHT, TOTAL LENGTH, GONAD WEIGHT, PERCENTAGES OF GONADAL DEVELOPMENT STAGE AND THE PRESENCES OF  $\beta$  CELL IN COBIA FISH AT VARIOUS AGES THAT ARE KEPT IN FLOATING NET CAGES

Age (Month)	Body Weight (g)	Total Length (cm)	Gonad Weight (g)	Gonad maturity percentage (%)					Sel $\beta$
				M	V	CA	P	CN	
3	70,00 $\pm$ 1,00	21,83 $\pm$ 0,76	< 1	0,00 $\pm$ 0,00	0,00 $\pm$ 0,00	0,00 $\pm$ 0,00	73,07 $\pm$ 7,72	26,93 $\pm$ 7,72	Was found
6	507,00 $\pm$ 49,50	50,50 $\pm$ 0,71	2,00 $\pm$ 0,00	0,00 $\pm$ 0,00	0,00 $\pm$ 0,00	2,19 $\pm$ 0,03	95,34 $\pm$ 0,44	2,47 $\pm$ 0,42	Was found
9	1447,50 $\pm$ 102,53	62,00 $\pm$ 0,00	21,50 $\pm$ 2,12	0,98 $\pm$ 0,37	5,62 $\pm$ 1,72	3,91 $\pm$ 0,43	78,72 $\pm$ 5,11	10,77 $\pm$ 4,42	Was found
12	1625,00 $\pm$ 176,78	70,50 $\pm$ 7,78	20,50 $\pm$ 6,36	0,74 $\pm$ 0,86	0,00 $\pm$ 0,00	0,00 $\pm$ 0,00	85,42 $\pm$ 5,21	13,84 $\pm$ 5,47	Was found
15	2607,50 $\pm$ 1573,31	79,50 $\pm$ 6,36	40,50 $\pm$ 27,58	0,19 $\pm$ 0,38	0,00 $\pm$ 0,00	0,00 $\pm$ 0,00	87,60 $\pm$ 8,42	12,21 $\pm$ 8,59	Was found

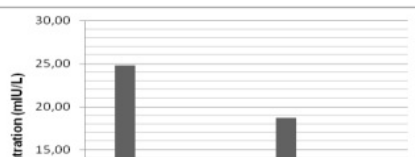
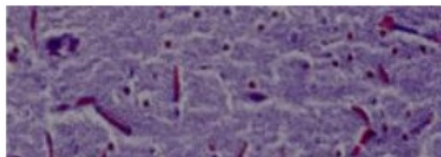
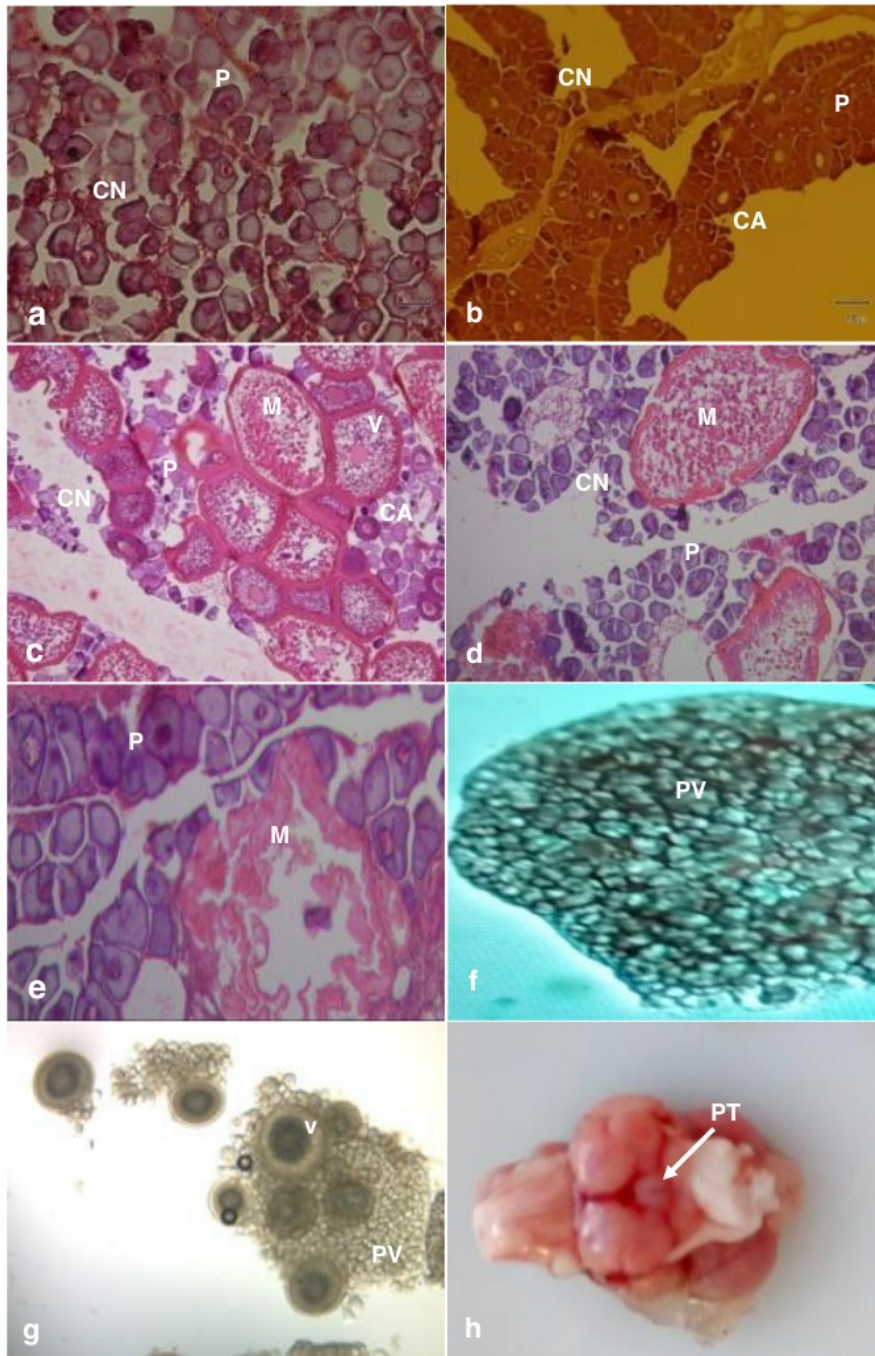
Note: M = mature; V = vitellogenesis; CA = cortical alveoli; P = perinucleolar dan CN = chromatin nucleus

Gonadotropin cells ( $\alpha$  cell and  $\beta$  cell) in the teleostei fish are usually found in the proximal pars distalis from the slices of the pituitary gland [20]. Based on the results of staining, cells in the pars distalis are divided into three types, i.e: acidophils, basophil, and chromopobes. Acidophil cells are large and polygonal in shape with heterochromatic nucleus and cytoplasm orange-red colouration. Basophil cells are round or oval in shape, and slightly smaller than acidophil cells, dark round nucleus is located in the middle of the cell. Chromopobes are stained weakly (pale) on the pars distalis.

These cells have less cytoplasm than Acidophil and Basophil cells and have a very dark nucleus [21]. Basophilic gonadotropin will be dark blue colouration with PAS, Masson's trichrome, and Heidenhain's azan staining [22,23]. From the results of the pituitary slices it can be seen that basophil cells ( $\beta$  cells) are found at all ages (3 - 15 months). But with ordinary staining it is difficult to distinguish FSH  $\beta$  cells from other gonadotropin cells, because all basophil cells will be blue in colouration, so immunohistochemicals staining is needed and high magnification is used at the time of

observation [24]. However this matter can be seen in another way, by looking at the content of FSH in the blood (if there is FSH in the blood is means that FSH B cells already exist and work). High FSH concentration are seen in the previtellogenic and regression phases, whereas in the vitellogenesis phase

the FSH concentration is low (Fig. 2). This is the same as the optical density value for  $\beta$  FSH with immunoblots in fish *Steindachneridium parahybae* [19], this displays a close relationship with the ovarian developmental season [25].



j

Fig 1. **g** nadal and pituitary slices of Cobia fish

Notes: a. 3 months old. b. 6 months old. c. 9 months old. d. 12 months old. e. 15 months old. f.

Results of Cobia oocyte cannulation aged 5-8 months in controlled tank (previtellogenic oocytes). g. The 9-month-old Cobia oocyte cannulation results in controlled tank (previtellogenic-PV and vitellogenic-V oocytes). h. Pituitary. i. Pituitary longitudinal slices,  $\alpha$  = acidophil cells,  $\beta$  = basophil cells. j. Results of measurement of FSH concentrations.

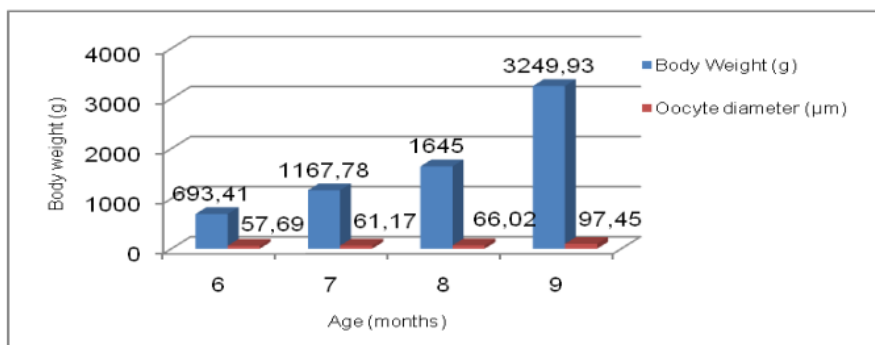


Fig 2. Graphics of body weight growth and oocyte diameter growth of Cobia fish kept on controlled tank.

#### 4. CONCLUSION

Based on the description above it can be concluded that cultivated female Cobia fish begins to progress gonad development to the stage of vitellogenesis and maturation at the age of 9 months.

#### ACKNOWLEDGMENT

The author would like to thank to Marine and Fisheries Human Resources Research and Resources Agency, Marine and Fisheries Ministry for providing the fellowship, thanks also to MCMA Lampung for the support of facilities.

#### REFERENCES

- [1] C. I. Liao, T. Huang, W. Tsai, C. Hsueh, S. Chang and L. M. Eduardo, Cobia culture in Taiwan: current status and problem, *Aquaculture* 237 (1-4) : 155-165, 2004.
- [2] G. J. Holt and C. K. Faulk, *Advances in Cobia *Rachycentron canadum* research in Texas*, <https://www.researchgate.net/publication/267452190>, 2007.
- [3] G. Gopakumar, A. K. A. Nazar, G. Tamilmani, M. Sakthivel, C. Kalidas, N. Ramamoorthy, S. Palanichamy, V. A. Maharshi, K. S. Rao and G. S. Rao, Broodstock development and controlled breeding of Cobia *Rachycentron canadum* (Linnaeus 1766) from Indian Seas, *Indian. J. Fish.* 58(4): 27-32, 2011.
- [4] V. C. Nhu, H. Q. Nguyen, T. L. Le, M. T. Tran, P. Sorgeloos, K. Dierckens, H. Reinertsen, E. Kjørsvik and N. Svennevig, Cobia *Rachycentron canadum* aquaculture in Vietnam: recent developments and prospects, *Aquaculture*, 315: 20 – 25, 2011.
- [5] P. Lee, L. Dutney, A. Elizur, S. Poole, A. Forrest, J. Moloney and M. Mitris, The development of an Australian Cobia aquaculture industry. The Seafood CRC Company Ltd, The Fisheries Research and Development Corporation and Department of Agriculture and Fisheries, 55 p, 2015.
- [6] Bantolo, KKP produksi ikan king kobia secara massal, <https://indonesiainside.id/ekonomi/2019/11/06/kkp-produksi-ikan-king-kobia-secara-massal>, 2019.
- [7] R. V. Shaffer and E. L. Nakamura, *Synopsis of Biological Data on the Cobia, *Rachycentron canadum**, (Pisces: Rachycentridae). U. S. Department of Commerce, 30 p, 1989.
- [8] L. Dutney, A. Elizur and P. Lee, Analysis of sexually dimorphic growth in captive reared Cobia (*Rachycentron canadum*) and the occurrence of intersex individuals, *Aquaculture*, doi: 10.1016/j.aquaculture.2016.09.04, 2016.
- [9] Vazzoler, A. E. A. M, *Biologia da reprodução de peixes teleosteos: teoria e prática*, EDUEM, Maringá, 1996.
- [10] A.C. Bomfim, D. Peretti, C. S. Camillo, S. A.G. L. Costa and R. S. S. Nascimento, Reproductive biology and variations in the gonadal development of the fish

- Curimata (*Prochilodus brevis* Steindachner, 1875) in captivity, Biota Amazonia, Macapa: 5(2): 65-70, 2015.
- [11] P. M. Biesiot, R. E. Caylor and J. S. Franks, Biochemical and histological changes during ovarian development of Cobia, *Rachycentron canadum*, From The Northern Gulf of Mexico, Fishery Bulletin, 92(4): 686-696, 1994.
- [12] J. M. Lotz, R. M. Overstreet and J. S. Franks, Gonadal maturation in the Cobia, *Rachycentron canadum*, from the Northcentral Gulf of Mexico, Gulf Research Reports, 9(3): 147 – 159, 1996.
- [13] N. J. B. Brown - Peterson, R. M. Overstreet, J. M. Lotz, J. S. Franks and K. M. Burns, 2000, Reproductive biology of Cobia, *Rachycentron canadum*, from the coastal waters of The Southern United States. Faculty Publications from The Harold W. Manter Laboratory of Parasitology. 410, <http://digitalcommons.unl.edu/parasitologyfac.pubs/410>, 2000.
- [14] N. J. Brown – Peterson, H. J. Grier and R. M. Overstreet, Annual changes in germinal epithelium determine male reproductive classes of the Cobia, Journal of Fish Biology, 60: 178 – 202, 2002.
- [15] T. D. V. D, Velde, S. P. Griffiths and G. C. Fry, Reproductive biology of the commercially and recreationally important Cobia *Rachycentron canadum* in Northeastern Australia, Fish Sci., 76: 33-43, 2010.
- [16] M. K. Sajeevan and B. M. Kurup, Length at first maturity of Cobia *Rachycentron canadum* (Linnaeus, 1766) from north-west coast of India. Indian J. Fish., 64(1): 72-74, 2017.
- [17] T. A. Babatunde, S. M. N. Amin, N. Romano, F. M. Yusoff, A. Arshad, Y. B. Esa and M. Ebrahimi, Gonad maturation and spawning of Cobia, *Rachycentron canadum* (Linnaeus, 1766) off the Dungun Coast, Malaysia, J Appl Ichthyol., 1–8, 2018.
- [18] N. Romano, W. Simon, M. Ebrahimi, A. H. I. Fadel, C. M. Chong and M. S. Kamarudin, Dietary sodium citrate improved oxidative stability in red hybrid tilapia (*Oreochromis* sp.) but reduced growth, health status, intestinal short chain fatty acids and induced liver damage, Aquaculture, 458, 170–176. <https://doi.org/10.1016/j.aquaculture.2016.03.014>, 2016.
- [19] R. M. Honji, D. Caneppele, M. Pandolfi, F. L. Nostro and R. G. Moreira, Gonadotropins and growth hormone family characterization in an endangered siluriform species, *Steindachneridion parahybae* (Pimelodidae): relationship with annual reproductive cycle and induced spawning in captivity, The Anatomical Record, 298: 1644 – 1658, 2015.
- [20] A. Stahl, A. Adenohypophysis cytophysiology on fish. In: Benoit, J., C. Da Lages., Eds. Adenohypophysis Cytophysiology. Paris. 331-344 (in French), 1963.
- [21] S. Vukovic, H. Lucic, M. D. Gomercic, A. Galov, T. Gomercic, S. Curkovic, D. Skrtic, G. Domitran and H. Gomercic, Anatomical and histological characteristics of the pituitary gland in the bottlenose dolphin (*Tursiops truncatus*) from the Adriatic Sea, Veterinarski Arhiv. 81 (1): 143-151, 2011.
- [22] T. Hibiya, An Atlas of Fish Histology, Gustow Fischer Verlag, Stuttgart, 1982.
- [23] A. Ekici and M. Timur, An anatomical and histochemical examination of pituitary gland of carp (*Cyprinus carpio*). Turk. J. Vet. Anim. Sci., 37: 399 – 403, 2013.
- [24] R. M. Honji, R. H. Nobrega, M. Pandolfi, A. Shimizu, M. I. Borela and R. G. Moreira, Immunohistochemical study of pituitary cells in wild and captive *Salminus hilarii* (Characiformes: Characidae) females during the annual reproductive cycle SpringerPlus, 2(460): 1-14, 2013.
- [25] R. M. Honji, D. Caneppele, M. Pandolfi and R. G. Moreira, Studies on the brain-pituitary-ovaries axis of *Steindachneridion parahybae* (Siluriformes: Pimelodidae) females when reproductive migration is blocked, In: 7th International Symposium on Fish Endocrinology. Vol. 1. 161p., 2012.

# THE EARLY GONADAL DEVELOPMENT

---

## ORIGINALITY REPORT

---

5%

SIMILARITY INDEX

%

INTERNET SOURCES

5%

PUBLICATIONS

%

STUDENT PAPERS

---

## PRIMARY SOURCES

---

1

Sridhar Reddy Vulapula, Srinivas Malladi. "Attribute-based Encryption for Fine-Grained Access Control on Secure Hybrid Clouds", International Journal of Advanced Computer Science and Applications, 2020

Publication

2%

2

EKİCİ, Aygül and TİMUR, Metin. "An anatomical and histochemical examination of the pituitary gland of carp (Cyprinus carpio)", TÜBİTAK, 2013.

Publication

1%

3

E. Clarke, C. Jantrachotechatchawan, Y. Buhidma, M. Broadstock, L. Yu, D. Howlett, D. Aarsland, C. Ballard, P.T. Francis. "Age-related neurochemical and behavioural changes in D409V/WT GBA1 mouse: Relevance to lewy body dementia", Neurochemistry International, 2019

Publication

1%

4

Robert H. Devlin, Yoshitaka Nagahama. "Sex determination and sex differentiation in fish: an

1%

overview of genetic, physiological, and environmental influences", Aquaculture, 2002

Publication

---

5

Robert E Caylor, Patricia M Biesiot, James S Franks. "Culture of cobia (*Rachycentron canadum*): cryopreservation of sperm and induced spawning", Aquaculture, 1994

Publication

---

<1%

6

John W. Tucker. "Marine Fish Culture", Springer Science and Business Media LLC, 1998

Publication

---

<1%

---

Exclude quotes      On

Exclude matches      Off

Exclude bibliography      On