

# Turnitin First Case Mild Symptoms COVID-19 in Rural Central Java Area: Case Report of an Indonesian Patient

*by Edward Kurnia Setiawan Limijadi*

---

**Submission date:** 09-May-2023 09:33AM (UTC+0700)

**Submission ID:** 2088157747

**File name:** oamjms-11c-068.pdf (371.31K)

**Word count:** 2135

**Character count:** 12248



# First Case Mild Symptoms COVID-19 in Rural Central Java Area: Case Report of an Indonesian Patient

Edward Kumia Setiawan Limjadi<sup>1,2\*</sup>, Inge Cahya Ramadhani<sup>3</sup>, Dian Tunjungsari Hartutiningtyas<sup>4</sup>, Gara Samara Brajadenta<sup>5</sup>

<sup>1</sup>Department of Clinical Pathology, Faculty of Medicine, Diponegoro University, Semarang, Central Java, Indonesia; <sup>2</sup>Department of Clinical Pathology, Ajibarang Regional Hospital, Central Java, Indonesia; <sup>3</sup>Department of Pulmonology and Respiratory Medicine, Ajibarang Regional Hospital, Central Java, Indonesia, <sup>4</sup>Department of Radiology, Ajibarang Regional Hospital, Central Java, Indonesia, <sup>5</sup>Department of Genetics, Faculty of Medicine, Universitas Swadaya Gunung Jati, Cirebon, West Java, Indonesia

## Abstract

**Edited by:** Mirko Spiroski  
**Citation:** Limjadi EKS, Ramadhani IC, Hartutiningtyas DT, Brajadenta GS. First Case Mild Symptoms COVID-19 in Rural Central Java Area: Case Report of an Indonesian Patient. Open Access Maced J Med Sci. 2023 Feb 24; 11(C):68-70. <https://doi.org/10.3889/oamjms.2023.10498>

**Keywords:** COVID-19; Indonesian patient; case report  
**\*Correspondence:** Edward Kumia Setiawan Limjadi, Department of Clinical Pathology, Faculty of Medicine, Diponegoro University, Ajibarang Regional Hospital, Jl. Raya Pancasila, Ajibarang, Central Java, Indonesia. E-mail: [edwardksl@fk.unidip.ac.id](mailto:edwardksl@fk.unidip.ac.id)

**Received:** 22-Jun-2022  
**Revised:** 03-Aug-2022  
**Accepted:** 14-Feb-2023

**Copyright:** © 2023 Edward Kumia Setiawan Limjadi, Inge Cahya Ramadhani, Dian Tunjungsari Hartutiningtyas, Gara Samara Brajadenta

**Funding:** This research did not receive any financial support  
**Competing Interests:** The authors have declared that no competing interests exist

**Open Access:** This is an open-access article distributed under the terms of the Creative Commons Attribution-NonCommercial 4.0 International License (CC BY-NC 4.0)

**BACKGROUND:** SARS-CoV-2 virus infection is a pandemic that began to emerge in December 2019 in various countries with high death rates of 4–9% until now. In March 2020, Indonesia found its first case where the condition of the infection kept spreading to various regions in Indonesia. Different regional conditions in Indonesia make it difficult to manage this virus infection. The capability of the regional hospitals to detect this virus infection with their facilities and infrastructure is required.

**CASE PRESENTATION:** A 17-year-old man came to the Ajibarang Regional Hospital with complaints of coughs and colds felt for 4 days and fever for 2 days. Physical examination found a good general condition, moderate pain, the temperature of 38.8°C, pharyngeal hyperemia, and minimal lung crackles sound. Laboratory tests showed normal leukocytes, platelet, and hemoglobin levels. Chest radiograph was suggestive of bronchitis. The patient was hospitalized for approximately 4 days until the fever resolved and was discharged. Five days after the patient was discharged from the hospital, the results of the viral load examination using real-time polymerase chain reaction confirmed positive for Coronavirus Disease 2019 (COVID-19).

**CONCLUSION:** This case showed unusual conditions of a mild clinical COVID-19 infection, laboratory results that did not support viral infections, as well as radiology examination of only bronchitis. The viral load test was found to be positive. Therefore, the diagnosis of the COVID-19 infection requires a comprehensive interpretation of complete history taking, clinical examination, laboratory, and radiology examinations for clinicians working with limited hospital facilities and infrastructures.

## Introduction

SARS-CoV-2 virus infection is a pandemic that began to emerge in December 2019 in various countries with high death rates of 4–9% until now [1], [2]. In March 2020, Indonesia found its first case where the condition of the infection kept spreading to various regions in Indonesia. Different regional conditions in Indonesia make it difficult to manage this virus infection. The capability of the regional hospitals to detect this virus infection with their facilities and infrastructure is required. The first case in Indonesia was a case of a patient with mild airway infection and the laboratory results of bacterial infections, but he claimed to be positively infected by Coronavirus Disease 2019 (COVID-19).

In this study, we describe pulmonary radiological and clinical features present in an Indonesian patient diagnosed with COVID-19 using real-time polymerase chain reaction (RT-PCR) method.

## Case Presentation

A 17-year-old man came to the Ajibarang Regional Hospital with complaints of coughs and colds felt for 4 days and fever felt for 2 days. He did not have difficulty in breathing. He explained that he went to Bali before experiencing the complaint. The patient's physical examination found a good general condition, moderate pain, the temperature of 38.8°C, pharyngeal hyperemia, and minimal lung crackles sound. Laboratory tests showed normal leukocytes, platelet, and hemoglobin levels. However, the laboratory tests also showed neutrophilia of 72%, lymphocytes of 20%, and monocytes of 8%. Examination of CRP levels showed increased results. Examination of liver and kidney function was within normal limits.

Furthermore, chest radiograph carried out to evaluate the condition of the lungs was suggestive of bronchitis which was an inflammation of the lower respiratory tract (Figure 1). However, the patient's lung

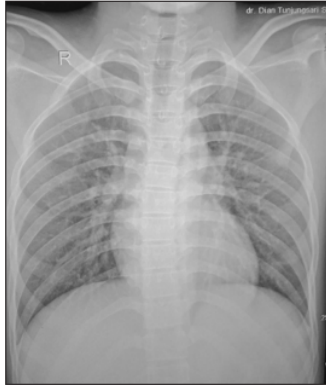


Figure 1: Chest radiograph of the patient. Radiographs showing bronchitis which include inflammation of the lower respiratory tract

image still classified as normal. The patient's clinical conditions, the laboratory, and radiology examination showed a usual respiratory infection and were still within normal limits. The clinicians suspected diagnosis of COVID-19 based on the patient's history of going to Bali where positive cases found, and suspicion of local transmission.

The clinicians referred the patient to higher-level hospitals in the district for further examinations, namely, the nasopharyngeal swab for COVID-19 viral load testing.

Molecular analysis was conducted in the patient using RT-PCR method and revealed positive COVID-19. RNA virus was isolated from nasopharyngeal swab using Ilustra RNAs pin Minikit. The PCR reactions were performed in 96-well plates containing a final volume of 15  $\mu$ L: 10  $\mu$ L of TaqMan Universal PCR Master Mix (Applied Biosystems), 1.5  $\mu$ L of 20  $\mu$ M forward and reverse primers including 10  $\mu$ M specific TaqMan probe, 0.4  $\mu$ L Platinum Taq Mix, 3.1  $\mu$ L of distilled water, and 5  $\mu$ L of RNA. The PCR amplification program is successively composed of activation of Taq polymerase for 15 min at 50°C and 2 min at 95°C followed by 45 PCR cycles: 3 s at 95°C and 30 s at 55°C. PCR reactions were performed on a 7500 Fast RTPCR System (Applied Biosystems). The sequence of oligonucleotides (Eurogentec) used for RTPCR is listed in Table 1.

Table 1: Sequences of RT-PCR oligonucleotides

Gene	Primers	Sequences
N1	Forward	GACCCAAAATCAGCGAAAT
	Reverse	TCTGGTACTGCCAGTTGAATCTG
	Internal probe	ACCOCGCATTACGTTTGGTGGACC
N2	Forward	TTACAAACATTGGCCGAAA
	Reverse	GCGGACATTCCGAAGAA
	Internal probe	ACAATTTGCCCCAGCGCTTCAG
RP	Forward	AGATTTGGACCTGCGAGCG
	Reverse	GAGCGGCTGTCTCCACAAT
	Internal probe	TTCTGACCTGAAGGCTCTGCGG

Internal probes are labeled at the 5'-end with the reporter molecule 6-carboxyfluorescein (FAM).

The patient was hospitalized for approximately 4 days until the fever resolved and was discharged. Five

days after the patient was discharged from the hospital, the results of the viral load examination confirmed positive for COVID-19.

## Discussion and Conclusion

This is a case report of COVID-19 from an Indonesian patient in rural Central Java confirmed by RT-PCR analysis. COVID-19 infection showed mild symptoms of fever and other symptoms of upper respiratory tract infections. Cao *et al.* (2020) and Cheng *et al.* (2020) explained that patients with COVID-19 infection had a fever, cough, or other respiratory infections symptoms [3], [4]. The patient's laboratory examination showed neutrophilia with normal lymphocytes, leukocytes, platelets, and hemoglobin levels. This situation is not common conditions found in COVID-19 infections where there should be leukopenia, thrombocytopenia, lymphopenia, and mild anemia [5], [6]. Some publications explained that COVID-19 patients had various laboratory results although generally found to be the same as previously described. The examination results of liver and kidney function of this patient were also within normal limits. Some cases reported an increased liver and kidney function, possibly due to the comorbid diseases. This variation in laboratory results has yet to be explained in detail and requires further research. Examination of inflammatory markers of CRP showed increased CRP levels due to the pro-inflammatory cytokine response to COVID-19 infection. Several cases reported the same significant increase in inflammatory markers according to the severity of the infection.

The viral load test followed by RT-PCR is currently considered to be a definitive diagnosis of COVID-19 infection [7]. A viral load test is positively related to RT-PCR result according to Zou *et al.* [8]. The presence of *N1*, *N2*, and *RP* genes was consistent with the diagnosis of COVID-19. This case showed unusual conditions of a mild clinical COVID-19 infection, laboratory results that did not support viral infections, as well as radiology examination of only bronchitis. COVID-19 patients usually show mild-to-severe pneumonia or if there is a CT-scan facility, it shows ground glass appearance. On the contrary, the radiology in this case only showed bronchitis, that clinician could conclude with general bronchitis that normally happened to the man. Here, we did not examine the CT scan because of the lack of equipment in the district hospital, so we could not find ground glass appearance. Because of the history taking of the patient, clinician decided to do the RT-PCR analysis for COVID-19 in the referral laboratory and it needs more time to diagnosis.

The patient was treated with high dose Vitamin C, anti-viral medication, good nutrition, also

with self-hygiene, and isolation. Patient was stated recover after second examination in 14 days after first test by RT-PCR analysis. The immune system in the body plays important roles for curing the viral infection specially SARS-CoV-2. The patient is still young, and he had a good condition, there was no comorbid can influence the worsening of COVID-19 infection.

Therefore, from this case, the diagnosis of the COVID-19 infection requires a comprehensive interpretation of complete history taking, clinical examination, laboratory, and radiology examinations for clinicians working with limited hospital facilities and infrastructures. In spite of the accessibility of molecular testing in a few parts of the world, the acknowledgement of clinically well-defined sign and symptoms will remain exceptionally imperative in developing countries with a lack of diagnostic facilities.

### Consent for Publication

Written informed consent was obtained from the patient for publication of this case report and any accompanying images. A copy of the written consent is available for review by the Editor-in-Chief of this journal.

### Availability of Data and Material

All data generated or analyzed during this study are included in this published article.

### Authors' Contribution

Limijadi EKS performed the experiments, designed, drafted and reviewed the manuscript. Ramadhani IC and Hartutiningtyas DT collected the blood sample, clinical details, X-ray, and photographs of this case report. Brajadenta GS verified the molecular analysis and reviewed the manuscript. Each of the authors participated in drafting the manuscript, and

each author read and approved the final version of this paper.

### Acknowledgments

The authors would like to thank the patient and his family for participation in this study. We thank also laboratory Balai Kesehatan dan Kalibrasi Yogyakarta.

### References

1. World Health Organization. Corona Virus Disease 2019 (COVID-19) Situation Report-59. Geneva: World Health Organization; 2020. p. 1-11.
2. John Hopkins University and Medicine. Corona COVID-19 Global Cases by the Center for Systems Science and Engineering. Available from: <https://www.coronavirus.jhu.edu/map.html> [Last accessed on 2020 Mar 25].
3. Cao W, Shi L, Chen L, Xu X, Wu Z. Clinical features and laboratory inspection of novel coronavirus pneumonia (COVID-19) in Xiangyang, Hubei. *MedRxiv*. 2020. <https://doi.org/10.1101/2020.02.23.20026963>
4. Cheng SC, Chang YC, Chiang YL, Chien YC, Cheng M, Yang CH, *et al*. First case of coronavirus disease 2019 (COVID-19) pneumonia in Taiwan. *J Formos Med Assoc*. 2020;119(3):747-51. <https://doi.org/10.1016/j.jfma.2020.02.007> PMID:32113824
5. Lippi G, Plebani M. Laboratory abnormalities in patients with COVID-2019 infection. *Clin Chem Lab Med*. 2020;58(7):1131-4. <https://doi.org/10.1515/cclm-2020-0198> PMID:32119647
6. Chen N, Zhou M, Dong X, Qu J, Gong F, Han Y, *et al*. Epidemiological and clinical characteristics of 99 cases of 2019 novel coronavirus pneumonia in Wuhan, China: A descriptive study. *Lancet*. 2020;395(10223):507-13. [https://doi.org/10.1016/S0140-6736\(20\)30211-7](https://doi.org/10.1016/S0140-6736(20)30211-7) PMID:32007143
7. Corman VM, Landt O, Kaiser M, Molenkamp R, Meijer A, Chu DK, *et al*. Detection of 2019 novel coronavirus (2019-nCoV) by real-time RT-PCR. *Euro Surveill*. 2020;25(3):2000045. <https://doi.org/10.2807/1560-7917.ES.2020.25.3.2000045> PMID:31992387
8. Zou L, Ruan F, Huang M, Liang L, Huang H, Hong Z, *et al*. ARS-CoV-2 viral load in upper respiratory specimens of infected patients. *N Engl J Med*. 2020;382(12):1177-9. <https://doi.org/10.1056/NEJMc2001737> PMID:32074444

# Turnitin First Case Mild Symptoms COVID-19 in Rural Central Java Area: Case Report of an Indonesian Patient

---

GRADEMARK REPORT

---

FINAL GRADE

**/0**

GENERAL COMMENTS

**Instructor**

---

PAGE 1

---

PAGE 2

---

PAGE 3

---

---

**PENDAHULUAN (15%)**

0 / 6

SANGAT BAGUS

(6)

BAGUS

(4)

KURANG

(2)

---

**ISI (50%)**

0 / 6

SANGAT BAGUS

(6)

BAGUS

(4)

KURANG

(2)

---

**PENURUP (15%)**

0 / 6

SANGAT BAGUS

(6)

BAGUS

(4)

KURANG

(2)