

Lampiran Peer Review Korespondensi Proses Submit Publikasi Internasional

Nama Jurnal : Open Access Macedonian Journal of Medical Sciences

Volume : 10 (E)

No. ISSN : 1857-9655

DOI : <https://doi.org/10.3889/oamjms.2022.9716>

H Index : 28

SJR Index : 0.257

Reputasi : Q3

Judul Artikel : Topical Role Of Ozonated Aloe Vera Oil In Radiation Dermatitis : Expression Of TGF- β and Collagen Density

Item	Halaman
Submission Received+Original Paper (9 April 2022)	2
Comment Reviewer (23 April)	15
Respond to Reviewer	17
Accepted for Publication (10 Mei 2022)	28
Galley Proof (11 July 2022)	29
Paper has been Published (2 Juni 2022)	30

mail.google.com

Gmail

Compose

Inbox 403

Starred

Snoozed

Important

Sent

Drafts 3

Categories

- Social 937
- Updates 399
- Forums
- Promotions 786
- More

Labels

- intan
- Personal
- More

Search mail

[OAMJMS] Submission Acknowledgement

Prof. Dr Mirko Spiroski via SFS - Journals (Scientific Foundation SPIROSKI - Journals), Skopje, Republic of Maced... Apr 9, 2022, 5:28 AM

Intan Pratama Neelanaviri Putri

Thank you for submitting the manuscript, "Topical Role of Ozonated Aloe Vera Oil in Radiation Dermatitis: Expression of TGF- β and Collagen Distribution" to Open Access Macedonian Journal of Medical Sciences. With the online journal management system that we are using, you will be able to track its progress through the editorial process by logging in to the journal web site:

Submission URL: <https://oamjms.eu/index.php/mjms/authorDashboard/submission/9716>
Username: intan09

If you have any questions, please contact me. Thank you for considering this journal as a venue for your work.

Prof. Dr Mirko Spiroski

Reply Forward

Topical Role of Ozonated Aloe Vera Oil in Radiation Dermatitis: Expression of TGF- β and Collagen Distribution

Intan Pratama Naelanaviri Putri¹, Yan Wisnu Prajoko^{1,2}, Christina Hari Nawangsih Prihharsanti^{1,3},
Udadi Sadhana^{1,4}, Neni Susilaningsih^{1,5}

1. Biomedical Science, Faculty of Medicine, Universitas Diponegoro, Semarang, Indonesia
2. Department of Surgical Oncology, Faculty of Medicine, Universitas Diponegoro, Dr. Kariadi General Hospital, Semarang, Indonesia;
3. Department of Radiology, Faculty of Medicine, Universitas Diponegoro, Dr. Kariadi General Hospital, Semarang, Indonesia
4. Department of Anatomical Pathology, Faculty of Medicine, Universitas Diponegoro, Semarang, Indonesia.
5. Department of Histology, Faculty of Medicine, Universitas Diponegoro, Semarang, Indonesia

Topical Role of Ozonated Aloe Vera Oil in Radiation Dermatitis: Expression of TGF- β and Collagen Distribution

Abstract

Background: Until now, the effect of ozonated aloe vera in the treatment of radiation dermatitis has not been studied, while long-term use of topical steroids can cause some side effects. This study aimed to analyze the effect of topical administration of ozonated aloe vera oil on the Expression of TGF- β and collagen distribution in the treatment of radiation dermatitis in Sprague Dawley rats. **Methods:** This study is an experimental laboratory study with a “post-test only control group design.” The samples used were 36 adult male Sprague Dawley rats. The independent variables were: Ozonated aloe vera oil of 300 mg/ml, 600 mg/ml and 1200mg/ml while the dependent variable were: the Expression of TGF- β and Collagen Distribution. Research and data collection was carried out for 4 weeks. This study was carried out in August 2021 to September 2021. **Results:** The results of the measurement of the Expression of TGF- β with the ANNOVA test showed a significance of $p=0.001$ ($p<0.05$), meaning that there was a significant difference in the treatment between groups. In the Post Hoc LSD test, there was a significant difference between the control group and the AV, Ozonated AV 300mg, Ozonated AV 600mg and Ozonated 1200 groups; also there was a significant difference between the hydrocortisone group and the ozonated AV 300mg, ozonated AV 600mg and ozonated AV 1200mg groups. The results of the measurement of Collagen Distribution with the Kruskal-Wallis test showed a significance of $p=<0.001$ ($p<0.05$), meaning that there was a significant difference in the treatment between groups. In the Post Hoc Mann-Whitney test, there was a significant difference between the control group and the AV, Ozonated AV 300mg, Ozonated AV 600mg and Ozonated 1200 groups; also there was a significant difference between the Hydrocortisone group and the Ozonated AV 300 mg, Ozonated AV 600 mg and Ozonated AV 1200 mg groups. The results of the Spearman's rho correlation test showed a value of $p = <0.001$ and $r = 0.722$, from these results, it can be concluded that there was a strong and unidirectional significant correlation between TGF- β to collagen. **Conclusion:** There was a significant correlation between the Expression of TGF- β and collagen distribution in healing radiation dermatitis.

Keywords: Topical Ozonated Aloe Vera Oil, Expression of TGF- β , Collagen Distribution, Healing Radiation Dermatitis

Introduction

Dermatitis is an inflammatory skin reaction that is sensitive to various endogenous and/or exogenous stimuli, causing clinical abnormalities in the form of polymorphic fluorescence (erythema, edema, papules, vesicles, scales, lichenification) and itching complaints. Polymorphic signals do not always occur simultaneously, maybe even only a few (oligomorphic) [1].

Radiation is one of the causes of dermatitis, often found in patients undergoing radiotherapy. Acute and chronic damage from radiation is a collection of damage to germ cells [2]. Acute side effects (in hours) that appear are in the form of itching, erythema, dryness, cracking and pain ranging from mild to severe [3]. Radiation reduces neovascularization, fibroblast proliferation, collagen deposition and level of growth factors for wound healing. The inhibited growth factors are *transforming growth factor β -1* (TGF β -1) and *basic fibroblast growth factor* (bFGF) in the acute phase, where the inhibition of TGF β -1 will also inhibit other controlled components, namely fibroblast proliferation, transformation into myofibroblasts, stimulation of extracellular matrix production and collagen distribution [4].

Wound healing is complex processes with cellular and molecular mechanisms. The success of wound healing depends on the inflammatory process, cell proliferation, angiogenesis, wound contraction, epithelialization and matrix remodeling. These processes require the continuous function of neutrophils, macrophages, fibroblasts and endothelial cells to regulate interactions between cells, extracellular matrix proteins and growth factors. Disruption of any of these healing processes will result in abnormal wound healing [4]. Collagen contributes a lot to wound healing. Collagen affects the mechanical strength and elasticity of tissues and acts as a natural substrate for cellular attachment, proliferation and differentiation. Collagen is a key component of the extracellular matrix that plays an important role in the regulation of the wound healing phase whether in its native, fibrillar conformation or as a soluble component in the wound environment [4].

Topical steroids have long been used for the prevention and treatment of radiation-induced toxic

dermatitis. There are several studies stating that the use of topical steroids can reduce burning, itching and erythema and slow the progression of the skin. However, long-term use of steroids can cause several local and systemic side effects, thus many studies have been carried out with herbal plants as replacement therapy for topical steroids [5].

Oral and topical administration of aloe vera gel was reported to be effective in wound healing. In a recent study, aloe vera gel or its extract content, namely *acemannan*, *β sitosterol* and others, has been reported to cause faster wound healing by stimulating fibroblast proliferation, collagen deposition, angiogenesis and growth factor production [4]. In addition, aloe vera also increases TGF- β gene expression which will accelerate the wound healing process [6].

Ozone (O₃) is a much stronger oxidant than oxygen and has the ability to oxidize many substances that are inert to oxygen under normal conditions [7]. Ozone is widely recognized as one of the best bactericidal, antiviral and antifungal agents, which currently are used as therapeutic mediators in wounds to reduce bacterial infection, heal skin damage and increase oxygen tension on exposure [8].

Until now, the effect of ozonated aloe vera in the treatment of radiation dermatitis has not been studied, while long-term use of topical steroids can cause some side effects. This study aimed to compare the expression of TGF- β and collagen distribution between the topical administration of ozonated aloe vera oil in various doses groups and the control group on the healing of radiation dermatitis in Sprague Dawley rats on day 7 and analyze the effect of topical administration of ozonated aloe vera oil on the expression of TGF- β and collagen distribution on the healing of radiation dermatitis in Sprague Dawley rats on day 7.

Methods

Research Design

This study is an experimental laboratory study with a “post-test only control group design.” The samples used were 36 adult male Sprague Dawley rats weighing 150±50 grams which received external gamma ray radiation of 7 Gy on the back; and there were 3 rats that died after receiving radiation, so the number of samples became 33 adult male Sprague Dawley rats.

Experimental animal samples were randomly divided into 6 groups, two control groups and four treatment groups, namely K1, K2, P1, P2, P3 and P4. The K1 group was a negative control consisted of 5 rats that did not receive topical therapy and the K2 group was a positive control consisted of 5 rats that received topical therapy with hydrocortisone cream 2.5%, the P1 group consisted of 5 rats that received aloe vera oil therapy, while the P2, P3, P4 groups consisted of 6 rats in each group that received treatment with ozonated aloe vera oil at doses of 300 mg/ml, 600 mg/ml and 1200 mg/ml. After 7 days of treatment, termination was carried out and continued with microscopic examination to see the expression of TGF- β and collagen distribution.

The K1, K2, P1, P2, P3 and P4 groups were terminated on day 7 to be performed with wound tissue taking (sampling), preparations making, as well as histopathological and immunohistochemical staining.

Research sample

In this study, white rats of the Sprague Dawley strain that were obtained from the Experimental Animal Laboratory of Universitas Islam Sultan Agung, Semarang were used. The inclusion criteria were male rats, 2-3 months old and weighing 150±50 grams. Meanwhile, the exclusion criteria were anatomical abnormalities. During the acclimatization and treatment period, there were rats that looked sick (inactive motion) or died. The WHO sample size for each group was at least five experimental animals, with a reserve of 10-20% (1 head) [9]. Thus, the number of samples used in this study for each group was 6 rats.

Research variables

The independent variables were: Ozonated aloe vera oil of 300 mg/ml, 600 mg/ml and 1200mg/ml while the dependent variable were: the Expression of TGF- β and Collagen Distribution.

Research settings (Research time and location)

Research and data collection was carried out for 4 weeks. Research and data collection was carried out for 4 weeks. This study was carried out in August 2021 to September 2021.

1. The production of ozonated aloe vera oil was carried out at the Center for Plasma Research, Universitas Diponegoro, Semarang.
2. The external radiation process was carried out at the radiotherapy installation of Ken Saras Hospital, Semarang.
3. The care, rats treatment, tissue collection and hematoxylin-eosin staining processes were carried out at the Experimental Animal Laboratory of Universitas Islam Sultan Agung, Semarang.
4. The TGF- β immunohistochemical staining process was carried out at the Department of Anatomical Pathology, Faculty of Medicine, Universitas Sebelas Maret, Solo.
5. The TGF- β and collagen distribution measurement process was carried out at the Department of Anatomical Pathology, Faculty of Medicine, Universitas Diponegoro, Semarang.

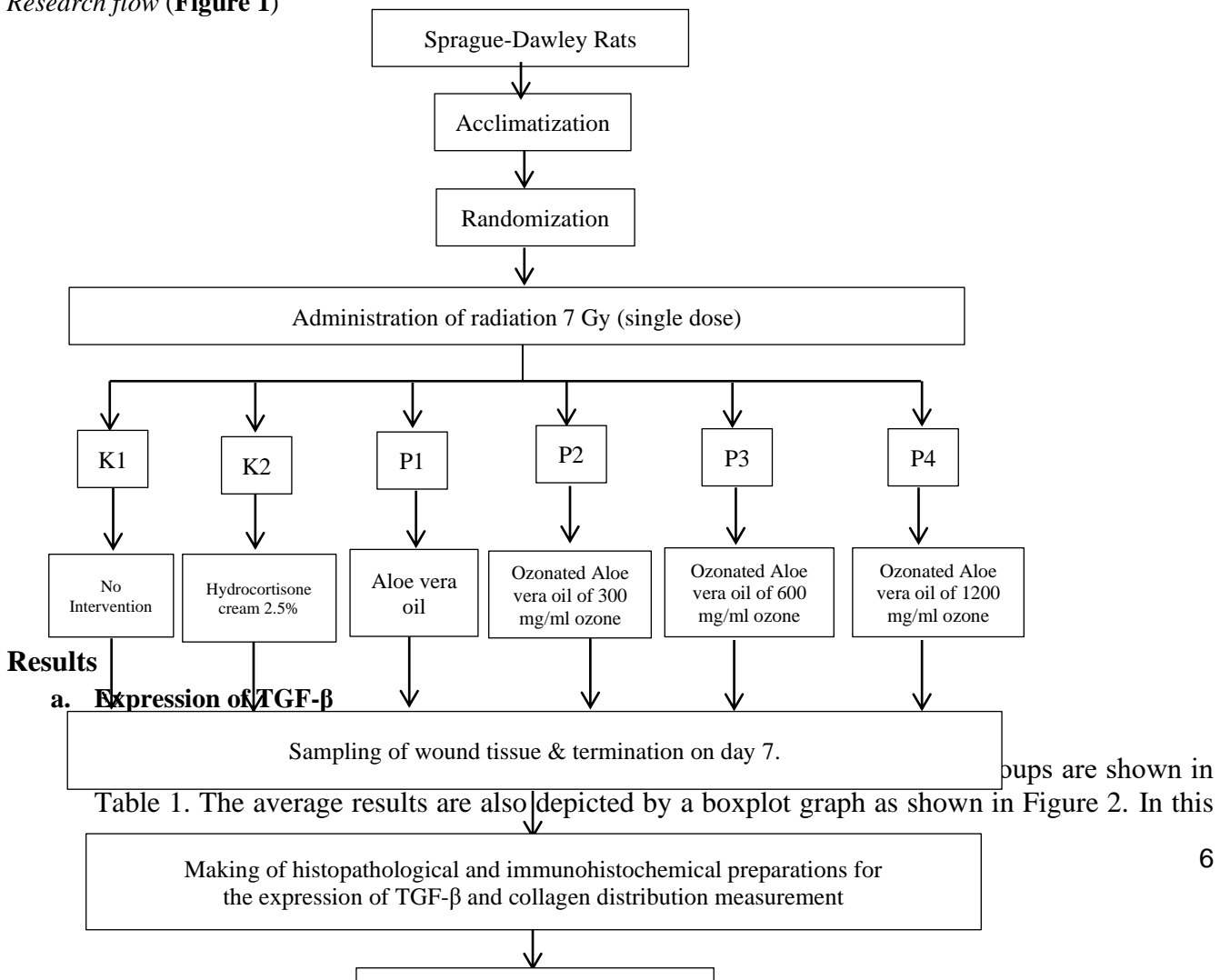
Tools and materials

The experimental animals used were male rats of the Sprague Dawley strain, 2-3 months old and weighing 150 \pm 50 grams. Rats were obtained from the Experimental Animal Laboratory of Universitas Islam Sultan Agung, Semarang. Rats were acclimatized in the laboratory for one week in individual cages with a period of 12 hours of light and 12 hours of darkness. Rats were fed and given water ad libitum. Treatment of radiation dermatitis making was carried out after acclimatization.

Ozonated aloe vera oil was obtained from the Center for Plasma Research, Universitas Diponegoro, which was generated by mixing ozone produced by the ozone generator into the oil. A magnetic stirrer was used to facilitate the mixing of ozone with oil so as to obtain ozonated aloe vera oil which was ready to be used as treatment materials. Ozonated oil samples were taken to be tested using a spectrometer or dissolved ozone meter kit. Measurement of ozone levels in ozonated oil was carried out using the potassium iodide titration method.

The tools and materials for radiation used included Ketamine, Xylazine, Markers, 1 cc Syringe and 27G Needle, Cobalt Radiotherapy Machine 2. Furthermore, tools and materials for microscopic examination used included 60 $^{\circ}$ C temperature incubator, Paraffin, Microtome, Hematoxylin Eosin (HE), Formalin buffer 10%, Alcohol 50%, 70%, 80%, 96%, Absolute, Xylol, Glass Slides and Covers and TGF- β Antibodies.

Research flow (Figure 1)



study, the normality test was carried out using the Shapiro Wilk test, while the homogeneity test was carried out using the Levene's test. The Shapiro Wilk test is intended to show that the sample come from a normally distributed population, but if the significance obtained is less than 0.05 then the sample data do not come from a normally distributed population. The results of the Shapphiro Wilk test for the Expression of TGF- β showed a significance of $p > 0.05$ in all groups as shown in Table 1 below. This shows that the data were normally distributed.

Table 1. Descriptive and normality test results of the Expression of TGF- β using the Sapphiro – Wilk

Group	Average score \pm SD	median (min – max)	p	Note.
Control	3.60 \pm 0.40	3.6 (3.2 – 4.0)	0.119	N
Hydrocortisone	4.20 \pm 1.02	4.2 (3.0 – 5.4)	0.692	N
Aloe vera	5.00 \pm 0.81	4.8 (4.2 – 6.2)	0.627	N
Ozonated AV 300 mg	5.33 \pm 0.63	5.0 (4.8 – 6.4)	0.054	N
Ozonated AV 600 mg	5.47 \pm 0.78	5.5 (4.2 – 6.4)	0.741	N
Ozonated AV 1200 mg	5.93 \pm 1.17	5.5 (5.0 – 8.0)	0.124	N

Description: N = Normal, Normal ($p > 0.05$)

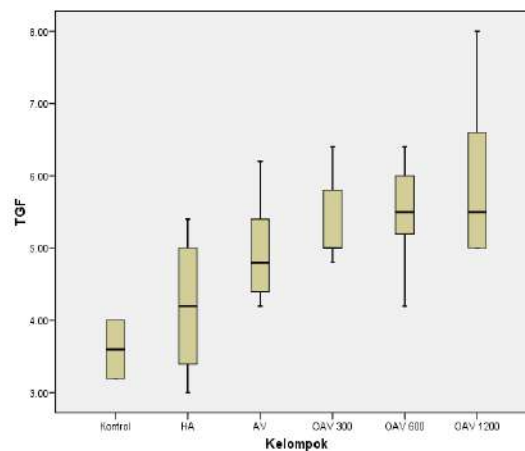


Figure 2. Boxplot Graph of the Expression of TGF- β of Research Samples

After the normality test was carried out, it was continued with the Levene's test to determine the homogeneity of the sample variations. The Levene's test results showed a significance of $p = 0.280$ ($p > 0.05$) indicating that the population variance was homogeneous and the assumptions were met, thus fulfilling the requirements for the ANOVA test.

Table 1. One Way Anova Test Results of the Expression of TGF- β

Group	Mean \pm SD	p	Levene
Control	3.60 \pm 0.40	0.001	0.280
HA	4.20 \pm 1.02		
AV	5.00 \pm 0.81		
Ozonated AV 300 mg	5.33 \pm 0.63		
Ozonated AV 600 mg	5.47 \pm 0.78		
Ozonated AV 1200 mg	5.93 \pm 1.17		

Description: * Significant ($p < 0.05$); ** Homogeneous ($p > 0.05$)

The results of the ANOVA test showed a significance of $p = 0.001$ ($p < 0.05$), meaning that that there was a significant difference in the treatment between groups. To find out which groups were significantly different, a follow-up LSD test was carried out. The results of the LSD test are shown in Table 3.

Table 3. Post hoc LSD Test Results of the Expression of TGF- β

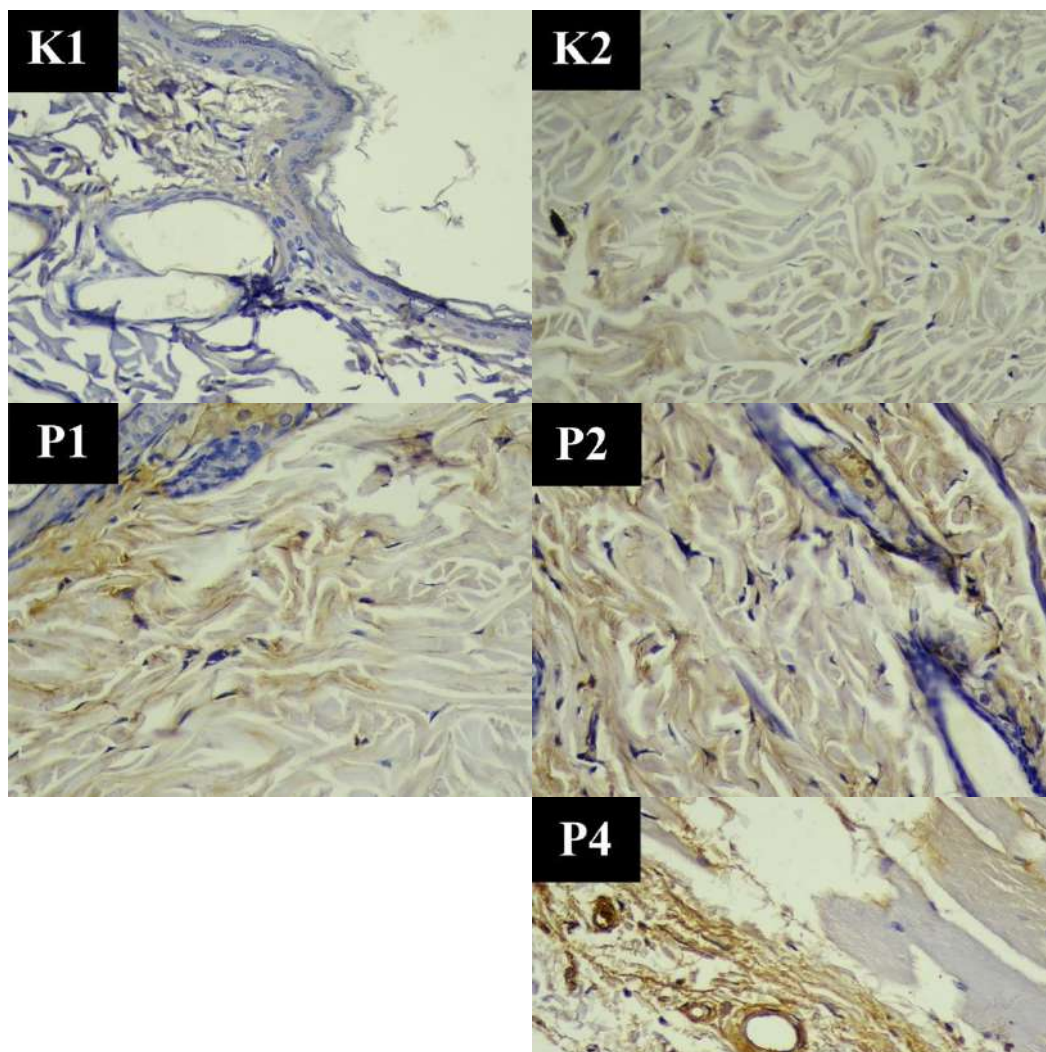
Group		p	Information
I	II		
Control	Hydrocortisone	0.271	Not significant

Group		p	Information
I	II		
	AV	0.014	Significant
	Ozonated AV 300 mg	0.002	Significant
	Ozonated AV 600 mg	0.001	Significant
	Ozonated AV 1200 mg	<0.001	Significant
Hydrocortisone	AV	0.146	Not significant
	Ozonated AV 300 mg	0.035	Significant
	Ozonated AV 600 mg	0.020	Significant
	Ozonated AV 1200 mg	0.002	Significant
AV	Ozonated AV 300 mg	0.520	Not significant
	Ozonated AV 600 mg	0.370	Not significant
	Ozonated AV 1200 mg	0.079	Not significant
Ozonated AV 300 mg	Ozonated AV 600 mg	0.787	Not significant
	Ozonated AV 1200 mg	0.229	Not significant
Ozonated AV 600 mg	Ozonated AV 1200 mg	0.347	Not significant

In the Post Hoc LSD test, there was a significant difference between the control group and the AV, Ozonated AV 300mg, Ozonated AV 600mg and Ozonated 1200 groups, also there was a significant difference between the hydrocortisone group and the Ozonated AV 300mg, Ozonated AV 600mg and Ozonated AV 1200mg groups.

b. Overview of TGF-β Immunohistochemical Examination

Based on immunohistochemical examination of TGF-β from wound tissue cuts in experimental animals in this study, the results were obtained as shown in Figure 3 below.



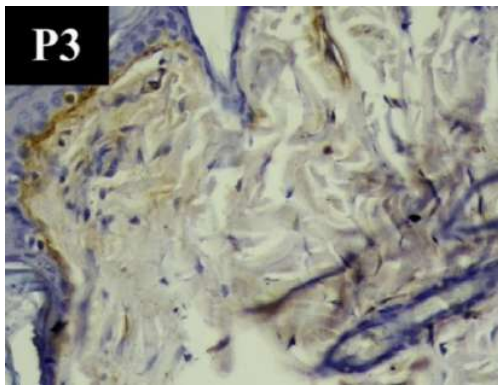


Figure 3. Immunohistochemical description of TGF- β wound tissue of Sprague Dawley Rats, K1. Without intervention, K2. Hydrocortisone cream 2.5%, P1. Aloe vera oil, P2. Ozonated Aloe vera oil of 300 mg/ml ozone, P3. Ozonated Aloe vera oil of 600 mg/ml ozone, P4. Ozonated Aloe vera oil of 1,200 mg/ml ozone.

c. Collagen Distribution

Statistical Test of Collagen Distribution

The results of collagen distribution measurement for all study groups are shown in Table 4. The average results are also depicted by a boxplot graph as shown in Figure 5. The results of the Shapiro Wilk test for collagen distribution showed a significance of $p > 0.05$ in all groups except the P4 group ($p = 0.003$) as shown in the following table. This shows that the data were not normally distributed and the ANOVA requirements were not met, so the analysis was continued with the Kruskal-Wallis test.

Table 2. Normality test results of collagen distribution using the Shappiro-wilk

Group	N	Mean \pm SD	median (min – max)	p	Note.
Control	5	3.92 \pm 0.44	3.8 (3.4 – 4.6)	0.607	N
HA	5	5.44 \pm 0.62	5.6 (4.6 – 6.0)	0.332	N
AV	5	5.72 \pm 0.33	5.8 (5.2 – 6.0)	0.314	N
Ozonated AV 300 mg	6	6.77 \pm 0.27	6.8 (6.4 – 7.0)	0.065	N
Ozonated AV 600 mg	6	7.27 \pm 0.27	7.2 (7.0 – 7.6)	0.093	N
Ozonated AV 1200 mg	6	7.33 \pm 0.24	7.2 (7.2 – 7.8)	0.003	TN

Description: N = Normal, TN = Abnormal, Normal ($p > 0.05$)

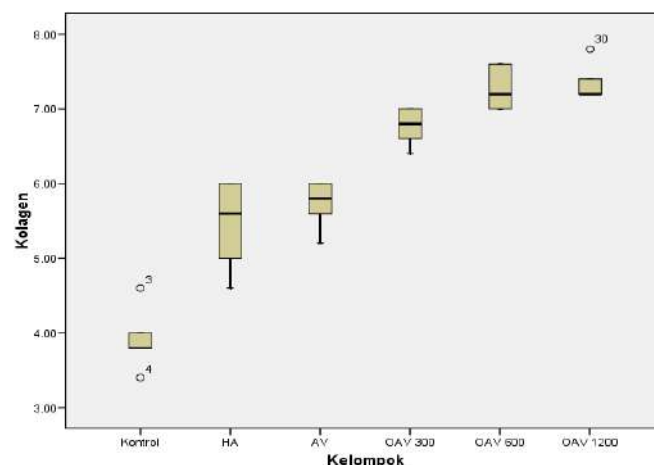


Figure 5. Boxplot Graph of Collagen Distribution of Research Samples

Table 4.3 Kruskal-Wallis test results of Collagen distribution

Group	Mean \pm SD	p
-------	---------------	---

Control	3.92±0.44	<0.001
HA	5.44 ± 0.62	
AV	5.72 ± 0.33	
Ozonated AV 300 mg	6.77±0.27	
Ozonated AV 600 mg	7.27±0.27	
Ozonated AV 1200 mg	7.33±0.24	

The results of the Kruskal-Wallis test showed a significance of $p < 0.001$ ($p < 0.05$), meaning that there was a significant difference in the treatment between groups. To find out which group were significantly different, a follow-up Mann-Whitney test was carried out. The results of the Mann-Whitney test are shown in Table 5.

Table 5. Post hoc Mann-Whitney Test Results of Collagen Distribution

Group		p	Information
I	II		
Control	HA	0.011	Significant
	AV	0.009	Significant
	Ozonated AV 300 mg	0.005	Significant
	Ozonated AV 600 mg	0.006	Significant
	Ozonated AV 1200 mg	0.005	Significant
HA	AV	0.517	Not significant
	Ozonated AV 300 mg	0.005	Significant
	Ozonated AV 600 mg	0.006	Significant
	Ozonated AV 1200 mg	0.005	Significant
AV	Ozonated AV 300 mg	0.005	Significant
	Ozonated AV 600 mg	0.006	Significant
	Ozonated AV 1200 mg	0.005	Significant
Ozonated AV 300 mg	Ozonated AV 600 mg	0.012	Significant
	Ozonated AV 1200 mg	0.003	Significant
Ozonated AV 600 mg	Ozonated AV 1200 mg	0.492	Not significant

In the Post Hoc Mann-Whitney test, there was a significant difference between the control group and the Hydrocortisone, AV, Ozonated AV 300mg, Ozonated AV 600mg and Ozonated 1200 groups; between the Hydrocortisone group and the Ozonated AV 300 mg, Ozonated AV 600 mg and Ozonated AV 1200 mg groups; between the AV group and the Ozonated AV 300 mg, Ozonated AV 600 mg and Ozonated AV 1200 mg. Furthermore, the Ozonated AV 300 mg group was significant to the Ozonated AV 600 mg and Ozonated AV 1200 mg groups.

d. Overview of Collagen Distribution Examination

Based on histological examination using H&E staining to assess the collagen distribution from wound tissue cuts in experimental animals in this study, the results are as shown in Figure 6 below.

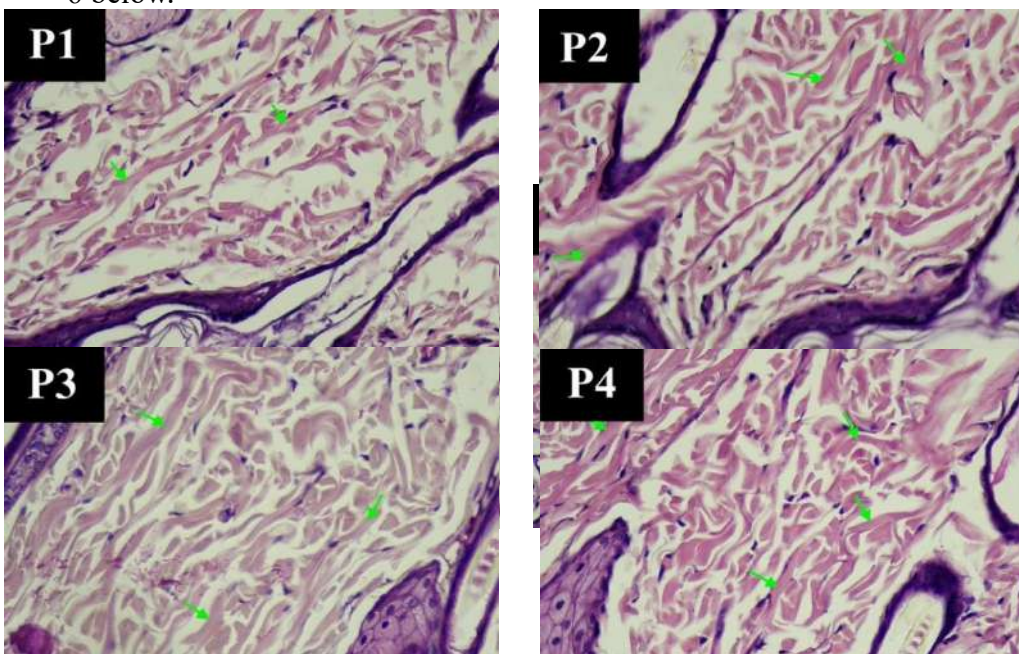


Figure 6. Collagen distribution using H&E staining of wound tissue of Sprague Dawley rats, K1. Without intervention, K2. Hydrocortisone cream 2.5%, P1. Aloe vera oil, P2. Ozonated Aloe vera oil of 300 mg/ml ozone, P3. Ozonated Aloe vera oil of 600 mg/ml ozone, P4. Ozonated Aloe vera oil of 1,200 mg/ml ozone.

e. Correlation between Expression of TGF- β and Collagen Distribution

Correlation test was conducted to determine whether there was a correlation between the Expression of TGF- β and collagen distribution variables in radiation dermatitis wound healing.

The results of the data normality test using Sapphiro Wilk showed that the Expression of TGF- β data were normally distributed, namely $p=0.534$ ($p>0.05$), while the collagen distribution data were not normally distributed $p = 0.005$ ($p <0.05$), so the correlation test used was the Spearman correlation test.

Table 6. Spearman correlation test results of TGF- β and collagen distribution

Variable	p	r
TGF- β	<0.001	0.722
Collagen		

The results of the Spearman's rho correlation test showed a value of $p = <0.001$ and $r = 0.722$, from these results, it can be concluded that there was a strong and unidirectional significant correlation between TGF- β to collagen.

Discussion

In this study, the Expression of TGF- β was expressed by cells in wound tissue that were seen on immunohistochemical staining and was measured semiquantitatively using the Allred score to see the proportion per 100 cells stained; and the intensity of staining was calculated per 100 cells/field of view in 5 fields of view with a 400x magnification. After that, the average was calculated. Meanwhile, for collagen distribution in the dermatitis wound tissue, examination was calculated in 5 fields of view with a 400x magnification binocular microscope and Hematoxylin eosin staining.

Ozone is widely recognized as one of the best bactericidal, antiviral and antifungal agents. Ozone's antiseptic properties can help reduce potential pathogens in wounds, thereby suppressing neutrophil counts, stopping inflammation and accelerating wound repair [10-11]. Ozone also causes an increase in the expression of TGF- β , PDGF and VEGF which are known to play a role in the wound healing process, this has been reported in clinical and experimental studies with ozone therapy. TGF- β is one of the growth factors that stimulates angiogenesis, fibroblast proliferation, myofibroblast differentiation, which in turn will increase collagen production thereby accelerating the wound healing process [11-13].

In this study, it was proven that the administration of aloe vera oil with or without ozonation resulted in better healing than the group without therapy and was equivalent to or better than the hydrocortisone group.

a. Radiation Dermatitis

Radiation dermatitis occurs as a result of cutaneous or subcutaneous lesions from exposure to external beam radiation. Radiation reduces neovascularization, fibroblast proliferation, collagen deposition and level of growth factors for wound healing. The inhibited growth factors are transforming growth factor β -1 (TGF β -1) and basic fibroblast growth factor (bFGF) in the acute phase. In the chronic phase of wound healing in radiation scars, TGF β -1 levels increase [4].

In this study, external radiation of 7 Gy gamma rays on the backs of rats of 4 x 4 cm showed a significant effect in causing radiation dermatitis. This is consistent with the results of study by Ran et al, where external gamma ray radiation of 1-8 Gy causes wounds accompanied by exudate, necrotic tissue, or inflammation [14]. The results of this study are supported by a previous study by

Andrade et al, who used animal models to study radiation-induced skin lesions. In this study, skin lesions were induced in Wistar rats by irradiating an electron beam of energy 4 MeV, using a dose rate of 240 cGy/min, for 3 different doses (10 Gy, 40 Gy, and 60 Gy). The skin was observed on days 5, 10, and 25 after exposure to ionizing radiation. The inflammatory infiltrate process was observed on days 5 and 10 for the 40 Gy and 60 Gy groups by assessing the progressive increase in TGF β -1 and the characterization of collagen fibers in the high dose group. The study showed that lesions caused by ionizing radiation in Rats were very similar to radiodermatitis in patients undergoing radiotherapy as was the case with the results of this study [15].

b. Expression of TGF- β

From the results of the study, it was found that giving aloe vera to dermatitis wounds with or without ozonation showed an effect, where the average expression of TGF- β in radiation dermatitis wounds tended to increase significantly compared to the group that did not receive aloe vera.

This study has proven that the administration of ozonated aloe vera oil can increase the expression of TGF- β higher than the positive and negative control groups. The results of this study are supported by previous studies conducted by Atiba et al, and Zhang et al,. This is because during the wound healing process, platelets will produce various growth factors and inflammatory cytokines such as TGF- β , PDGF, EGF and FGF, all of which will appear in the inflammatory phase and some of their functions are chemoactants [4,12,16]. Aloe vera in this study is useful in the wound healing process because of its extract content, namely *acemannan*, *β sitosterol* which activate macrophages in wounds. Besides, the role of ozone is to stimulate TGF- β and other growth factors to the wound area. TGF- β and other growth factors induce the fibroblasts proliferation where the process is affected by oxygen supply [13]. In radiation dermatitis there are pathological changes such as cellular depletion, matrix changes and microvascular damage that cause hypoxia in the wound tissue so that the wound healing process as mentioned above is disrupted [17].

In a previous study by Travagli et al, ozone has the ability to heal wounds, due to its "oxidative killing" effect on organisms. The use of ozone as a therapy provides many benefits because ozone will eliminate pathogens and activate the fibroblasts proliferation by releasing O₂. Furthermore, the formation of intercellular matrix will occur with the keratinofibroblasts proliferation and so, wound healing begins [11].

c. Collagen distribution

The average collagen distribution in the ozonated or non-ozonated group compared to the negative control and hydrocortisone cream 2.5% groups was higher. This study is supported by a previous study conducted by Taqwim Hidayat et al, which showed that the administration of ozonated aloe vera oil had an effect on collagen thickness [14].

This study has proven that the collagen distribution in the group that was given ozonated aloe vera oil was higher than that of the control group. This is because ozone therapy is an alternative therapy that can be used as a disinfectant and can induce strong oxidative stress, thereby stimulating cell and organ protection mechanisms [18]. In ozone therapy, various anti-oxidant systems are activated to defend the body against oxidation and the occurrence of ROS (Reactive Oxygen Species) in the form (O₃, H₂O₂, OH⁺), which leads to the production of antioxidant enzymes. These ROS act as secondary messengers for various immunocytic and non-lymphoid cells involved in the wound repair process and also play important roles in repairing inadequate tissue and coordinating the recruitment of lymphoid cells to the site of injury [8]. Ozonated aloe vera oil increases reactive oxygen species (ROS) and reactive nitrogen species (RNS) around the wound site, such as platelets, macrophages, fibroblasts, endothelial cells and keratinocytes that act as wound healing radicals. Fibroblasts around the wound site will produce collagen so that the wound healing process occurs [17,19, 20]. With the increasing number of fibroblasts, it will increase the production, metabolism of collagen and alters the composition of collagen (more in type III) and increase the degree of collagen cross-linking so that the wound healing process is not disrupted and becomes faster [17, 19].

d. Correlation of TGF- β and collagen distribution on wound healing

The results of this study indicate that there was a strong and unidirectional significant correlation

between the Expression of TGF- β and collagen distribution variables. The content of *acemannan*, β *sitosterol* and glycoproteins in aloe vera will activate macrophages in wounds and the role of ozone will stimulate TGF- β and other growth factors to the wound area. This allows TGF- β and other growth factors to induce the fibroblasts proliferation, which in turn will significantly increase collagen synthesis [13].³⁷ Aloe vera and ozone do not only cause an increase in the collagen content of the wound but also change the composition of collagen (more in type III) and increase the degree of collagen cross-linking. This can accelerate wound contraction and increase the breaking strength of the resulting scar tissue [17,19].

TGF- β will stimulate angiogenesis, fibroblast proliferation, myofibroblast differentiation which in turn will increase collagen production thus accelerating the wound healing process [11-13]. This shows that the occurrence of the collagen production process can increase or decrease depending on the number of growth factors, so that the higher the expression of TGF- β the more collagen is produced and the wound healing process is also faster.

The limitations of this study are related to expensive equipment and costs, so that radiation is only given once. Besides, the immunohistochemical examination is also relatively expensive.

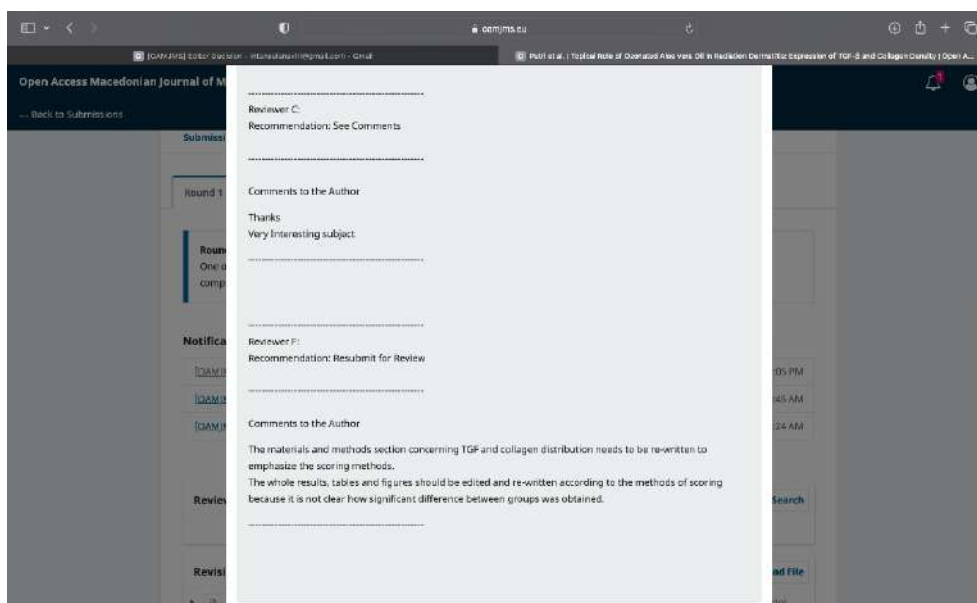
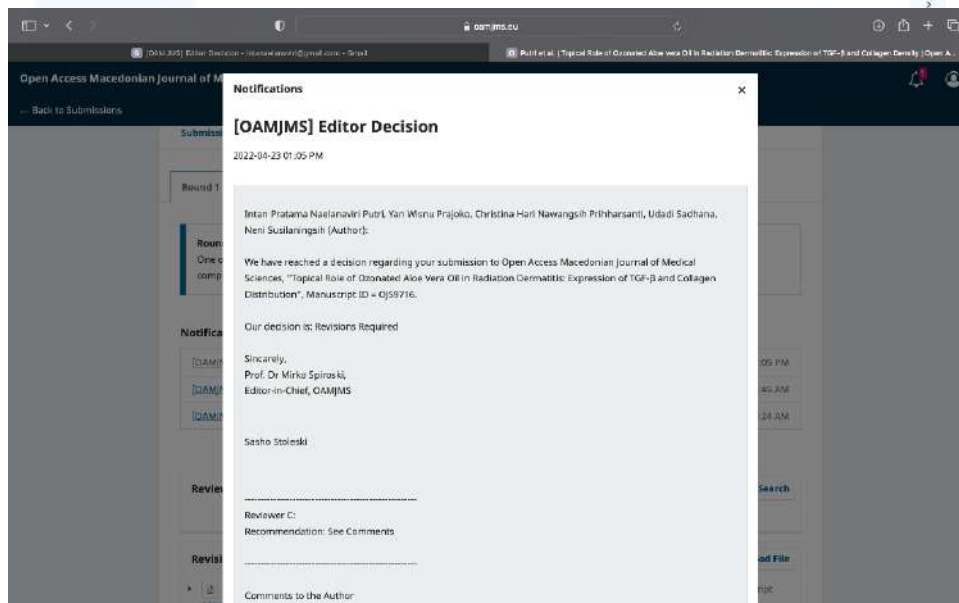
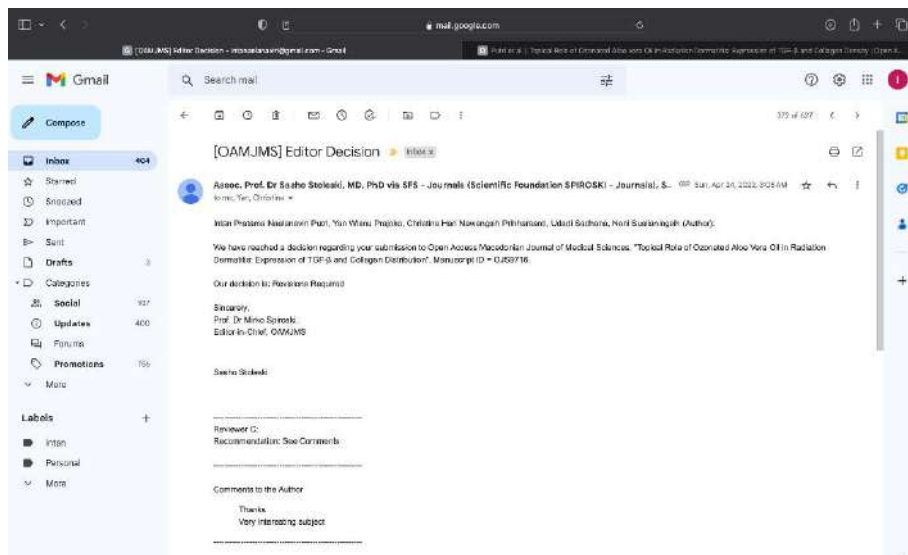
Conclusion

1. There was a significant difference in the expression of TGF- β between the group treated with 300, 600 and 1200 mg/ml ozonated aloe vera and the group that did not receive any therapy (negative control) and the group that received hydrocortisone therapy (positive control).
2. There was a significant difference in the collagen distribution between the group treated with 300, 600 and 1200 mg/ml ozonated aloe vera and the group that did not receive any therapy (negative control) and the group that received hydrocortisone therapy (positive control)
3. There is a significant correlation between the Expression of TGF- β and collagen distribution in healing radiation dermatitis.

References

1. Djuanda A, Hamzah M, Aisah S. *Ilmu Penyakit Kulit Dan Kelamin*. 5th ed. Badan Penerbit Fakultas Kedokteran Universitas Indonesia; 2010.
2. Khanna N, Kumar D, Laskar S, Laskar S. Radiation dermatitis: An overview. *Indian J Burn*. 2013;21(1):24. doi:10.4103/0971-653x.121877
3. Farrugia CJE, Burke ES, Haley ME, Bedi KT, Gandhi MA. The use of aloe vera in cancer radiation: An updated comprehensive review. *Complement Ther Clin Pract*. 2019;35:126-130. doi:10.1016/j.ctcp.2019.01.013
4. Atiba A, Nishimura M, Kakinuma S, et al. Aloe vera oral administration accelerates acute radiation-delayed wound healing by stimulating transforming growth factor- β and fibroblast growth factor production. *Am J Surg*. 2011;201(6):809-818. doi:10.1016/j.amjsurg.2010.06.017
5. Bray FN, Simmons BJ, Wolfson AH, Nouri K. Acute and Chronic Cutaneous Reactions to Ionizing Radiation Therapy. *Dermatol Ther (Heidelb)*. 2016;6(2):185-206. doi:10.1007/s13555-016-0120-y
6. Takzaree, NasrinAbbas, Gholamreza Hassanzadeh, Hadjiakhondi, Mohammad Reza Rouini, Azadeh Manayi MMZ. TGF- β Expression in Aloe Vera Treated Wounds Transforming Growth Factor- β (TGF- β) Activation in Cutaneous Wounds after Topical Application of Aloe Vera Gel Abstract : *Can J Physiol Pharmacol*. Published online 2016:1-22.
7. Kim HS, Noh SU, Han YW, et al. Therapeutic effects of topical application of ozone on acute cutaneous wound healing. *J Korean Med Sci*. 2009;24(3):368-374. doi:10.3346/jkms.2009.24.3.368
8. 11. Campanati A, De Blasio S, Giuliano A, et al. Topical ozonated oil versus hyaluronic gel for the treatment of partial- to full-thickness second-degree burns: A prospective, comparative, single-blind, non-randomised, controlled clinical trial. *Burns*. 2013;39(6):1178-1183. doi:10.1016/j.burns.2013.03.002
9. Cargnello M, Roux PP. Activation and Function of the MAPKs and Their Substrates, the MAPK-Activated Protein Kinases. *Microbiol Mol Biol Rev*. 2011;75(1):50-83. doi:10.1128/mmbr.00031-10
10. Anzolin A, Da Silveira-Kaross N, Bertol C. Ozonated oil in wound healing: What has already been proven? *Med Gas Res*. 2020;10(1):54-59. doi:10.4103/2045-9912.279985
11. Travagli V, Zanardi I, Valacchi G, Bocci V. Ozone and ozonated oils in skin diseases: A review. *Mediators Inflamm*. 2010;2010. doi:10.1155/2010/610418
12. Zhang J, Guan M, Xie C, Luo X, Zhang Q, Xue Y. Increased growth factors play a role in wound healing promoted by noninvasive oxygen-ozone therapy in diabetic patients with foot ulcers. *Oxid Med Cell Longev*. 2014;2014:1-8. doi:10.1155/2014/273475

13. Hashemi SA, Madani SA, Abediankenari S. The review on properties of aloe vera in healing of cutaneous wounds. *Biomed Res Int*. 2015;2015. doi:10.1155/2015/714216
14. Ran X, Cheng T, Shi C, et al. The effects of total-body irradiation on the survival and skin wound healing of rats with combined radiation-wound injury. *J Trauma - Inj Infect Crit Care*. 2004;57(5):1087-1093. doi:10.1097/01.TA.0000141885.72033.C7
15. de Andrade CBV, Ramos IPR, de Moraes ACN, et al. Radiotherapy-induced skin reactions induce fibrosis mediated by TGF- β 1 cytokine. *Dose-Response*. 2017;15(2):1-9. doi:10.1177/1559325817705019
16. Pakyari M, Farrokhi A, Maharlooei MK, Ghahary A. Critical Role of Transforming Growth Factor Beta in Different Phases of Wound Healing. *Adv Wound Care*. 2013;2(5):215-224. doi:10.1089/wound.2012.0406
17. Jacobson LK, Johnson MB, Dedhia RD, Niknam-Bienia S, Wong AK. Impaired wound healing after radiation therapy: A systematic review of pathogenesis and treatment. *JPRAS Open*. 2017;13:92-105. doi:10.1016/j.jptra.2017.04.001
18. Degli Agosti I, Ginelli E, Mazzacane B, et al. Effectiveness of a Short-Term Treatment of Oxygen-Ozone Therapy into Healing in a Posttraumatic Wound. *Case Rep Med*. 2016;2016:1-6. doi:10.1155/2016/9528572
19. Surjushe A, Vasani R, Saple D. Aloe vera: a short review. *Indian J Dermatol*. 2008;53(4):163.
20. Taqwim Hidayat A, Thoah Arifin M, Nur M, Muniroh M, Susilaningsih N. Ozonated Aloe vera Oil Effective Increased the Number of Fibroblasts and Collagen Thickening in the Healing Response of Full-Thickness Skin Defects. *Int J Inflamm*. 2021;2021. doi:10.1155/2021/6654343



oamjms.eu

[OAMJMS] Editor Decision - intanastanavir@gmail.com - Gmail

Putri et al. | Topical Role of Ozonated Aloe vera Oil in Radiation Dermatitis: Expression of TGF- β and Collagen Density | Open A...

Open Access Macedonian Journal of Medical Sciences

— Back to Submissions

Submission Review Copyediting Production

Round 1 Round 2

Round 2 Status
Submission accepted.

Notifications

[OAMJMS] Editor Decision	2022-04-23 01:05 PM
[OAMJMS] Editor Decision	2022-05-10 02:45 AM
[OAMJMS] Editor Decision	2022-06-02 04:24 AM

Reviewer's Attachments [Search](#)

No Files

Revisions [Search](#) [Upload File](#)

No Files

Topical Role of Ozonated Aloe Vera Oil in Radiation Dermatitis: Expression of TGF- β and Collagen density

Abstract

Background: The effect of ozonated aloe vera in the treatment of radiation dermatitis has not been studied, while long-term use of topical steroids can cause some side effects. **Aim:** to analyze the effect of topical administration of ozonated aloe vera oil on the expression of TGF- β and collagen density in the treatment of radiation dermatitis. **Methods:** 36 *Sprague Dawley* rats were randomized into six groups, namely K1 (negative control-without therapy), K2 (positive control-hydrocortisone cream 2.5%), P1 (aloe vera oil), P2, P3, P4 (ozonized aloe vera oil 300/600/1200 mg/ml). Termination and immunohistopathological analysis of TGF- β expression and collagen density were performed after 7 days of treatment. **Results:** Measurement of TGF- β expression by ANNOVA test showed a significant difference between groups $p=0.001$. The Post Hoc LSD test showed a significant differences between groups K1 and P1, P2, P3 and P4 also between groups K2 and P2, P3 and P4. Measurement of collagen density by Kruskal Wallis test showed a significant difference between the treatment groups $p<0.001$. Post Hoc Mann Whitney test of collagen density found a significant difference between groups K1 and P1, P2, P3 and P4 also between groups K2 and P2, P3 and P4. Spearman's rho correlation test showed a strong and unidirectional relationship between TGF- β and collagen ($p < 0.001$ and $r = 0.722$). **Conclusion:** Topical ozonated aloe vera oil increased TGF- β expression and collagen density in radiation dermatitis.

Keywords: ozonated aloe vera oil, TGF- β , collagen density, radiation dermatitis

Introduction

Dermatitis is an inflammatory skin reaction that is sensitive to various endogenous and/or exogenous stimuli, causing clinical abnormalities in the form of polymorphic fluorescence (erythema, edema, papules, vesicles, scales, lichenification) and itching complaints. Polymorphic signals do not always occur simultaneously, maybe even only a few (oligomorphic) [1].

Radiation is one of the causes of dermatitis, often found in patients undergoing radiotherapy. Acute and chronic damage from radiation is a collection of damage to germ cells [2]. Acute side effects (in hours) that appear are in the form of itching, erythema, dryness, cracking and pain ranging from mild to severe [3]. Radiation reduces neovascularization, fibroblast proliferation, collagen deposition and level of growth factors for wound healing. The inhibited growth factors are *transforming growth factor β -1* (TGF β -1) and *basic fibroblast growth factor* (bFGF) in the acute phase, where the inhibition of TGF β -1 will also inhibit other controlled components, namely fibroblast proliferation, transformation into myofibroblasts, stimulation of extracellular matrix production and collagen density [4].

Wound healing is complex processes with cellular and molecular mechanisms. The success of wound healing depends on the inflammatory process, cell proliferation, angiogenesis, wound contraction, epithelialization and matrix remodeling. These processes require the continuous function of neutrophils, macrophages, fibroblasts and endothelial cells to regulate interactions between cells, extracellular matrix proteins and growth factors. Disruption of any of these healing processes will result in abnormal wound healing [4]. Collagen contributes a lot to wound healing. Collagen affects the mechanical strength and elasticity of tissues and acts as a natural substrate for cellular attachment, proliferation and differentiation. Collagen is a key component of the extracellular matrix that plays an important role in the regulation of the wound healing phase whether in its native, fibrillar conformation or as a soluble component in the wound environment [4].

Topical steroids have long been used for the prevention and treatment of radiation-induced toxic dermatitis. There are several studies stating that the use of topical steroids can reduce burning, itching and erythema and slow the progression of the skin. However, long-term use of steroids can cause several local and systemic side effects, thus many studies have been carried out with herbal plants as replacement therapy for topical steroids [5].

Oral and topical administration of aloe vera gel was reported to be effective in wound healing. In a recent study, aloe vera gel or its extract content, namely *acemannan*, *β sitosterol* and others, has been

reported to cause faster wound healing by stimulating fibroblast proliferation, collagen deposition, angiogenesis and growth factor production [4]. In addition, aloe vera also increases TGF- β gene expression which will accelerate the wound healing process [6].

Ozone (O₃) is a much stronger oxidant than oxygen and has the ability to oxidize many substances that are inert to oxygen under normal conditions [7]. Ozone is widely recognized as one of the best bactericidal, antiviral and antifungal agents, which currently are used as therapeutic mediators in wounds to reduce bacterial infection, heal skin damage and increase oxygen tension on exposure [8].

Until now, the effect of ozonated aloe vera in the treatment of radiation dermatitis has not been studied, while long-term use of topical steroids can cause some side effects. This study aimed to compare the expression of TGF- β and collagen density between the topical administration of ozonated aloe vera oil in various doses groups and the control group on the healing of radiation dermatitis in Sprague Dawley rats on day 7 and analyze the effect of topical administration of ozonated aloe vera oil on the expression of TGF- β and collagen density on the healing of radiation dermatitis in Sprague Dawley rats on day 7.

Materials and Methods

Experimental animals

The samples used were 36 adult male Sprague Dawley rats weighing 150 \pm 50 grams and 2-3 months old ; and there were 3 rats that died after receiving radiation, so the number of samples became 33 adult male Sprague Dawley rats. Rats were fed and given water ad libitum and acclitized for 1 weeks before the start of the experiments. Sampels were randomly divided into 6 groups:

K1(negative control): radiation with no treatment

K2(positive control): radiation + hydrocortison cream 2,5%

P1 : radiation + non ozonated aloe vera oil

P2 : radiation + ozonated aloe vera oil 300 mg/ml

P3: radiation + ozonated aloe vera oil 600 mg/ml

P4: radiation + ozonated aloe vera oil 1200 mg/ml

The K1, K2, P1, P2, P3 and P4 groups were terminated on day 7 to be performed with wound tissue taking (sampling), preparations making, as well as histopathological and immunohistochemical staining.

Establishment of the radiation-induced dermatitis rat model

The anesthetic was administered to the rats by an intraperitoneal injection of ketamine-xylazine (ketamine 80 mg/kg, xylazine 10 mg/kg), each rat was placed in a prone position to expose the back area of 4x4 cm before being radiated with a dosage of 7 Gy from a linear accelerator (LINAC). The radiation was done by the accredited radiation oncology facility. The subject was returned to a clean tray/container after radiotherapy, and then it was left until a spontaneous consciousness occurred before topical intervention was applied on the following day. The radiation wound was marked by macular erythema and dry desquamation, grade I dermatitis, based on RTOG/EORTC [9].

Topical treatment applications

Non-ozonated aloe vera oil and ozonated aloe vera oil were obtained from the Center for Plasma Research, Universitas Diponegoro, produced using the method that had been explained in a study conducted by Vahlepi et al [10]. Topical intervention was given 24 hours after radiotherapy, based on the treatment group. The intervention was conducted for 7 consecutive days, given twice a day.

Expression of TGF- β and Collagen Density analysis

TGF- β immunohistochemistry staining was conducted in the Department of Anatomical Pathology, Faculty of Medicine, *Universitas Sebelas Maret*, Solo, and the reading was carried out in the Department of Anatomy, Faculty of Medicine, *Universitas Diponegoro*, Semarang. Euthanasia and tissue excision were performed after giving topical intervention. The tissue excision was carried out on the tissue that was exposed to radiation beams along with less normal skin along the side edge. The tissue was fixated using 10% formalin buffer and cut into 3mm pieces that were then prepared to be paraffin blocks. The paraffin block tissues were cut into 3-micrometer pieces follows by the TGF β antibody staining.

The evaluation of TGF- β expression on the wounds of radiation dermatitis was measured in a semi-quantitative method using the Allred score: proportion score + intensity. The proportion score (A), 0= 0% stained cells; 1=<1% stained cells; 2= 1-10% stained cells; 3=11-33% stained cells; 4=34-66% stained cells, 5: \geq 67% stained cells. The intensity score (B), 0: non-stained, 1: poor intensity, 2: moderate intensity, 3: strong intensity. The proportion score was added by the intensity score, and the final score was 0-8.

The collagen density was evaluated and scored by seeing the percentage of collagen distribution that filled the vision of field in 1 vision of field and was scored, the observation was calculated over 5 visions of field using a binocular microscope with 400x magnification using hematoxylin and eosin (HE) staining. The collagen density score: 1=collagen density on 10% wound area; 2 collagen density on 20% wound area; 3= collagen density on 30% wound area; 4= collagen density on 40% wound area; 5= collagen density on 50% wound area; 6= collagen density on 60% wound area; 7= collagen density on 70% wound area; 8= collagen density on 80% wound area; 9= collagen density on 90% wound area; 10= collagen density on 100% wound area, so the final score was 1-10.

The qualitative evaluation of both TGF-β and collagen density was taken from five visions of field using a binocular microscope with 400x magnification for each sample to obtain the average score. The preparation and the immunohistochemistry analysis were conducted by two accredited pathologists.

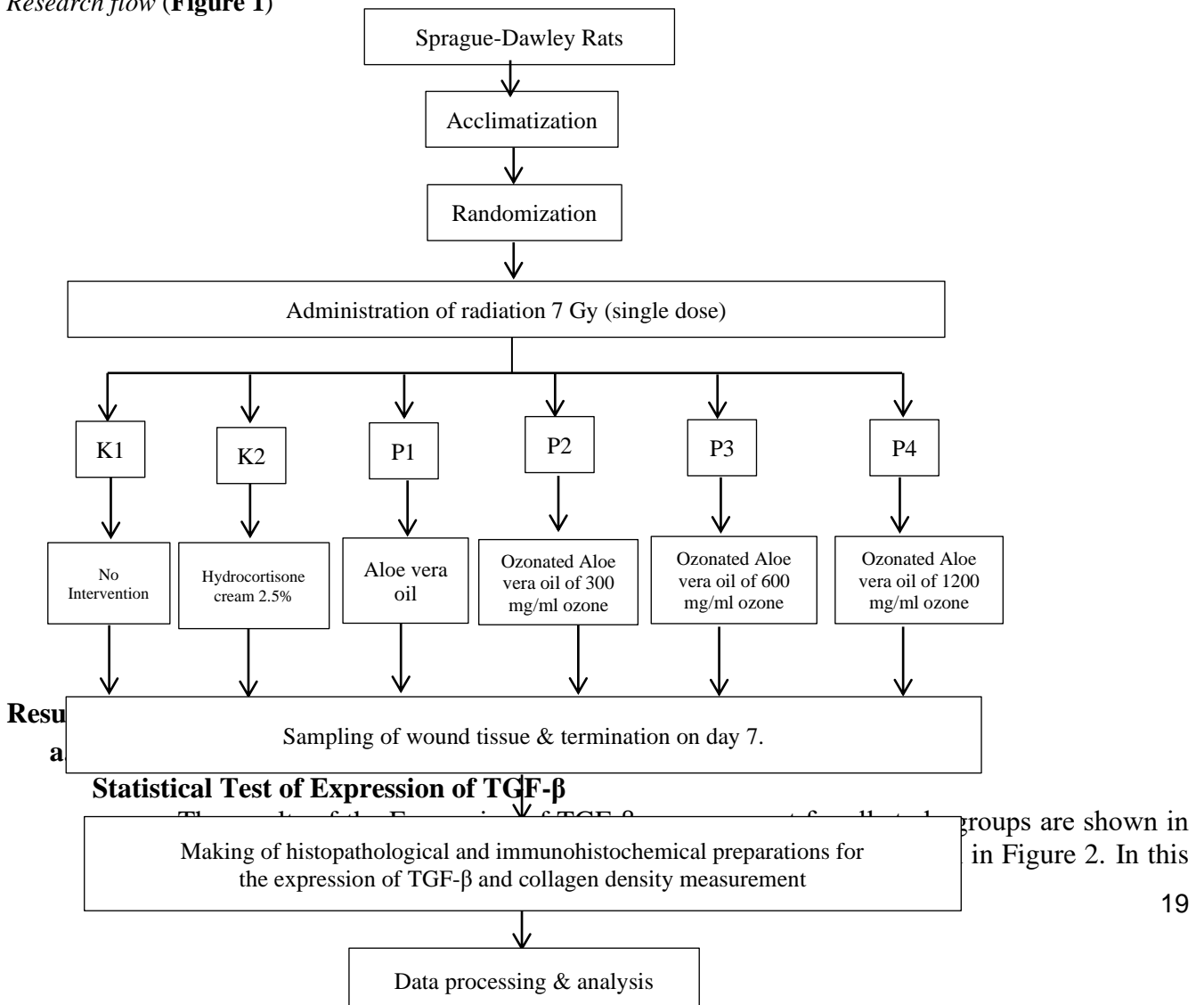
Statistical Analysis

The statistical analysis used the SPSS version 22 (IBM corporation, AS). The testing for the normality of data was conducted using the Shapiro-Wilk test. The TGF-β expression of data was normally distributed, so the One-Way ANOVA testing was conducted and followed by the Post Hoc LSD test after finding a significant difference. The collagen density of data was not normally distributed, so the test was done using the Kruskal-Wallis test and was followed by the Man-Whitney test. The correlation analysis was performed using the Spearman test. The P-value of <0.05 was considered important statistically.

Ethical Approval

All the research subjects used in this study were located and conducted in a certified facility appropriate to the guideline for medical and animal research. The ethical clearance for experimental research using animals was obtained from the ethical committee that regulates the subject (No. 66/EC/H/FK-UNDIP/VII/2021).

Research flow (Figure 1)



study, the normality test was carried out using the Shapiro Wilk test, while the homogeneity test was carried out using the Levene's test. The Shapiro Wilk test is intended to show that the sample come from a normally distributed population, but if the significance obtained is less than 0.05 then the sample data do not come from a normally distributed population. The results of the Shapphiro Wilk test for the Expression of TGF- β showed a significance of $p > 0.05$ in all groups as shown in Table 1 below. This shows that the data were normally distributed.

Table 1. Descriptive and normality test results of the Expression of TGF- β using the Sapphiro – Wilk

Group	Mean \pm SD	median (min – max)	p	Note.
Control	3.60 \pm 0.40	3.6 (3.2 – 4.0)	0.119	N
Hydrocortisone	4.20 \pm 1.02	4.2 (3.0 – 5.4)	0,692	N
Aloe vera	5.00 \pm 0.81	4.8 (4.2 – 6.2)	0.627	N
Ozonated AV 300 mg	5.33 \pm 0.63	5.0 (4.8 – 6.4)	0.054	N
Ozonated AV 600 mg	5.47 \pm 0.78	5.5 (4.2 – 6.4)	0.741	N
Ozonated AV 1200 mg	5.93 \pm 1.17	5.5 (5.0 – 8.0)	0.124	N

Description: N = Normal, Normal ($p > 0.05$)

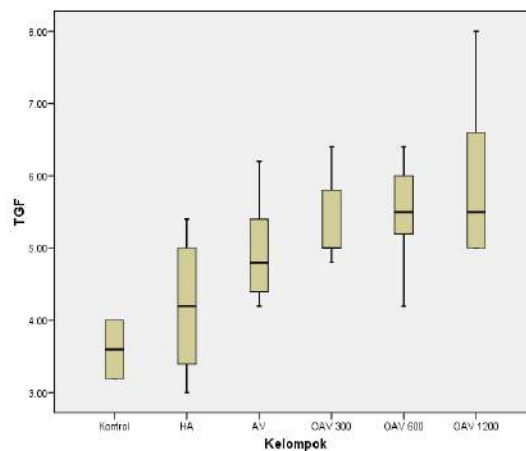


Figure 2. Boxplot Graph of the Expression of TGF- β of Research Samples

After the normality test was carried out, it was continued with the Levene's test to determine the homogeneity of the sample variations. The Levene's test results showed a significance of $p = 0.280$ ($p > 0.05$) indicating that the population variance was homogeneous and the assumptions were met, thus fulfilling the requirements for the ANOVA test.

Table 4. One Way Anova Test Results of the Expression of TGF- β

Group	Mean \pm SD	p	Levene
Control	3.60 \pm 0.40	0.001	0.280
HA	4.20 \pm 1.02		
AV	5.00 \pm 0.81		
Ozonated AV 300 mg	5.33 \pm 0.63		
Ozonated AV 600 mg	5.47 \pm 0.78		
Ozonated AV 1200 mg	5.93 \pm 1.17		

Description: * Significant ($p < 0.05$); ** Homogeneous ($p > 0.05$)

The results of the ANOVA test showed a significance of $p = 0.001$ ($p < 0.05$), meaning that that there was a significant difference in the treatment between groups. To find out which groups were significantly different, a follow-up LSD test was carried out. The results of the LSD test are shown in Table 3.

Table 3. Post hoc LSD Test Results of the Expression of TGF- β

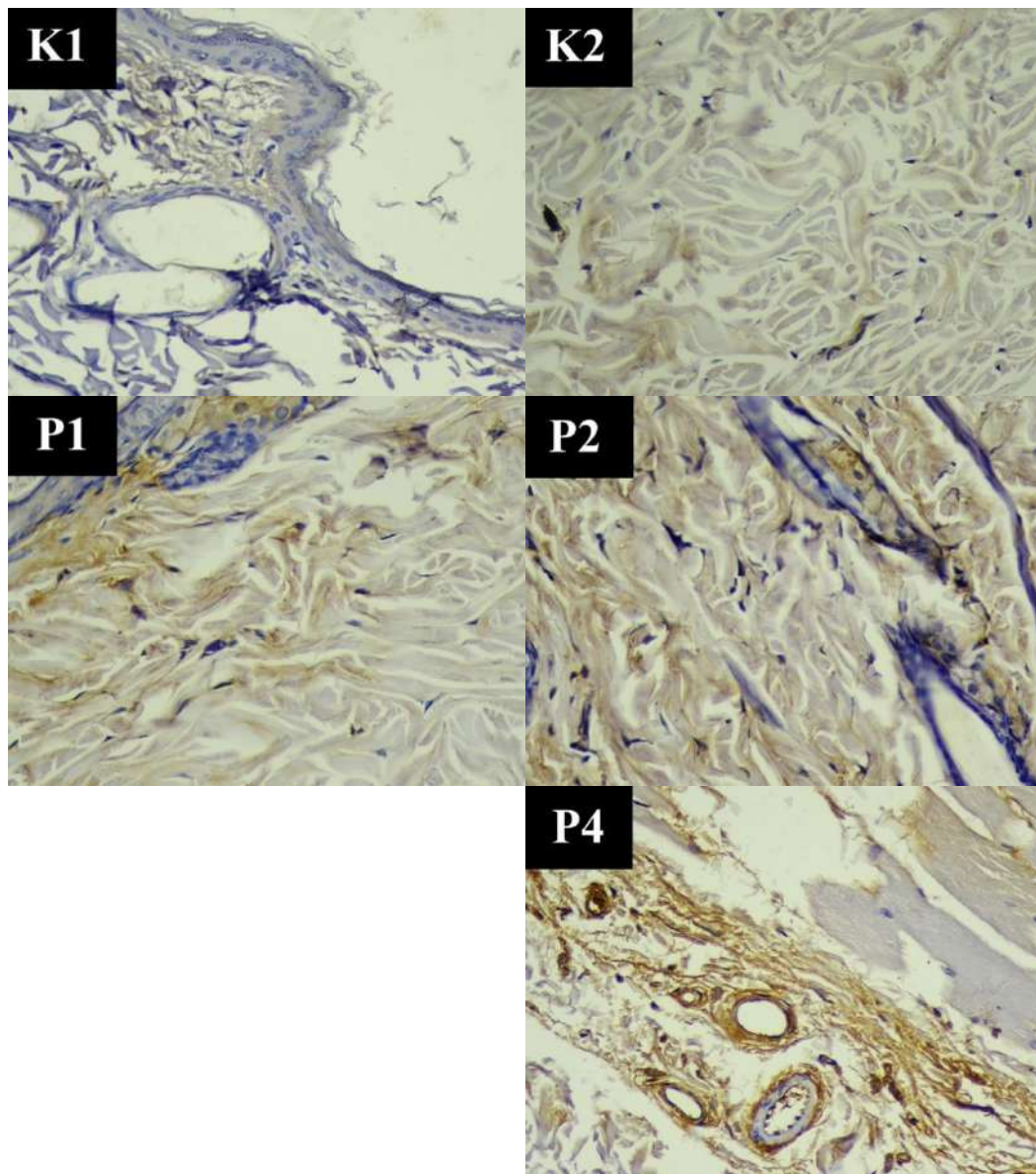
Group		p	Information
I	II		
Control	Hydrocortisone	0.271	Not significant

Group		p	Information
I	II		
	AV	0.014	Significant
	Ozonated AV 300 mg	0.002	Significant
	Ozonated AV 600 mg	0.001	Significant
	Ozonated AV 1200 mg	<0.001	Significant
Hydrocortisone	AV	0.146	Not significant
	Ozonated AV 300 mg	0.035	Significant
	Ozonated AV 600 mg	0.020	Significant
	Ozonated AV 1200 mg	0.002	Significant
AV	Ozonated AV 300 mg	0.520	Not significant
	Ozonated AV 600 mg	0.370	Not significant
	Ozonated AV 1200 mg	0.079	Not significant
Ozonated AV 300 mg	Ozonated AV 600 mg	0.787	Not significant
	Ozonated AV 1200 mg	0.229	Not significant
Ozonated AV 600 mg	Ozonated AV 1200 mg	0.347	Not significant

In the Post Hoc LSD test, there was a significant difference between the control group and the AV, Ozonated AV 300mg, Ozonated AV 600mg and Ozonated 1200 groups, also there was a significant difference between the hydrocortisone group and the Ozonated AV 300mg, Ozonated AV 600mg and Ozonated AV 1200mg groups.

b. Overview of TGF- β Immunohistochemical Examination

Based on immunohistochemical examination of TGF- β from wound tissue cuts in experimental animals in this study, the results were obtained as shown in Figure 3 below.



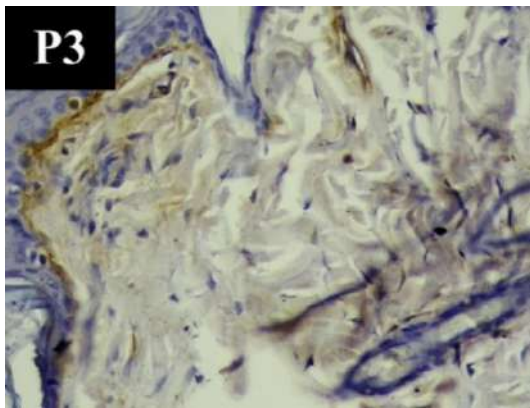


Figure 3. Immunohistochemical description of TGF- β wound tissue. (K1) Without intervention. (K2) Hydrocortisone cream 2.5%. (P1) Aloe vera oil. (P2) Ozonated Aloe vera oil of 300 mg/ml. (P3) Ozonated Aloe vera oil of 600 mg/ml. (P4). Ozonated Aloe vera oil of 1,200 mg/ml.

c. Collagen density

Statistical Test of Collagen density

The results of collagen density measurement for all study groups are shown in Table 4. The average results are also depicted by a boxplot graph as shown in Figure 5. The results of the Shapiro Wilk test for collagen density showed a significance of $p > 0.05$ in all groups except the P4 group ($p = 0.003$) as shown in the following table. This shows that the data were not normally distributed and the ANOVA requirements were not met, so the analysis was continued with the Kruskal-Wallis test.

Table 5. Normality test results of collagen density using the Shappiro-wilk

Group	N	Mean \pm SD	median (min – max)	p	Note.
Control	5	3.92 \pm 0.44	3.8 (3.4 – 4.6)	0.607	N
HA	5	5.44 \pm 0.62	5.6 (4.6 – 6.0)	0.332	N
AV	5	5.72 \pm 0.33	5.8 (5.2 – 6.0)	0.314	N
Ozonated AV 300 mg	6	6.77 \pm 0.27	6.8 (6.4 – 7.0)	0.065	N
Ozonated AV 600 mg	6	7.27 \pm 0.27	7.2 (7.0 – 7.6)	0.093	N
Ozonated AV 1200 mg	6	7.33 \pm 0.24	7.2 (7.2 – 7.8)	0.003	TN

Description: N = Normal, TN = Abnormal, Normal ($p > 0.05$)

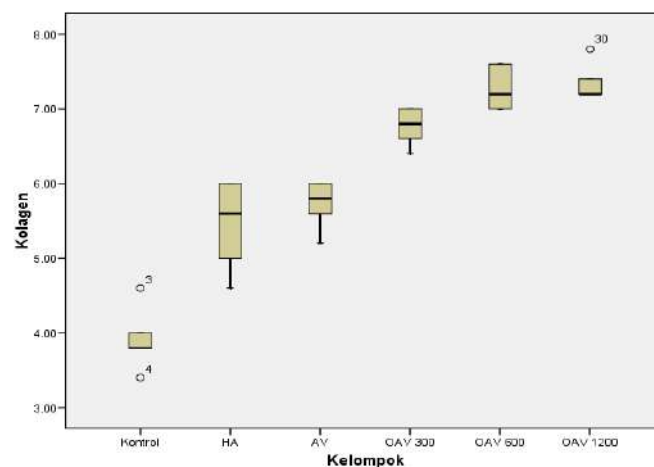


Figure 5. Boxplot Graph of Collagen density of Research Samples

Table 4.6 Kruskal-Wallis test results of Collagen density

Group	Mean ± SD	p
Control	3.92±0.44	<0.001
HA	5.44 ± 0.62	
AV	5.72 ± 0.33	
Ozonated AV 300 mg	6.77±0.27	
Ozonated AV 600 mg	7.27±0.27	
Ozonated AV 1200 mg	7.33±0.24	

The results of the Kruskal-Wallis test showed a significance of $p < 0.001$ ($p < 0.05$), meaning that there was a significant difference in the treatment between groups. To find out which group were significantly different, a follow-up Mann-Whitney test was carried out. The results of the Mann-Whitney test are shown in Table 5.

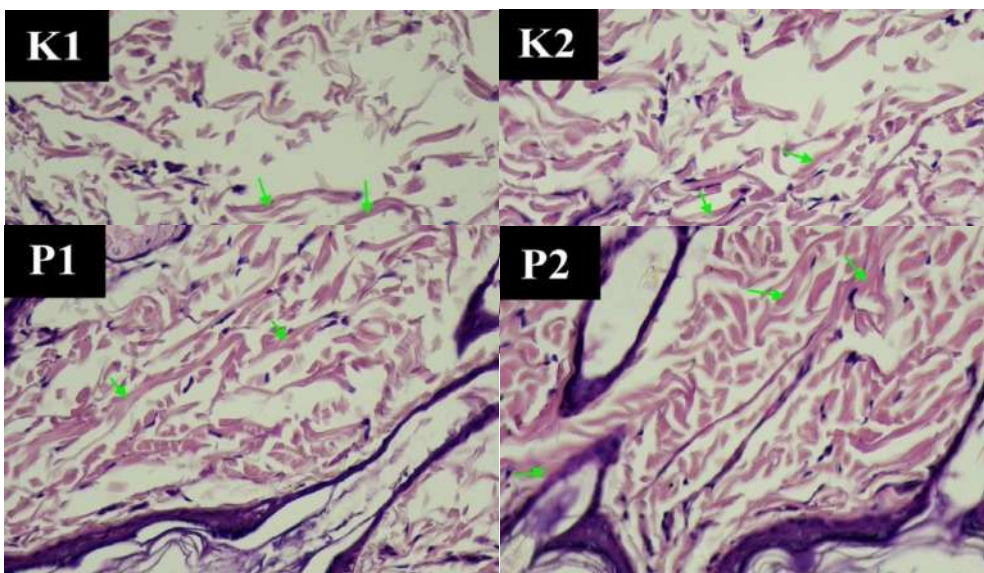
Table 5. Post hoc Mann-Whitney Test Results of Collagen density

Group		p	Information
I	II		
Control	HA	0.011	Significant
	AV	0.009	Significant
	Ozonated AV 300 mg	0.005	Significant
	Ozonated AV 600 mg	0.006	Significant
	Ozonated AV 1200 mg	0.005	Significant
HA	AV	0.517	Not significant
	Ozonated AV 300 mg	0.005	Significant
	Ozonated AV 600 mg	0.006	Significant
	Ozonated AV 1200 mg	0.005	Significant
AV	Ozonated AV 300 mg	0.005	Significant
	Ozonated AV 600 mg	0.006	Significant
	Ozonated AV 1200 mg	0.005	Significant
Ozonated AV 300 mg	Ozonated AV 600 mg	0.012	Significant
	Ozonated AV 1200 mg	0.003	Significant
Ozonated AV 600 mg	Ozonated AV 1200 mg	0.492	Not significant

In the Post Hoc Mann-Whitney test, there was a significant difference between the control group and the Hydrocortisone, AV, Ozonated AV 300mg, Ozonated AV 600mg and Ozonated 1200 groups; between the Hydrocortisone group and the Ozonated AV 300 mg, Ozonated AV 600 mg and Ozonated AV 1200 mg groups; between the AV group and the Ozonated AV 300 mg, Ozonated AV 600 mg and Ozonated AV 1200 mg. Furthermore, the Ozonated AV 300 mg group was significant to the Ozonated AV 600 mg and Ozonated AV 1200 mg groups.

d. Overview of Collagen density Examination

Based on histological examination using H&E staining to assess the collagen density from wound tissue cuts in experimental animals in this study, the results are as shown in Figure 6 below.



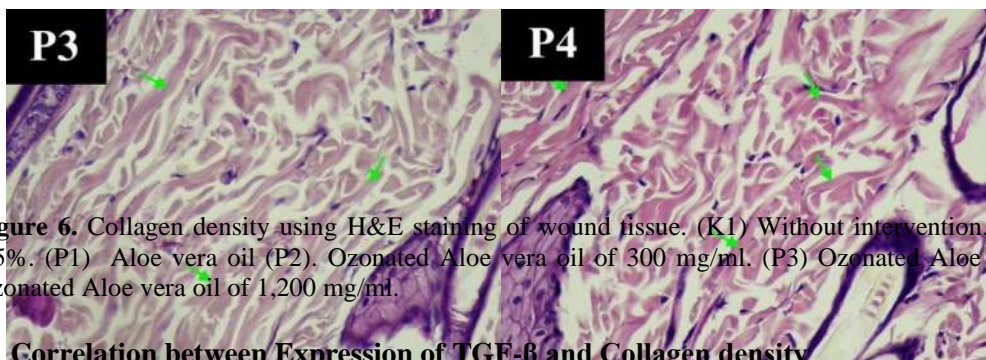


Figure 6. Collagen density using H&E staining of wound tissue. (K1) Without intervention, (K2) Hydrocortisone cream 2.5%. (P1) Aloe vera oil (P2). Ozonated Aloe vera oil of 300 mg/ml. (P3) Ozonated Aloe vera oil of 600 mg/ml. (P4) Ozonated Aloe vera oil of 1,200 mg/ml.

e. **Correlation between Expression of TGF- β and Collagen density**

Correlation test was conducted to determine whether there was a correlation between the Expression of TGF- β and collagen density variables in radiation dermatitis wound healing.

The results of the data normality test using Saphiro Wilk showed that the Expression of TGF- β data were normally distributed, namely $p=0.534$ ($p>0.05$), while the collagen density data were not normally distributed $p = 0.005$ ($p <0.05$), so the correlation test used was the Spearman correlation test.

Table 6. Spearman correlation test results of TGF- β and collagen density

Variable	p	r
TGF- β	<0.001	0.722
Collagen		

The results of the Spearman's rho correlation test showed a value of $p = <0.001$ and $r = 0.722$, from these results, it can be concluded that there was a strong and unidirectional significant correlation between TGF- β to collagen.

Discussion

In this study, the Expression of TGF- β was expressed by cells in wound tissue that were seen on immunohistochemical staining and was measured semiquantitatively using the Allred score to see the proportion per 100 cells stained; and the intensity of staining was calculated per 100 cells/field of view in 5 fields of view with a 400x magnification. After that, the average was calculated. Meanwhile, for collagen density in the dermatitis wound tissue, examination was calculated in 5 fields of view with a 400x magnification binocular microscope and Hematoxylin eosin staining.

Ozone is widely recognized as one of the best bactericidal, antiviral and antifungal agents. Ozone's antiseptic properties can help reduce potential pathogens in wounds, thereby suppressing neutrophil counts, stopping inflammation and accelerating wound repair [12-13]. Ozone also causes an increase in the expression of TGF- β , PDGF and VEGF which are known to play a role in the wound healing process, this has been reported in clinical and experimental studies with ozone therapy. TGF- β is one of the growth factors that stimulates angiogenesis, fibroblast proliferation, myofibroblast differentiation, which in turn will increase collagen production thereby accelerating the wound healing process [13-15].

In this study, it was proven that the administration of aloe vera oil with or without ozonation resulted in better healing than the group without therapy and was equivalent to or better than the hydrocortisone group.

a. Radiation Dermatitis

Radiation dermatitis occurs as a result of cutaneous or subcutaneous lesions from exposure to external beam radiation. Radiation reduces neovascularization, fibroblast proliferation, collagen deposition and level of growth factors for wound healing. The inhibited growth factors are transforming growth factor β -1 (TGF β -1) and basic fibroblast growth factor (bFGF) in the acute phase. In the chronic phase of wound healing in radiation scars, TGF β -1 levels increase [4].

In this study, external radiation of 7 Gy gamma rays on the backs of rats of 4 x 4 cm showed a

significant effect in causing radiation dermatitis. This is consistent with the results of study by Ran et al, where external gamma ray radiation of 1-8 Gy causes wounds accompanied by exudate, necrotic tissue, or inflammation [16]. The results of this study are supported by a previous study by Andrade et al, who used animal models to study radiation-induced skin lesions. In this study, skin lesions were induced in Wistar rats by irradiating an electron beam of energy 4 MeV, using a dose rate of 240 cGy/min, for 3 different doses (10 Gy, 40 Gy, and 60 Gy). The skin was observed on days 5, 10, and 25 after exposure to ionizing radiation. The inflammatory infiltrate process was observed on days 5 and 10 for the 40 Gy and 60 Gy groups by assessing the progressive increase in TGF β -1 and the characterization of collagen fibers in the high dose group. The study showed that lesions caused by ionizing radiation in Rats were very similar to radiodermatitis in patients undergoing radiotherapy as was the case with the results of this study [17].

b. Expression of TGF- β

From the results of the study, it was found that giving aloe vera to dermatitis wounds with or without ozonation showed an effect, where the average expression of TGF- β in radiation dermatitis wounds tended to increase significantly compared to the group that did not receive aloe vera.

This study has proven that the administration of ozonated aloe vera oil can increase the expression of TGF- β higher than the positive and negative control groups. The results of this study are supported by previous studies conducted by Atiba et al, and Zhang et al,. This is because during the wound healing process, platelets will produce various growth factors and inflammatory cytokines such as TGF- β , PDGF, EGF and FGF, all of which will appear in the inflammatory phase and some of their functions are chemoactants [4,14,18]. Aloe vera in this study is useful in the wound healing process because of its extract content, namely *acemannan*, *β sitosterol* which activate macrophages in wounds. Besides, the role of ozone is to stimulate TGF- β and other growth factors to the wound area. TGF- β and other growth factors induce the fibroblasts proliferation where the process is affected by oxygen supply [15]. In radiation dermatitis there are pathological changes such as cellular depletion, matrix changes and microvascular damage that cause hypoxia in the wound tissue so that the wound healing process as mentioned above is disrupted [19].

In a previous study by Travagli et al, ozone has the ability to heal wounds, due to its "oxidative killing" effect on organisms. The use of ozone as a therapy provides many benefits because ozone will eliminate pathogens and activate the fibroblasts proliferation by releasing O₂. Furthermore, the formation of intercellular matrix will occur with the keratinofibroblasts proliferation and so, wound healing begins [13].

c. Collagen density

The average collagen density in the ozonated or non-ozonated group compared to the negative control and hydrocortisone cream 2.5% groups was higher. This study is supported by a previous study conducted by Taqwim Hidayat et al, which showed that the administration of ozonated aloe vera oil had an effect on collagen thickness [16].

This study has proven that the collagen density in the group that was given ozonated aloe vera oil was higher than that of the control group. This is because ozone therapy is an alternative therapy that can be used as a disinfectant and can induce strong oxidative stress, thereby stimulating cell and organ protection mechanisms [20]. In ozone therapy, various anti-oxidant systems are activated to defend the body against oxidation and the occurrence of ROS (Reactive Oxygen Species) in the form (O₃, H₂O₂, OH⁺), which leads to the production of antioxidant enzymes. These ROS act as secondary messengers for various immunocytic and non-lymphoid cells involved in the wound repair process and also play important roles in repairing inadequate tissue and coordinating the recruitment of lymphoid cells to the site of injury [8]. Ozonated aloe vera oil increases reactive oxygen species (ROS) and reactive nitrogen species (RNS) around the wound site, such as platelets, macrophages, fibroblasts, endothelial cells and keratinocytes that act as wound healing radicals. Fibroblasts around the wound site will produce collagen so that the wound healing process occurs [19,21,22]. With the increasing number of fibroblasts, it will increase the production, metabolism of collagen and alters the composition of collagen (more in type III) and increase the degree of collagen cross-linking so that the wound healing process is not disrupted and becomes faster [19, 21].

d. Correlation of TGF- β and collagen density on wound healing

The results of this study indicate that there was a strong and unidirectional significant correlation between the Expression of TGF- β and collagen density variables. The content of *acemannan*, β *sitosterol* and glycoproteins in aloe vera will activate macrophages in wounds and the role of ozone will stimulate TGF- β and other growth factors to the wound area. This allows TGF- β and other growth factors to induce the fibroblasts proliferation, which in turn will significantly increase collagen synthesis [15]. Aloe vera and ozone do not only cause an increase in the collagen content of the wound but also change the composition of collagen (more in type III) and increase the degree of collagen cross-linking. This can accelerate wound contraction and increase the breaking strength of the resulting scar tissue [19,21].

TGF- β will stimulate angiogenesis, fibroblast proliferation, myofibroblast differentiation which in turn will increase collagen production thus accelerating the wound healing process [13-15]. This shows that the occurrence of the collagen production process can increase or decrease depending on the number of growth factors, so that the higher the expression of TGF- β the more collagen is produced and the wound healing process is also faster.

The limitations of this study are related to expensive equipment and costs, so that radiation is only given once. Besides, the immunohistochemical examination is also relatively expensive.

Conclusion

1. There was a significant difference in the expression of TGF- β between the group treated with 300, 600 and 1200 mg/ml ozonated aloe vera and the group that did not receive any therapy (negative control) and the group that received hydrocortisone therapy (positive control).
2. There was a significant difference in the collagen density between the group treated with 300, 600 and 1200 mg/ml ozonated aloe vera and the group that did not receive any therapy (negative control) and the group that received hydrocortisone therapy (positive control)
3. There is a significant correlation between the Expression of TGF- β and collagen density in healing radiation dermatitis.

References

1. Djuanda A, Hamzah M, Aisah S. *Ilmu Penyakit Kulit Dan Kelamin*. 5th ed. Badan Penerbit Fakultas Kedokteran Universitas Indonesia; 2010.
2. Khanna N, Kumar D, Laskar S, Laskar S. Radiation dermatitis: An overview. *Indian J Burn*. 2013;21(1):24. doi:10.4103/0971-653x.121877
3. Farrugia CJE, Burke ES, Haley ME, Bedi KT, Gandhi MA. The use of aloe vera in cancer radiation: An updated comprehensive review. *Complement Ther Clin Pract*. 2019;35:126-130. doi:10.1016/j.ctcp.2019.01.013
4. Atiba A, Nishimura M, Kakinuma S, et al. Aloe vera oral administration accelerates acute radiation-delayed wound healing by stimulating transforming growth factor- β and fibroblast growth factor production. *Am J Surg*. 2011;201(6):809-818. doi:10.1016/j.amjsurg.2010.06.017
5. Bray FN, Simmons BJ, Wolfson AH, Nouri K. Acute and Chronic Cutaneous Reactions to Ionizing Radiation Therapy. *Dermatol Ther (Heidelb)*. 2016;6(2):185-206. doi:10.1007/s13555-016-0120-y
6. Takzaree, NasrinAbbas, Gholamreza Hassanzadeh, Hadjiakhondi, Mohammad Reza Rouini, Azadeh Manayi MMZ. TGF- β Expression in Aloe Vera Treated Wounds Transforming Growth Factor- β (TGF- β) Activation in Cutaneous Wounds after Topical Application of Aloe Vera Gel Abstract : *Can J Physiol Pharmacol*. Published online 2016:1-22.
7. Kim HS, Noh SU, Han YW, et al. Therapeutic effects of topical application of ozone on acute cutaneous wound healing. *J Korean Med Sci*. 2009;24(3):368-374. doi:10.3346/jkms.2009.24.3.368
8. Campanati A, De Blasio S, Giuliano A, et al. Topical ozonated oil versus hyaluronic gel for the treatment of partial- to full-thickness second-degree burns: A prospective, comparative, single-blind, non-randomised, controlled clinical trial. *Burns*. 2013;39(6):1178-1183. doi:10.1016/j.burns.2013.03.002
9. Hymes SR, Strom EA, Fife C. Radiation dermatitis: clinical presentation, pathophysiology, and treatment 2006. *J Am Acad Dermatol*. 2006;54(1):28-46. doi:10.1016/j.jaad.2005.08.054
10. Vahlepi R, Arifin MT, Nur M, Muniroh M, Susilaningsih N. Ozonated aloe vera oil improve wound healing by decreasing neutrophil count and wound diameter in Sprague Dawley rats with full-thickness skin defect. *Indones J Biomed Sci*. 2020;14(2):48. doi:10.15562/ijbs.v14i2.253
11. Cargnello M, Roux PP. Activation and Function of the MAPKs and Their Substrates, the MAPK-Activated Protein Kinases. *Microbiol Mol Biol Rev*. 2011;75(1):50-83. doi:10.1128/mmbr.00031-10

12. Anzolin A, Da Silveira-Kaross N, Bertol C. Ozonated oil in wound healing: What has already been proven? *Med Gas Res*. 2020;10(1):54-59. doi:10.4103/2045-9912.279985
13. Travagli V, Zanardi I, Valacchi G, Bocci V. Ozone and ozonated oils in skin diseases: A review. *Mediators Inflamm*. 2010;2010. doi:10.1155/2010/610418
14. Zhang J, Guan M, Xie C, Luo X, Zhang Q, Xue Y. Increased growth factors play a role in wound healing promoted by noninvasive oxygen-ozone therapy in diabetic patients with foot ulcers. *Oxid Med Cell Longev*. 2014;2014:1-8. doi:10.1155/2014/273475
15. Hashemi SA, Madani SA, Abediankenari S. The review on properties of aloe vera in healing of cutaneous wounds. *Biomed Res Int*. 2015;2015. doi:10.1155/2015/714216
16. Ran X, Cheng T, Shi C, et al. The effects of total-body irradiation on the survival and skin wound healing of rats with combined radiation-wound injury. *J Trauma - Inj Infect Crit Care*. 2004;57(5):1087-1093. doi:10.1097/01.TA.0000141885.72033.C7
17. de Andrade CBV, Ramos IPR, de Moraes ACN, et al. Radiotherapy-induced skin reactions induce fibrosis mediated by TGF- β 1 cytokine. *Dose-Response*. 2017;15(2):1-9. doi:10.1177/1559325817705019
18. Pakyari M, Farrokhi A, Maharlooei MK, Ghahary A. Critical Role of Transforming Growth Factor Beta in Different Phases of Wound Healing. *Adv Wound Care*. 2013;2(5):215-224. doi:10.1089/wound.2012.0406
19. Jacobson LK, Johnson MB, Dedhia RD, Niknam-Bienia S, Wong AK. Impaired wound healing after radiation therapy: A systematic review of pathogenesis and treatment. *JPRAS Open*. 2017;13:92-105. doi:10.1016/j.jptra.2017.04.001
20. Degli Agosti I, Ginelli E, Mazzacane B, et al. Effectiveness of a Short-Term Treatment of Oxygen-Ozone Therapy into Healing in a Posttraumatic Wound. *Case Rep Med*. 2016;2016:1-6. doi:10.1155/2016/9528572
21. Surjushe A, Vasani R, Saple D. Aloe vera: a short review. *Indian J Dermatol*. 2008;53(4):163.
22. Taqwim Hidayat A, Thohar Arifin M, Nur M, Muniroh M, Susilaningsih N. Ozonated Aloe vera Oil Effective Increased the Number of Fibroblasts and Collagen Thickening in the Healing Response of Full-Thickness Skin Defects. *Int J Inflamm*. 2021;2021. doi:10.1155/2021/6654343

mail.google.com

[OAMJMS] Editor Decision - Intanaelanaviri@gmail.com - Gmail

Putri et al. | Topical Role of Ozonated Aloe vera Oil in Radiation Dermatitis: Expression of TGF- β and Collagen Density | Open A...

Gmail

Compose

Inbox 404

Starred

Snoozed

Important

Sent

Drafts 3

Categories

Social 937

Updates 400

Forums

Promotions 786

More

Labels +

intan

Personal

More

Search mail

360 of 627

[OAMJMS] Editor Decision inbox x

Katerina Spiroska via SFS - Journals (Scientific Foundation SPIROSKI - Journals), Skopje, Republic of Maced...
to me, Yan, Christina

Tue, May 10, 2022, 4:45 PM

Intan Pratama Naelanaviri Putri, Yan Wisnu Prajoko, Christina Hari Nawangsih Priharsanti, Udadi Sadhana, Neni Suslianingsih (Author):

We have reached a decision regarding your submission to Open Access Macedonian Journal of Medical Sciences, "Topical Role of Ozonated Aloe Vera Oil in Radiation Dermatitis: Expression of TGF- β and Collagen Distribution", Manuscript ID = OJS9716.

Our decision is to: Accept your revised manuscript for publication in OAMJMS.

Reviewer A:
Recommendation: Accept Submission

Comments to the Author

Nice work

Reply Reply all Forward

mail.google.com

[OAMJMS] Your Article was Published - Intanaelaviri...
Putri et al. | Topical Role of Ozonated Aloe vera Oil in R...
Putri et al. | Topical Role of Ozonated Aloe vera Oil in R...
Putri et al. | Topical Role of Ozonated Aloe vera Oil in R...

Gmail

Compose

Inbox 404

Starred

Snoozed

Important

Sent

Drafts 3

Categories

Social 937

Updates 400

Forums

Promotions 786

More

Labels +

intan

Personal

More

Search mail

319 of 627

[OAMJMS] Your Article was Published

MSc, Eng Ivo Spiroski via SFS - Journals (Scientific Foundation SPIROSKI - Journals), Skopje, Republic of Mac... Mon, Jul 11, 2022, 4:30 AM

Dear Intan Pratama Naelanaviri Putri,

Please note that your paper "Topical Role of Ozonated Aloe vera Oil in Radiation Dermatitis: Expression of TGF- β and Collagen Density", was published in Open Access Maced J Med Sci (OAMJMS).

DOI: <https://doi.org/10.3889/oamjms.2022.9716>

Username: Intan Pratama Naelanaviri Putri

Thank you for your fine contribution. On behalf of the Editors of the Open Access Macedonian Journal of Medical Sciences, we look forward to your continued contributions to the Journal.

Cordially,
Prof. Dr Mirko Spiroski,
Editor-in-Chief

MSc Ivo Spiroski, Engineer of Interior Design, ID Design 2012, Skopje Naroden Front 13/45, 1000 Skopje, Republic of Macedonia

Reply Forward

oamjms.eu

[OAMJMS] Editor Decision - intanaelanaviri@gmail.com - Gmail

Putri et al. | Topical Role of Ozonated Aloe vera Oil in Radiation Dermatitis: Expression of TGF-β and Collagen Density | Open A...

Open Access Macedonian Journal of Medical Sciences

Back to Submissions

9716 / Putri

Workflow

Submission

Production

Number

[OAMJMS]

[OAMJMS]

[OAMJMS] Your Article was Published

Participants

MSc, Eng Ivo Spiroski (ivos)
Intan Pratama Naelanaviri Putri (intan99)

Messages

Note	From
Dear Intan Pratama Naelanaviri Putri,	ivos 2022-07-10 02:30 PM
Please note that your paper "Topical Role of Ozonated Aloe vera Oil in Radiation Dermatitis: Expression of TGF-β and Collagen Density", was published in Open Access Maced J Med Sci (OAMJMS). DOI: https://doi.org/10.3889/oamjms.2022.9716 Username: Intan Pratama Naelanaviri Putri	
Thank you for your fine contribution. On behalf of the Editors of the Open Access Macedonian Journal of Medical Sciences, we look forward to your continued contributions to the Journal.	
Cordially, Prof. Dr Mirko Spiroski, Editor-in-Chief	
MSc Ivo Spiroski, Engineer of Interior Design, ID Design 2012, Skopje Naroden Front 13/45, 1000 Skopje, Republic of Macedonia	

oamjms.eu

Inbox (404) - intanaelanaviri@gmail.com... Putri et al. | Topical Role of Ozonated Alo... Putri et al. | Topical Role of Ozonated Alo... Putri et al. | Topical Role of Ozonated Alo... Topical Role of Ozonated Aloe vera Oil in...

Open Access Macedonian Journal of Medical Sciences

About - Announcements - Metrics - Current - Archives - EU - Scopus - NCBI - CABI - Indexation - Search

Membership

Home / Archives / Vol. 10 No. E (2022): E - Public Health / Public Health Epidemiology

Topical Role of Ozonated Aloe vera Oil in Radiation Dermatitis: Expression of TGF-β and Collagen Density

Intan Pratama Naelanaviri Putri
Department of Biomedical Science, Faculty of Medicine, Universitas Diponegoro, Semarang, Indonesia


Yan Wisnu Prajoko
Department of Biomedical Science, Faculty of Medicine, Universitas Diponegoro, Semarang, Indonesia; Department of Surgical Oncology, Faculty of Medicine, Universitas Diponegoro, Dr. Kariadi General Hospital, Semarang, Indonesia

Christina Hari Nawangsih Priharsanti
Department of Biomedical Science, Faculty of Medicine, Universitas Diponegoro, Semarang, Indonesia; Department of Radiology, Faculty of Medicine, Universitas Diponegoro, Dr. Kariadi General Hospital, Semarang, Indonesia

Udadi Sadhana
Department of Biomedical Science, Faculty of Medicine, Universitas Diponegoro, Semarang, Indonesia; Department of Anatomical Pathology, Faculty of Medicine, Universitas Diponegoro, Semarang, Indonesia

Neni Susilaningih
Department of Biomedical Science, Faculty of Medicine, Universitas Diponegoro, Semarang, Indonesia; Department of Histology, Faculty of Medicine, Universitas Diponegoro, Semarang, Indonesia

DOI: <https://doi.org/10.3889/oamjms.2022.9716>



PDF

Published
2022-06-02

How to Cite
Putri IPN, Prajoko YW, Priharsanti CHN, Sadhana U, Susilaningih N. Topical Role of Ozonated Aloe vera Oil in Radiation Dermatitis: Expression of TGF-β and Collagen Density. Open Access Maced J Med Sci [Internet]. 2022 Jun. 2 [cited 2023 May

Make a Submission

Submit your manuscript - Free of Charge

You can submit your manuscript in our Open Access Journals **free of charge**:

- South East European Journal of Architecture and Design (SEEJAD)
- South East European Journal of Cardiology (SEEJCA)
- South East European Journal of Immunology (SEEJIM)
- South East European Journal of Human Genetics (SEEJHG)

Browse

Categories

- A - Basic Sciences



Topical Role of Ozonated *Aloe vera* Oil in Radiation Dermatitis: Expression of TGF- β and Collagen Density

Intan Pratama Naelanaviri Putri¹, Yan Wisnu Prajoko^{1,2*}, Christina Hari Nawangsih Priharsanti^{1,3}, Udadi Sadhana^{1,4}, Neni Susilaningih^{1,5}

¹Department of Biomedical Science, Faculty of Medicine, Universitas Diponegoro, Semarang, Indonesia; ²Department of Surgical Oncology, Faculty of Medicine, Universitas Diponegoro, Dr. Kariadi General Hospital, Semarang, Indonesia; ³Department of Radiology, Faculty of Medicine, Universitas Diponegoro, Dr. Kariadi General Hospital, Semarang, Indonesia; ⁴Department of Anatomical Pathology, Faculty of Medicine, Universitas Diponegoro, Semarang, Indonesia; ⁵Department of Histology, Faculty of Medicine, Universitas Diponegoro, Semarang, Indonesia

Abstract

BACKGROUND: The effect of ozonated *Aloe vera* in the treatment of radiation dermatitis has not been studied, while long-term use of topical steroids can cause some side effects.

AIM: The aim of the study was to analyze the effect of topical administration of ozonated *Aloe vera* oil on the expression of TGF- β and collagen density in the treatment of radiation dermatitis.

METHODS: 36 Sprague Dawley rats were randomized into six groups, namely, K1 (negative control-without therapy), K2 (positive control-hydrocortisone cream 2.5%), P1 (*Aloe vera* oil), P2, P3, and P4 (ozonized *Aloe vera* oil 300/600/1200 mg/ml). Termination and immunohistopathological analysis of TGF- β expression and collagen density were performed after 7 days of treatment.

RESULTS: Measurement of TGF- β expression by ANNOVA test showed a significant difference between groups $p = 0.001$. The *Post Hoc* LSD test showed significant differences between groups K1 and P1, P2, P3, and P4 also between groups K2 and P2, P3, and P4. Measurement of collagen density by Kruskal-Wallis test showed a significant difference between the treatment groups $p < 0.001$. *Post hoc* Mann-Whitney test of collagen density found a significant difference between groups K1 and P1, P2, P3, and P4 also between groups K2 and P2, P3, and P4. Spearman's rho correlation test showed a strong and unidirectional relationship between TGF- β and collagen ($p < 0.001$ and $r = 0.722$).

CONCLUSION: Topical ozonated *Aloe vera* oil increased TGF- β expression and collagen density in radiation dermatitis.

Edited by: Sasho Stoleski
Citation: Putri IPN, Prajoko YW, Priharsanti CHN, Sadhana U, Susilaningih N. Topical Role of Ozonated *Aloe vera* Oil in Radiation Dermatitis: Expression of TGF- β and Collagen Density. Open Access Maced J Med Sci. 2022 Jun 02; 10(E):1004-1011. <https://doi.org/10.3889/oamjms.2022.9716>
Keywords: Ozonated *Aloe vera* oil; TGF- β ; Collagen density; Radiation dermatitis
***Correspondence:** Yan Wisnu Prajoko, Jalan Dokter Sutomo No. 16, Kota Semarang, Jawa Tengah, Indonesia. E-mail: yanprajoko7519@gmail.com
Received: 08-Apr-2022
Revised: 10-May-2022
Accepted: 22-May-2022
Copyright: © 2022 Intan Pratama Naelanaviri Putri, Yan Wisnu Prajoko, Christina Hari Nawangsih Priharsanti, Udadi Sadhana, Neni Susilaningih
Funding: This research did not receive any financial support
Competing Interests: The authors have declared that no competing interests exist
Open Access: This is an open-access article distributed under the terms of the Creative Commons Attribution-NonCommercial 4.0 International License (CC BY-NC 4.0)

Introduction

Dermatitis is an inflammatory skin reaction that is sensitive to various endogenous and/or exogenous stimuli, causing clinical abnormalities in the form of polymorphic fluorescence (erythema, edema, papules, vesicles, scales, and lichenification) and itching complaints. Polymorphic signals do not always occur simultaneously, maybe even only a few (oligomorphic) [1].

Radiation is one of the causes of dermatitis, often found in patients undergoing radiotherapy. Acute and chronic damage from radiation is a collection of damage to germ cells [2]. Acute side effects (in hours) that appear are in the form of itching, erythema, dryness, cracking, and pain ranging from mild to severe [3]. Radiation reduces neovascularization, fibroblast proliferation, collagen deposition, and level of growth factors for wound healing. The inhibited growth factors are transforming growth factor β -1 (TGF β -1) and basic

fibroblast growth factor (bFGF) in the acute phase, where the inhibition of TGF β -1 will also inhibit other controlled components, namely, fibroblast proliferation, transformation into myofibroblasts, stimulation of extracellular matrix production, and collagen density [4].

Wound healing is complex processes with cellular and molecular mechanisms. The success of wound healing depends on the inflammatory process, cell proliferation, angiogenesis, wound contraction, epithelialization, and matrix remodeling. These processes require the continuous function of neutrophils, macrophages, fibroblasts, and endothelial cells to regulate interactions between cells, extracellular matrix proteins, and growth factors. Disruption of any of these healing processes will result in abnormal wound healing [4]. Collagen contributes a lot to wound healing. Collagen affects the mechanical strength and elasticity of tissues and acts as a natural substrate for cellular attachment, proliferation and differentiation. Collagen is a key component of the extracellular matrix that plays an important role in the regulation of the wound healing

phase whether in its native, fibrillar conformation, or as a soluble component in the wound environment [4].

Topical steroids have long been used for the prevention and treatment of radiation-induced toxic dermatitis. There are several studies stating that the use of topical steroids can reduce burning, itching and erythema and slow the progression of the skin. However, long-term use of steroids can cause several local and systemic side effects, thus many studies have been carried out with herbal plants as replacement therapy for topical steroids [5].

Oral and topical administration of *Aloe vera* gel was reported to be effective in wound healing. In a recent study, *Aloe vera* gel or its extract content, namely, *acemannan*, β *sitosterol* and others, has been reported to cause faster wound healing by stimulating fibroblast proliferation, collagen deposition, angiogenesis, and growth factor production [4]. In addition, *Aloe vera* also increases TGF- β gene expression which will accelerate the wound healing process [6].

Ozone (O₃) is a much stronger oxidant than oxygen and has the ability to oxidize many substances that are inert to oxygen under normal conditions [7]. Ozone is widely recognized as one of the best bactericidal, antiviral, and antifungal agents, which currently are used as therapeutic mediators in wounds to reduce bacterial infection, heal skin damage, and increase oxygen tension on exposure [8].

Until now, the effect of ozonated *Aloe vera* in the treatment of radiation dermatitis has not been studied, while long-term use of topical steroids can cause some side effects. This study aimed to compare the expression of TGF- β and collagen density between the topical administration of ozonated *Aloe vera* oil in various doses groups and the control group on the healing of radiation dermatitis in Sprague–Dawley rats on day 7 and analyze the effect of topical administration of ozonated *Aloe vera* oil on the expression of TGF- β and collagen density on the healing of radiation dermatitis in Sprague–Dawley rats on day 7.

Materials and Methods

Experimental animals

The samples used were 36 adult male Sprague–Dawley rats weighing 150 ± 50 g and 2–3 months old; and there were three rats that died after receiving radiation, so the number of samples became 33 adult male Sprague–Dawley rats. Rats were fed and given water *ad libitum* and acclimatized for 1 weeks before the start of the experiments. Samples were randomly divided into six groups:

K1 (Negative control): radiation with no treatment

K2 (Positive control): radiation + hydrocortisone cream 2.5%

P1: Radiation + non ozonated *Aloe vera* oil

P2: Radiation + ozonated *Aloe vera* oil 300 mg/ml

P3: Radiation + ozonated *Aloe vera* oil 600 mg/ml

P4: Radiation + ozonated *Aloe vera* oil 1200 mg/ml.

The K1, K2, P1, P2, P3, and P4 groups were terminated on day 7 to be performed with wound tissue taking (sampling), preparations making, as well as histopathological, and immunohistochemical staining.

Establishment of the radiation-induced dermatitis rat model

The anesthetic was administered to the rats by an intraperitoneal injection of ketamine-xylazine (ketamine 80 mg/kg and xylazine 10 mg/kg), each rat was placed in a prone position to expose the back area of 4×4 cm before being radiated with a dosage of 7 Gy from a linear accelerator (LINAC). The radiation was done by the accredited radiation oncology facility. The subject was returned to a clean tray/container after radiotherapy, and then it was left until a spontaneous consciousness occurred before topical intervention was applied on the following day. The radiation wound was marked by macular erythema and dry desquamation, Grade I dermatitis, based on RTOG/EORTC [9].

Topical treatment applications

Non-ozonated *Aloe vera* oil and ozonated *Aloe vera* oil were obtained from the Center for Plasma Research, Universitas Diponegoro, produced using the method that had been explained in a study conducted by Vahlepi *et al.* [10]. Topical intervention was given 24 hours after radiotherapy, based on the treatment group. The intervention was conducted for 7 consecutive days, given twice a day.

Expression of TGF- β and collagen density analysis

TGF- β immunohistochemistry staining was conducted in the Department of Anatomical Pathology, Faculty of Medicine, *Universitas Sebelas Maret*, Solo, and the reading was carried out in the Department of Anatomy, Faculty of Medicine, *Universitas Diponegoro*, Semarang. Euthanasia and tissue excision were performed after giving topical intervention. The tissue excision was carried out on the tissue that was exposed to radiation beams along with less normal skin along the side edge. The tissue was fixated using 10% formalin buffer and cut into 3 mm pieces that were then prepared to be paraffin blocks. The paraffin block tissues were cut into 3- μ m pieces follows by the TGF β antibody staining.

The evaluation of TGF- β expression on the wounds of radiation dermatitis was measured in a semi-quantitative method using the Allred score: proportion score + intensity. The proportion score (A), 0 = 0% stained cells; 1 = <1% stained cells; 2 = 1–10% stained cells; 3 = 11–33% stained cells; 4 = 34–66% stained cells, and 5: \geq 67% stained cells. The intensity score (B), 0: non-stained, 1: poor intensity, 2: moderate intensity, and 3: strong intensity. The proportion score was added by the intensity score and the final score was 0–8.

The collagen density was evaluated and scored by seeing the percentage of collagen distribution that filled the vision of field in 1 vision of field and was scored, the observation was calculated over 5 visions of field using a binocular microscope with 400x magnification using hematoxylin and eosin (HE) staining. The collagen density score: 1 = collagen density on 10% wound area; 2 collagen density on 20% wound area; 3 = collagen density on 30% wound area; 4 = collagen density on 40% wound area; 5 = collagen density on 50% wound area; 6 = collagen density on 60% wound area; 7 = collagen density on 70% wound area; 8 = collagen density on 80% wound area; 9 = collagen density on 90% wound area; 10 = collagen density on 100% wound area, so the final score was 1–10.

The qualitative evaluation of both TGF- β and collagen density was taken from five visions of field using a binocular microscope with 400 \times magnification for each sample to obtain the average score. The preparation and the immunohistochemistry analysis were conducted by two accredited pathologists.

Statistical analysis

The statistical analysis used the SPSS version 22 (IBM corporation, AS). The testing for the normality of data was conducted using the Shapiro–Wilk test. The TGF- β expression of data was normally distributed, so the One-Way ANOVA testing was conducted and followed by the *post hoc* LSD test after finding a significant difference. The collagen density of data was not normally distributed, so the test was done using the Kruskal–Wallis test and was followed by the Mann–Whitney test. The correlation analysis was performed using the Spearman test. $p < 0.05$ was considered important statistically.

Ethical approval

All the research subjects used in this study were located and conducted in a certified facility appropriate to the guideline for medical and animal research. The ethical clearance for experimental research using animals was obtained from the ethical committee that regulates the subject (No. 66/EC/H/ FK-UNDIP/VII/2021) (Figure 1).

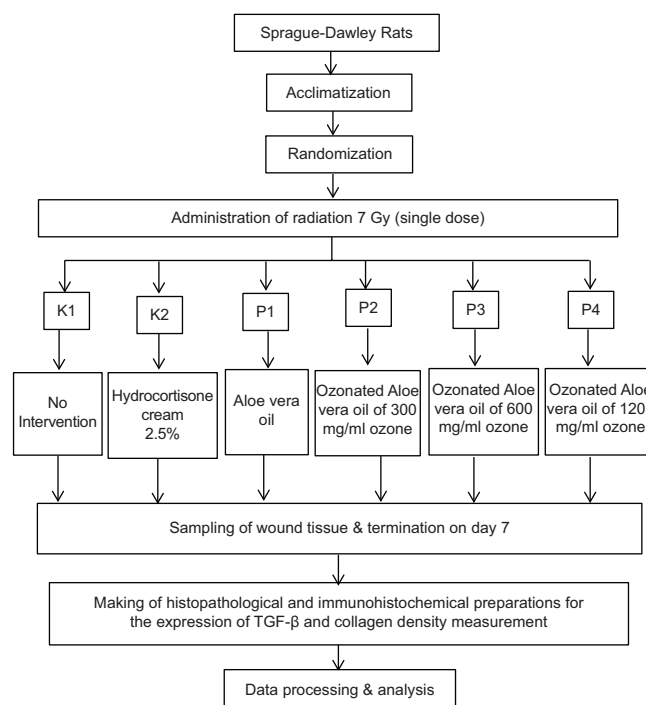


Figure 1: Research flow

Results

Expression of TGF- β

Statistical test of expression of TGF- β

The results of the expression of TGF- β measurement for all study groups are shown in Table 1. The average results are also depicted by a boxplot graph as shown in Figure 2. In this study, the normality test was carried out using the Shapiro–Wilk test, while the homogeneity test was carried out using the Levene’s test. The Shapiro–Wilk test is intended to show that the sample come from a normally distributed population, but if the significance obtained is < 0.05 then the sample data do not come from a normally distributed population. The results of the Shapiro–Wilk test for the expression of TGF- β showed a significance of $p > 0.05$ in all groups as shown in Table 1. This shows that the data were normally distributed.

Table 1: Descriptive and normality test results of the Expression of TGF- β using the Shapiro–Wilk

Group	Mean \pm SD	Median (min–max)	p	Note
Control	3.60 \pm 0.40	3.6 (3.2–4.0)	0.119	N
Hydrocortisone	4.20 \pm 1.02	4.2 (3.0–5.4)	0.692	N
Aloe vera	5.00 \pm 0.81	4.8 (4.2–6.2)	0.627	N
Ozonated AV 300 mg	5.33 \pm 0.63	5.0 (4.8–6.4)	0.054	N
Ozonated AV 600 mg	5.47 \pm 0.78	5.5 (4.2–6.4)	0.741	N
Ozonated AV 1200 mg	5.93 \pm 1.17	5.5 (5.0–8.0)	0.124	N

Description: N: Normal, Normal ($p > 0.05$).

After the normality test was carried out, it was continued with the Levene’s test to determine the homogeneity of the sample variations. The Levene’s test results showed a significance of $p = 0.280$ ($p > 0.05$) indicating that the population variance was homogeneous and the assumptions were met, thus fulfilling the requirements for the ANOVA test (Table 2).

Table 2: One-way ANOVA test results of the expression of TGF-β

Group	Mean ± SD	p	Levene
Control	3.60 ± 0.40	0.001	0.280
HA	4.20 ± 1.02		
AV	5.00 ± 0.81		
Ozonated AV 300 mg	5.33 ± 0.63		
Ozonated AV 600 mg	5.47 ± 0.78		
Ozonated AV 1200 mg	5.93 ± 1.17		

Description: *Significant ($p < 0.05$); **Homogeneous ($p > 0.05$)

The results of the ANOVA test showed a significance of $p = 0.001$ ($p < 0.05$), meaning that there was a significant difference in the treatment between groups. To find out which groups were significantly different, a follow-up LSD test was carried out. The results of the LSD test are shown in Table 3.

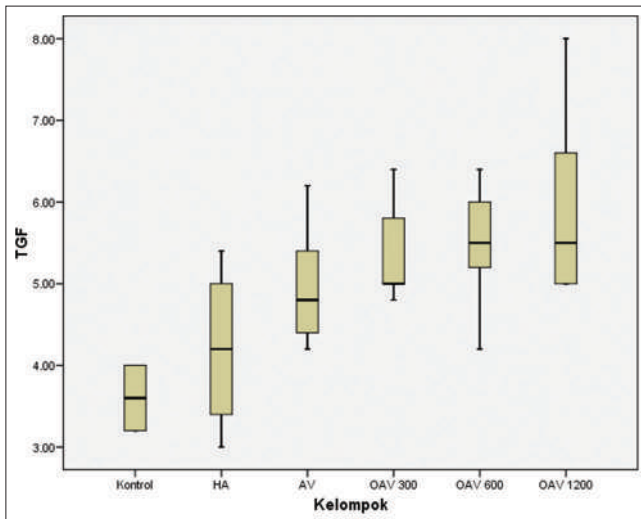


Figure 2: Boxplot graph of the expression of TGF-β of research samples

In the *post hoc* LSD test, there was a significant difference between the control group and the AV, Ozonated AV 300 mg, Ozonated AV 600 mg, and Ozonated 1200 groups; also there was a significant difference between the hydrocortisone group and the Ozonated AV 300 mg, Ozonated AV 600 mg, and Ozonated AV 1200 mg groups.

Overview of TGF-β immunohistochemical examination

Based on immunohistochemical examination of TGF-β from wound tissue cuts in experimental animals in this study, the results are shown in Figure 3.

Collagen density

Statistical test of collagen density

The results of collagen density measurement for all study groups are shown in Table 4 and 4a. The average results are also depicted by a boxplot graph as shown in Figure 4. The results of the Shapiro–Wilk test for collagen density showed a significance of $p > 0.05$ in all groups except the P4 group ($p = 0.003$) as shown

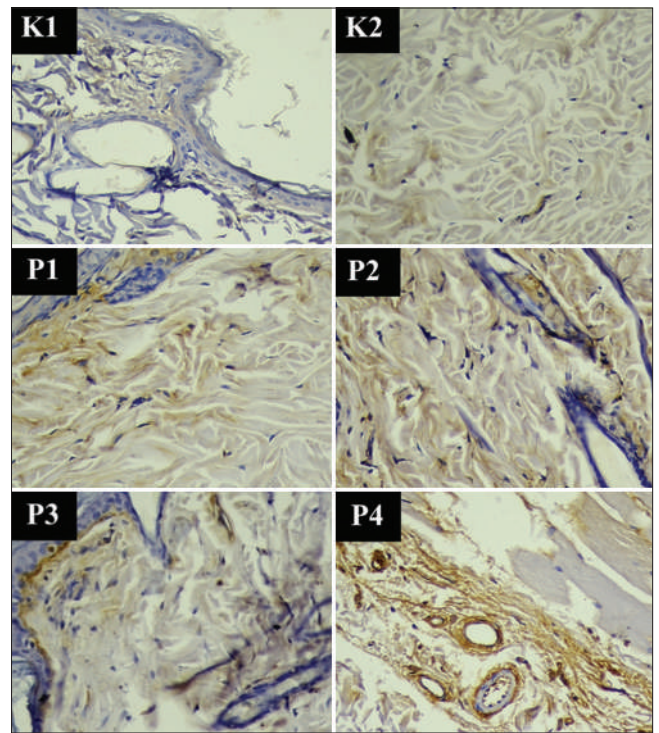


Figure 3: Immunohistochemical description of TGF-β wound tissue. (K1) Without intervention. (K2) Hydrocortisone cream 2.5%. (P1) Aloe vera oil. (P2) Ozonated Aloe vera oil of 300 mg/ml. (P3) Ozonated Aloe vera oil of 600 mg/ml. (P4). Ozonated Aloe vera oil of 1200 mg/ml

in the following table. This shows that the data were not normally distributed and the ANOVA requirements were not met, so the analysis was continued with the Kruskal–Wallis test.

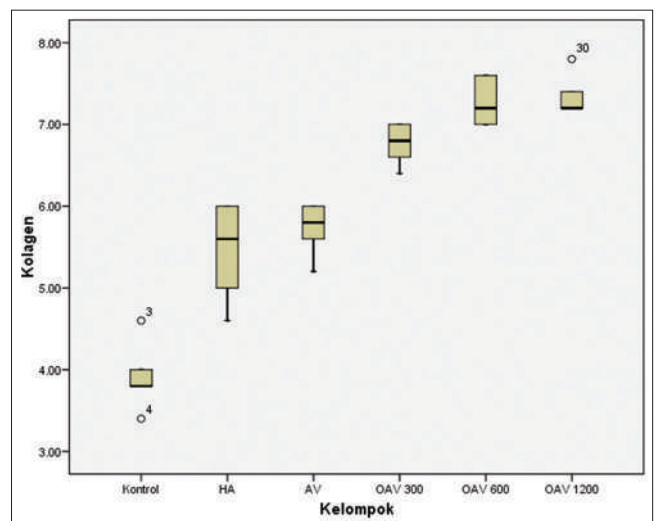


Figure 4: Boxplot graph of collagen density of research samples

The results of the Kruskal–Wallis test showed a significance of $p = < 0.001$ ($p < 0.05$), meaning that there was a significant difference in the treatment between groups. To find out which group was significantly different, a follow-up Mann–Whitney test was carried out. The results of the Mann–Whitney test are shown in Table 5.

Table 3: Post hoc LSD test results of the expression of TGF- β

Group	II	p	Information
Control	Hydrocortisone	0.271	Not significant
	AV	0.014	Significant
	Ozonated AV 300 mg	0.002	Significant
	Ozonated AV 600 mg	0.001	Significant
	Ozonated AV 1200 mg	< 0.001	Significant
Hydrocortisone	AV	0.146	Not significant
	Ozonated AV 300 mg	0.035	Significant
	Ozonated AV 600 mg	0.020	Significant
	Ozonated AV 1200 mg	0.002	Significant
AV	Ozonated AV 300 mg	0.520	Not significant
	Ozonated AV 600 mg	0.370	Not significant
	Ozonated AV 1200 mg	0.079	Not significant
	Ozonated AV 300 mg	0.787	Not significant
Ozonated AV 300 mg	Ozonated AV 600 mg	0.787	Not significant
	Ozonated AV 1200 mg	0.229	Not significant
	Ozonated AV 1200 mg	0.347	Not significant

In the *post hoc* Mann–Whitney test, there was a significant difference between the control group and the hydrocortisone, AV, Ozonated AV 300 mg, Ozonated AV 600 mg, and Ozonated 1200 groups; between the hydrocortisone group and the Ozonated AV 300 mg, Ozonated AV 600 mg and Ozonated AV 1200 mg groups; between the AV group and the Ozonated AV 300 mg, Ozonated AV 600 mg and Ozonated AV 1200 mg groups. Furthermore, the Ozonated AV 300 mg group was significant to the Ozonated AV 600 mg and Ozonated AV 1200 mg groups.

Table 4: Normality test results of collagen density using the Shapiro–Wilk

Group	N	Mean \pm SD	Median (min–max)	p	Note
Control	5	3.92 \pm 0.44	3.8 (3.4–4.6)	0.607	N
HA	5	5.44 \pm 0.62	5.6 (4.6–6.0)	0.332	N
AV	5	5.72 \pm 0.33	5.8 (5.2–6.0)	0.314	N
Ozonated AV 300 mg	6	6.77 \pm 0.27	6.8 (6.4–7.0)	0.065	N
Ozonated AV 600 mg	6	7.27 \pm 0.27	7.2 (7.0–7.6)	0.093	N
Ozonated AV 1200 mg	6	7.33 \pm 0.24	7.2 (7.2–7.8)	0.003	TN

Description: N = Normal, TN = Abnormal, Normal ($p > 0.05$)

Table 4a: Kruskal–Wallis test results of collagen density

Group	Mean \pm SD	p
Control	3.92 \pm 0.44	< 0.001
HA	5.44 \pm 0.62	
AV	5.72 \pm 0.33	
Ozonated AV 300 mg	6.77 \pm 0.27	
Ozonated AV 600 mg	7.27 \pm 0.27	
Ozonated AV 1200 mg	7.33 \pm 0.24	

Overview of collagen density examination

Based on histological examination using H&E staining to assess the collagen density from wound tissue cuts in experimental animals in this study, the results are shown in Figure 5.

Table 5. Post hoc Mann–Whitney test results of collagen density

Group	II	p	Information
Control	HA	0.011	Significant
	AV	0.009	Significant
	Ozonated AV 300 mg	0.005	Significant
	Ozonated AV 600 mg	0.006	Significant
	Ozonated AV 1200 mg	0.005	Significant
HA	AV	0.517	Not significant
	Ozonated AV 300 mg	0.005	Significant
	Ozonated AV 600 mg	0.006	Significant
	Ozonated AV 1200 mg	0.005	Significant
AV	Ozonated AV 300 mg	0.005	Significant
	Ozonated AV 600 mg	0.006	Significant
	Ozonated AV 1200 mg	0.005	Significant
	Ozonated AV 300 mg	0.012	Significant
Ozonated AV 300 mg	Ozonated AV 600 mg	0.003	Significant
	Ozonated AV 1200 mg	0.492	Not significant

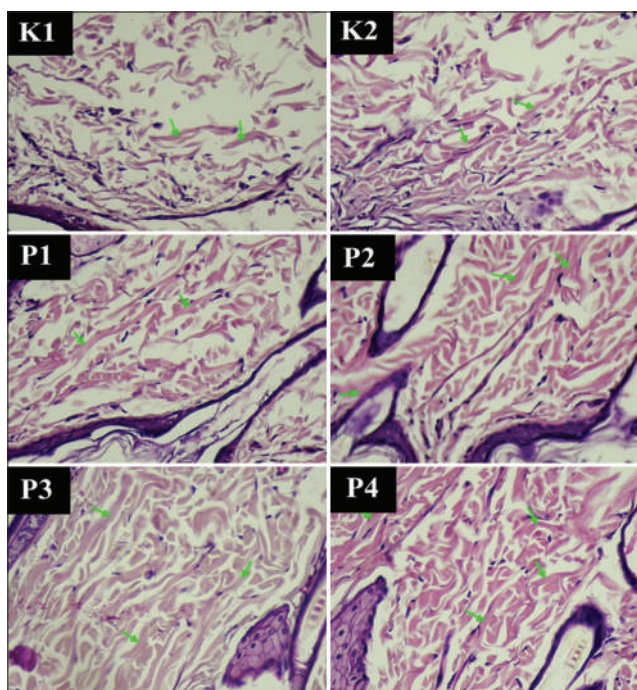


Figure 5: Collagen density using H&E staining of wound tissue. (K1) Without intervention. (K2) Hydrocortisone cream 2.5%. (P1) Aloe vera oil (P2). Ozonated Aloe vera oil of 300 mg/ml. (P3) Ozonated Aloe vera oil of 600 mg/ml. (P4) Ozonated Aloe vera oil of 1,200 mg/ml

Correlation between expression of TGF- β and collagen density

Correlation test was conducted to determine whether there was a correlation between the expression of TGF- β and collagen density variables in radiation dermatitis wound healing.

The results of the data normality test using Shapiro–Wilk showed that the expression of TGF- β data were normally distributed, namely, $p = 0.534$ ($p > 0.05$), while the collagen density data were not normally distributed $p = 0.005$ ($p < 0.05$), so the correlation test used was the Spearman correlation test (Table 6).

Table 6: Spearman correlation test results of TGF- β and collagen density

Variable	p	r
TGF- β	< 0.001	0.722
Collagen		

The results of the Spearman's rho correlation test showed a value of $p = < 0.001$ and $r = 0.722$, from these results, it can be concluded that there was a strong and unidirectional significant correlation between TGF- β to collagen.

Discussion

In this study, the expression of TGF- β was expressed by cells in wound tissue that were seen on immunohistochemical staining and was measured semiquantitatively using the Allred score to see the

proportion per 100 cells stained; and the intensity of staining was calculated per 100 cells/field of view in five fields of view with a 400× magnification. After that, the average was calculated. Meanwhile, for collagen density in the dermatitis wound tissue, examination was calculated in five fields of view with a 400× magnification binocular microscope and Hematoxylin eosin staining.

Ozone is widely recognized as one of the best bactericidal, antiviral, and antifungal agents. Ozone's antiseptic properties can help reduce potential pathogens in wounds, thereby suppressing neutrophil counts, stopping inflammation, and accelerating wound repair [11], [12], [13]. Ozone also causes an increase in the expression of TGF- β , PDGF, and VEGF which are known to play a role in the wound healing process; this has been reported in clinical and experimental studies with ozone therapy. TGF- β is one of the growth factors that stimulate angiogenesis, fibroblast proliferation, and myofibroblast differentiation, which, in turn, will increase collagen production thereby accelerating the wound healing process [13], [14], [15].

In this study, it was proven that the administration of *Aloe vera* oil with or without ozonation resulted in better healing than the group without therapy and was equivalent to or better than the hydrocortisone group.

Radiation dermatitis

Radiation dermatitis occurs as a result of cutaneous or subcutaneous lesions from exposure to external beam radiation. Radiation reduces neovascularization, fibroblast proliferation, collagen deposition, and level of growth factors for wound healing. The inhibited growth factors are transforming growth factor β -1 (TGF β -1) and basic fibroblast growth factor (bFGF) in the acute phase. In the chronic phase of wound healing in radiation scars, TGF β -1 levels increase [4].

In this study, external radiation of 7 Gy gamma rays on the backs of rats of 4 × 4 cm showed a significant effect in causing radiation dermatitis. This is consistent with the results of study by Ran et al., where external gamma ray radiation of 1–8 Gy causes wounds accompanied by exudate, necrotic tissue, or inflammation [16]. The results of this study are supported by a previous study by Andrade et al., who used animal models to study radiation-induced skin lesions. In this study, skin lesions were induced in Wistar rats by irradiating an electron beam of energy 4 MeV, using a dose rate of 240 cGy/min, for 3 different doses (10 Gy, 40 Gy, and 60 Gy). The skin was observed on days 5, 10, and 25 after exposure to ionizing radiation. The inflammatory infiltrate process was observed on days 5 and 10 for the 40 Gy and 60 Gy groups by assessing the progressive increase

in TGF β -1 and the characterization of collagen fibers in the high dose group. The study showed that lesions caused by ionizing radiation in Rats were very similar to radiodermatitis in patients undergoing radiotherapy as was the case with the results of this study [17].

Expression of TGF- β

From the results of the study, it was found that giving *Aloe vera* to dermatitis wounds with or without ozonation showed an effect, where the average expression of TGF- β in radiation dermatitis wounds tended to increase significantly compared to the group that did not receive *Aloe Vera*.

This study has proven that the administration of ozonated *Aloe vera* oil can increase the expression of TGF- β higher than the positive and negative control groups. The results of this study are supported by previous studies conducted by Atiba et al. and Zhang et al. This is because during the wound healing process, platelets will produce various growth factors and inflammatory cytokines such as TGF- β , PDGF, EGF, and FGF, all of which will appear in the inflammatory phase and some of their functions are chemoattractants [4], [14], [18]. *Aloe vera* in this study is useful in the wound healing process because of its extract content, namely *acemannan*, β *sitosterol* which activates macrophages in wounds. Besides, the role of ozone is to stimulate TGF- β and other growth factors to the wound area. TGF- β and other growth factors induce the fibroblasts proliferation where the process is affected by oxygen supply [15]. In radiation dermatitis there are pathological changes such as cellular depletion, matrix changes and microvascular damage that cause hypoxia in the wound tissue so that the wound healing process as mentioned above is disrupted [19].

In a previous study by Travagli et al., ozone has the ability to heal wounds, due to its "oxidative killing" effect on organisms. The use of ozone as a therapy provides many benefits because ozone will eliminate pathogens and activate the fibroblasts proliferation by releasing O₂. Furthermore, the formation of intercellular matrix will occur with the keratin fibroblasts proliferation and so, wound healing begins [13].

Collagen density

The average collagen density in the ozonated or non-ozonated group compared to the negative control and hydrocortisone cream 2.5% groups was higher. This study is supported by a previous study conducted by Taqwim Hidayat et al., which showed that the administration of ozonated *Aloe vera* oil had an effect on collagen thickness [16].

This study has proven that the collagen density in the group that was given ozonated *Aloe vera* oil was higher than that of the control group. This is because

ozone therapy is an alternative therapy that can be used as a disinfectant and can induce strong oxidative stress, thereby stimulating cell and organ protection mechanisms [20]. In ozone therapy, various anti-oxidant systems are activated to defend the body against oxidation and the occurrence of ROS (Reactive Oxygen Species) in the form (O₃, H₂O₂, and OH⁺), which leads to the production of antioxidant enzymes. These ROS act as secondary messengers for various immunocytic and non-lymphoid cells involved in the wound repair process and also play important roles in repairing inadequate tissue and coordinating the recruitment of lymphoid cells to the site of injury [8]. Ozonated *Aloe vera* oil increases reactive oxygen species (ROS) and reactive nitrogen species (RNS) around the wound site, such as platelets, macrophages, fibroblasts, endothelial cells, and keratinocytes that act as wound healing radicals. Fibroblasts around the wound site will produce collagen so that the wound healing process occurs [19], [21], [22]. With the increasing number of fibroblasts, it will increase the production, metabolism of collagen and alters the composition of collagen (more in type III) and increase the degree of collagen cross-linking so that the wound healing process is not disrupted and becomes faster [19], [21].

Correlation of TGF- β and collagen density on wound healing

The results of this study indicate that there was a strong and unidirectional significant correlation between the expression of TGF- β and collagen density variables. The content of *acemannan*, β *sitosterol*, and glycoproteins in *Aloe vera* will activate macrophages in wounds and the role of ozone will stimulate TGF- β and other growth factors to the wound area. This allows TGF- β and other growth factors to induce the fibroblasts proliferation, which in turn will significantly increase collagen synthesis [15]. *Aloe vera* and ozone do not only cause an increase in the collagen content of the wound but also change the composition of collagen (more in type III) and increase the degree of collagen cross-linking. This can accelerate wound contraction and increase the breaking strength of the resulting scar tissue [19], [21].

TGF- β will stimulate angiogenesis, fibroblast proliferation, myofibroblast differentiation which, in turn, will increase collagen production thus accelerating the wound healing process [13], [14], [15]. This shows that the occurrence of the collagen production process can increase or decrease depending on the number of growth factors, so that the higher the expression of TGF- β the more collagen is produced and the wound healing process is also faster.

The limitations of this study are related to expensive equipment and costs, so that radiation is only given once. Besides, the immunohistochemical examination is also relatively expensive.

Conclusion

1. There was a significant difference in the expression of TGF- β between the group treated with 300, 600, and 1200 mg/ml ozonated *Aloe vera* and the group that did not receive any therapy (negative control) and the group that received hydrocortisone therapy (positive control).
2. There was a significant difference in the collagen density between the group treated with 300, 600, and 1200 mg/ml ozonated *Aloe vera* and the group that did not receive any therapy (negative control) and the group that received hydrocortisone therapy (positive control).
3. There is a significant correlation between the expression of TGF- β and collagen density in healing radiation dermatitis.

References

1. Djuanda A, Hamzah M, Aisah S. Ilmu Penyakit Kulit Dan Kelamin. 5th ed. Jakarta: Badan Penerbit Fakultas Kedokteran Universitas Indonesia; 2010.
2. Khanna NR, Kumar DP, Laskar SG, Laskar S. Radiation dermatitis: An overview. Indian J Burn. 2013;21(1):24. <https://doi.org/10.4103/0971-653x.121877>
3. Farrugia CJ, Burke ES, Haley ME, Bedi KT, Gandhi MA. The use of *Aloe vera* in cancer radiation: An updated comprehensive review. Complement Ther Clin Pract. 2019;35:126-30. <https://doi.org/10.1016/j.ctcp.2019.01.013> PMID:31003648
4. Atiba A, Nishimura M, Kakinuma S, Hiraoka T, Goryo M, Shimada Y, et al. *Aloe vera* oral administration accelerates acute radiation-delayed wound healing by stimulating transforming growth factor- β and fibroblast growth factor production. Am J Surg. 2011;201(6):809-18. <https://doi.org/10.1016/j.amjsurg.2010.06.017> PMID:21396624
5. Bray FN, Simmons BJ, Wolfson AH, Nouri K. Acute and chronic cutaneous reactions to ionizing radiation therapy. Dermatol Ther (Heidelb). 2016;6(2):185-206. <https://doi.org/10.1007/s13555-016-0120-y> PMID:27250839
6. Takzaree N, Hadjiakhondi A, Hassanzadeh G, Rouini MR, Manayi A, Zolbin MM. Transforming growth factor- β (TGF- β) activation in cutaneous wounds after topical application of *Aloe Vera* gel. Can J Physiol Pharmacol. 2016;94(12):1285-90. <https://doi.org/10.1139/cjpp-2015-0460> PMID:27660884
7. Kim HS, Noh SU, Han YW, Kim KM, Kang H, Kim HO, et al. Therapeutic effects of topical application of ozone on acute cutaneous wound healing. J Korean Med Sci. 2009;24(3):368-74. <https://doi.org/10.3346/jkms.2009.24.3.368> PMID:19543419
8. Campanati A, De Blasio S, Giuliano A, Ganzetti G, Giuliadori K, Pecora T, et al. Topical ozonated oil versus hyaluronic gel for

- the treatment of partial-to full-thickness second-degree burns: A prospective, comparative, single-blind, non-randomised, controlled clinical trial. *Burns*. 2013;39(6):1178-83. <https://doi.org/10.1016/j.burns.2013.03.002>
PMid:23579036
9. Hymes SR, Strom EA, Fife C. Radiation dermatitis: Clinical presentation, pathophysiology, and treatment 2006. *J Am Acad Dermatol*. 2006;54(1):28-46. <https://doi.org/10.1016/j.jaad.2005.08.054>
PMid:16384753
 10. Vahlepi R, Arifin MT, Nur M, Muniroh M, Susilaningih N. Ozonated *Aloe vera* oil improve wound healing by decreasing neutrophil count and wound diameter in sprague dawley rats with full-thickness skin defect. *Indones J Biomed Sci*. 2020;14(2):48-54. <https://doi.org/10.15562/ijbs.v14i2.253>
 11. Cargnello M, Roux PP. Activation and function of the MAPKs and their substrates, the MAPK-activated protein kinases. *Microbiol Mol Biol Rev*. 2011;75(1):50-83. <https://doi.org/10.1128/mubr.00031-10>
PMid:21372320
 12. Anzolin AP, Da Silveira-Kaross NL, Bertol CD. Ozonated oil in wound healing: What has already been proven? *Med Gas Res*. 2020;10(1):54-9. <https://doi.org/10.4103/2045-9912.279985>
PMid:32189671
 13. Travagli V, Zanardi I, Valacchi G, Bocci V. Ozone and ozonated oils in skin diseases: A review. *Mediators Inflamm*. 2010;2010:610418. <https://doi.org/10.1155/2010/610418>
PMid:20671923
 14. Zhang J, Guan M, Xie C, Luo X, Zhang Q, Xue Y. Increased growth factors play a role in wound healing promoted by noninvasive oxygen-ozone therapy in diabetic patients with foot ulcers. *Oxid Med Cell Longev*. 2014;2014:273475. <https://doi.org/10.1155/2014/273475>
PMid:25089169
 15. Hashemi SA, Madani SA, Abediankenari S. The review on properties of *Aloe vera* in healing of cutaneous wounds. *Biomed Res Int*. 2015;2015:714216. <https://doi.org/10.1155/2015/714216>
PMid:26090436
 16. Ran X, Cheng T, Shi C, Xu H, Qu J, Yan G, et al. The effects of total-body irradiation on the survival and skin wound healing of rats with combined radiation-wound injury. *J Trauma*. 2004;57(5):1087-93. <https://doi.org/10.1097/01.TA.0000141885.72033.C7>
PMid:15580037
 17. De Andrade CB, Ramos IP, De Moraes AC, Do Nascimento AL, Salata C, Dos Santos Goldenberg RC, et al. Radiotherapy-induced skin reactions induce fibrosis mediated by TGF- β 1 cytokine. *Dose Response*. 2017;15(2):8. <https://doi.org/10.1177/1559325817705019>
PMid:28507463
 18. Pakyari M, Farrokhi A, Maharlooei MK, Ghahary A. Critical role of transforming growth factor beta in different phases of wound healing. *Adv Wound Care (New Rochelle)*. 2013;2(5):215-24. <https://doi.org/10.1089/wound.2012.0406>
PMid:24527344
 19. Jacobson LK, Johnson MB, Dedhia RD, Niknam-Bienia S, Wong AK. Impaired wound healing after radiation therapy: A systematic review of pathogenesis and treatment. *JPRAS Open*. 2017;13:92-105. <https://doi.org/10.1016/j.jptra.2017.04.001>
 20. Degli Agosti I, Ginelli E, Mazzacane B, Peroni G, Bianco S, Guerriero F, et al. Effectiveness of a short-term treatment of oxygen-ozone therapy into healing in a posttraumatic wound. *Case Rep Med*. 2016;2016:9528572. <https://doi.org/10.1155/2016/9528572>
PMid:27738434
 21. Surjushe A, Vasani R, Saple D. *Aloe vera*: A short review. *Indian J Dermatol*. 2008;53(4):163-6. <https://doi.org/10.4103/0019-5154.44785>
PMid:19882025
 22. Hidayat AT, Arifin MT, Nur M, Muniroh M, Susilaningih N. Ozonated *Aloe vera* oil effective increased the number of fibroblasts and collagen thickening in the healing response of full-thickness skin defects. *Int J Inflamm*. 2021;2021:6654343. <https://doi.org/10.1155/2021/6654343>
PMid:33628417