

2023 drg. IchaWJARR-2023- 0229.pdf *by*

Submission date: 10-May-2023 12:32AM (UTC+0800)

Submission ID: 2088693275

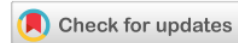File name: 2023 drg. IchaWJARR-2023-0229.pdf (875.95K)

Word count: 5190

Character count: 28275



(REVIEW ARTICLE)



Immunohistochemical findings of osteopontin expression in various odontogenic cyst and odontogenic tumour: A systematic review

Fredy Mardiyantoro ^{1, 2, *}, Elissa Chairani ³, Pratiwi Soesilawati ⁴, Taufan Bramantoro ⁵, Dini Setyowati ⁵, Theresia Indah Budhy ³ and David B Kamadjaja ⁶

¹ Department of Oral and Maxillofacial Surgery, Faculty of Dentistry, Universitas Brawijaya, Indonesia.

² Master Program of Dental Health Science, Faculty of Dental Medicine, Universitas Airlangga, Indonesia.

³ Dentistry Study Program, Faculty of Medicine, Universitas Diponegoro, Indonesia.

⁴ Department of Oral Biology, Faculty of Dental Medicine, Universitas Airlangga, Indonesia.

⁵ Department of Public Health, Faculty of Dental Medicine, Universitas Airlangga, Indonesia.

⁶ Department of Oral and Maxillofacial Surgery, Faculty of Dental Medicine, Universitas Airlangga, Indonesia.

² World Journal of Advanced Research and Reviews, 2023, 17(02), 243–251

Publication history: Received on 25 December 2022; revised on 05 February 2023; accepted on 07 February 2023

Article DOI: <https://doi.org/10.30574/wjarr.2023.17.2.0229>

Abstract

Objective: This study aimed to assess osteopontin expression following immunohistochemical staining of odontogenic cysts and tumors.

Methods: A systematic review was conducted based on PRISMA Statement. The literature search was carried out through PubMed, Scopus, and Science Direct databases, covering all the articles published up to October 2021, using a combination of the key terms 'osteopontin', 'odontogenic tumor', 'odontogenic cyst', and 'expression'. The tool of the Joanna Briggs Institute Critical Appraisal Checklist for Cross Sectional Studies was applied to examine the quality of the selected articles.

Results: The search strategy yielded in total 853 possibly relevant references. After removal of duplicates, 614 titles and abstracts were initially reviewed. From these, 22 were independently assessed in full text for eligibility, and seven studies were included to the review. The analysis revealed the frequency of osteopontin expression in odontogenic cysts as 35.3% for (-) score, 23.5% for (+) score, 21.6% for (++) score, 19.6% for (+++) score; and in odontogenic tumors as 11.3% for (-) score, 1.9% for (+) score, 3.8% for (++) score, and 83% for (+++) score.

Conclusions: The present study showed different frequency of osteopontin expression between odontogenic cysts and tumors. The frequency of OPN expression with a (+++) score in odontogenic tumor was higher than that of in odontogenic cyst. The highest frequency of OPN expression with (-) score was shown in odontogenic cysts. Osteopontin has a different expression pattern related to the progressivity and recurrence of the lesion.

Keywords: Immunohistochemistry; Osteopontin; OPN; Odontogenic tumor; Odontogenic cyst

1. Introduction

Odontogenic lesions can be divided into cysts and tumors, solid masses but not necessarily neoplastic. Intra-bony lesions of the jaws are identified most commonly on radiographic imaging [1]. The development of odontogenic tumors originates from epithelial, ectomesenchymal, or mesenchymal elements of the tooth-forming apparatus. Each odontogenic tumor presents different clinical, radiographic and histopathological characteristics [2]. In comparison,

* Corresponding author: Fredy Mardiyantoro; E-mail: fredy.fre@ub.ac.id

odontogenic cysts can be derived from developmental and inflammatory cysts. The odontogenic cyst is a lesion in an epithelial lined pathological cavity. Proper diagnosis of odontogenic cysts is critical because different biological behaviors of the various types of cysts require different treatment plans and present significantly different risk for affected patients [3,4].

Osteopontin (OPN) is an extracellular matrix protein identified in bone and released by osteoblasts and osteoclasts [5]. Osteopontin also exist in a large number of tissues with its various essential roles. It contributes to bone remodeling and is increased during tumor growth through a variety of different mechanisms [6]. Previous study showed that high expression level of osteopontin in either the plasma or the tumor of the patients with oral squamous cell carcinoma (OSCC) was associated with tumor progression, suggesting that osteopontin expression is an important prognostic factor for OSCC [7]. The OPN expression was also associated with malignant bone tumors. The malignant cases had significantly elevated the level of OPN expression compared to the benign cases [8].

Specific examination of protein expression can be performed through immunohistochemical analysis (IHC). In odontogenic lesion or tumor cases, IHC examination can show the type of protein expressed by the tumor or cells in the surrounding tissue of the tumor. The immunohistochemical marker analysis may characterize the expression profile of a lesion and reveal whether the profile is a normal developing odontogenic tissues or a range of odontogenic tumors [9-11]. A number of studies of OPN in odontogenic lesions showed an increased OPN expression by immunohistochemical examination. Various studies were conducted to examine the expression of osteopontin in odontogenic cysts and tumors. A study conducted by Masloub *et al.* investigated the expression of osteopontin in dentigerous cyst and ameloblastoma and the correlation of their expression with neoplastic potentiality, local invasion and risk of local recurrence [12].

This study aimed to assess the osteopontin expression in odontogenic cyst and tumors by conducting a systematic review. The knowledge about osteopontin expression might be helpful for oral and maxillofacial surgeons, as it could guide evidence-based decision making on the management of these lesions.

4

2. Material and methods

2.1. Protocol and Eligibility criteria

This systematic review was conducted according to the Preferred Reporting Items for Systematic Reviews and Meta-Analysis (PRISMA) protocols (figure 1) [13]. Furthermore, the reporting of this systematic review was guided by the PRISMA checklist [14]. The following inclusion criteria were applied: 1) observational cross sectional study design, 2) articles in English language, 3) odontogenic tumor and cyst as the object of study, 4) focus on OPN expression using immunohistochemistry. The article was excluded for the following reasons: 1) using different method of examination for osteopontin expression, 2) tumor in oral cavity but not classified as odontogenic tumor or cyst.

2.2. Information sources and search strategy

Search strategies were individually developed for three databases: PubMed, Scopus, and Science Direct, covering all the articles published up to October 2021, using a combination of the medical subject heading (MeSH) terms 'osteopontin', 'odontogenic tumor', 'odontogenic cyst', and 'expression'. All database searches were last conducted on December 3, 2021. In addition, manual searches were performed to find other eligible articles that were not available in the electronic databases. All references were managed and duplicates were removed using specific bibliographic software (Mendeley).

2.3. Study selection and data collection

Study selection was performed in a two-phase process. Phase-1 was carried out in a web application specific for systematic reviews, in which two reviewers (F.M and E.C.) independently applied the eligibility criteria to titles and abstracts of all identified references. In phase-2, the same two reviewers separately applied the eligibility criteria to full-text articles. Any disagreements were resolved in a consensus meeting. If necessary, a third reviewer (P.S.) was consulted for selection and evaluation of the included studies. The data collection was performed by two reviewers (F.M and E.C.), and included study type, method, histopathological diagnosis, and outcome measures.

2.4. Risk of bias in individual studies

Two oral and maxillofacial surgeons (F.M and E.C.) independently performed the risk of bias (RoB) assessment of included articles according to the Joanna Briggs Institute (JBI) Critical Appraisal Checklist for Cross Sectional Studies [15]. The JBI appraisal checklist is based on 8 items and each item is assessed by scoring yes, no and unclear or not

applicable. The total score obtained of each study was presented as percentages and each study was categorized according to different levels of risk of bias. The risk of bias was classified as high when the study reached up to 49% of "yes" score, moderate when the study reached from 50 to 69% of "yes" score, and low when the study reached more than 70% of "yes" score. The detail of quality assessment as per JBI checklist is presented in Table 1.

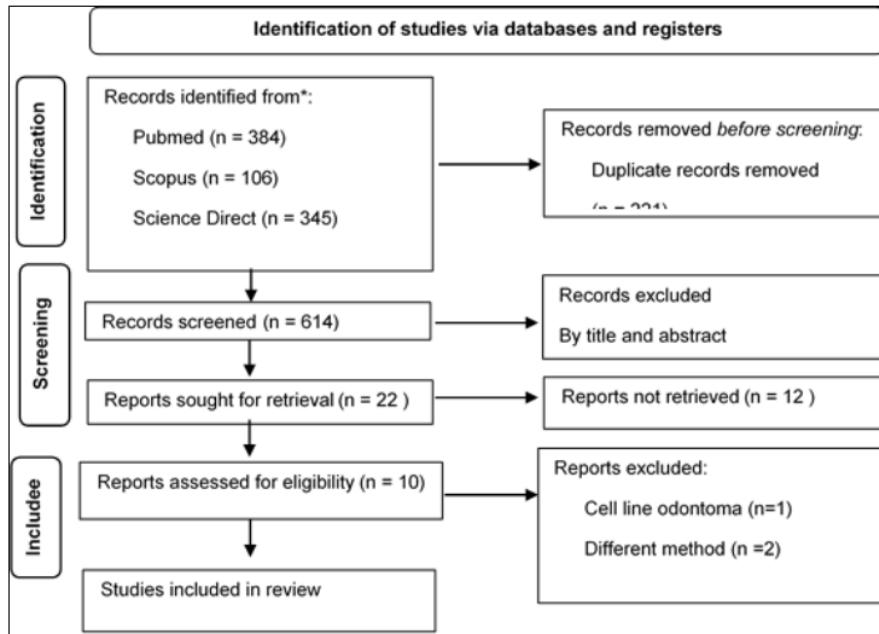


Figure 1 Flow diagram of literature search and selection process

Table 1 Quality assessment of individual study

Study	Were the criteria for inclusion in the sample clearly defined?	Were the study subjects and the setting described in detail?	Was the exposure measured in a valid and reliable way?	Were objective, standard criteria used for measurement of the condition?	Were confounding factors identified?	Were strategies to deal with confounding factors stated?	Were the outcomes measured in a valid and reliable way?	Was appropriate statistical analysis used?
[16]	Yes	Yes	Yes	Yes	Yes	Yes	Yes	Yes
[17]	Yes	Yes	Yes	Yes	Unclear	Unclear	Yes	Yes
[18]	Yes	Yes	Yes	Yes	Yes	Yes	Yes	Yes
[19]	Yes	Yes	Yes	Yes	Yes	Yes	Yes	No
[20]	Yes	Yes	Yes	Yes	Yes	Yes	Yes	Yes
[21]	Yes	No	Yes	Yes	Yes	Yes	Yes	No
[22]	Yes	Yes	Yes	Yes	Yes	Yes	Yes	Yes

2.5. Data extraction and quality assessments

Because there was variation in the type of odontogenic tumor or cyst in each study, a full meta-analysis was not feasible. We extracted data presented as text, figures, or tables from the published manuscript. There was no duplication of data between studies. Information for the following characteristics were extracted from studies: the title of article, author,

year of publication, method of examination, histopathological diagnosis, number of sample, and number of OPN expression based on scoring group. All selected articles for this review almost used the same method to evaluate the percentage of positively stained cells after immunohistochemical examination using score of (-); (+); (++) and (+++).

3. Results

3.1. Studies selection and risk of bias

The initial searches resulted in 835 studies, excluding 221 studies duplicates. A total of 614 titles and abstracts were initially reviewed. After removing articles outside of scope, 22 full text articles were independently assessed for eligibility. The reference list of the eligible articles did not reveal any additional articles. There were ten studies assessed for eligibility. Excluded studies and the reasons for refusal are shown in table 2. Full review identified 7 studies fitting inclusion criteria for the review [16, 17, 18, 19, 20, 21, 22]. The process of study selection is described in Figure 1. All studies met 70% of critical appraisal criteria defined by Joanna Briggs Institute [15].

Table 2 Articles excluded and their reasons

Authors	Type of lesion	No. of Cases	Reason
[23]	OKC	16	Evaluation of osteopontin using gen expression analysis by RT-PCR
[12]	DC AME	9 17	Immunohistochemical analysis of OPN using image] software that difficult to compare scoring of expression
[24]	Odontoma	29	Evaluation of osteopontin using gen expression analysis by RT-PCR

3.2. Study characteristic

A total of 7 articles with 208 cases of odontogenic lesions were processed for final review. The odontogenic lesion is classified as an odontogenic cyst and tumor based on the latest classification from WHO 2017 [23]. The characteristics of studies included in the review are summarized in Table 3. There were four articles that reported odontogenic cyst and three articles reported odontogenic tumor in relation with OPN expression. The total cases of studies that reported OPN expression for odontogenic cyst was 153 cases and 53 cases for odontogenic tumor. We estimated the frequency of OPN expression from each case and found that in odontogenic cyst cases, the most frequent scoring of OPN expression was (-) score (35.3% cases) and the lowest was (+++) score (19.6% cases). In odontogenic tumor cases, the most frequent scoring of OPN expression was (+++) score (83% cases), and the lowest was (+) score (1.9% cases) as shown in Table 3.

Table 3 Frequency of OPN expression between odontogenic cyst and odontogenic tumor

Cyst Type	Total cases	OPN expression score				Tumor type	Total cases	OPN expression score			
		-	+	++	+++			-	+	++	+++
OKC	54	24	7	3	20	OF	5	0	0	0	5
DC	30	12	10	8	0	PCOF	7	2	1	1	3
RC	55	18	19	15	3	AOT	11	0	0	0	11
COC	14	0	0	7	7	AME	30	4	0	1	25
Total (n%)	153 (100%)	54 (35.3%)	36 (23.5%)	33 (21.6%)	30 (19.6%)	Total (n%)	53 (100%)	6 (11.3%)	1 (1.9%)	2 (3.8%)	44 (83%)

Note: R: Retrospective; IHC: immunohistochemistry; OKC: odontogenic keratocyst; DC: dentigerous cyst; RC: radicular cyst; COC: Calcifying Odontogenic Cyst; OF: Ossifying Fibroma; PCOF: Peripheral Cemento Ossifying Fibromas; AOT: Adenomatoid odontogenic Tumor; AME: Ameloblastoma.

3.3. OPN expression in odontogenic cyst

The four included studies reported OPN expression in odontogenic cysts [16, 18, 19] and [20]. The types of odontogenic cysts that we found in the studies were odontogenic keratocyst (OKC), dentigerous cyst (DC), radicular cyst (RC) and calcifying odontogenic cyst (COC). We evaluated the frequency of OPN expression in scoring system. The OKC showed the highest OPN expression with (-) and (+++) score as 44.4% and 66.7%, respectively. The COC only expressed OPN with (++) and (+++) score as 21.2% and 23.3%, respectively. The types of cysts which showed OPN expression in all scores were OKC and RC. For DC, there was OPN expression for (-), (+), and (++) score but not for (+++) score as shown in Figure 2.

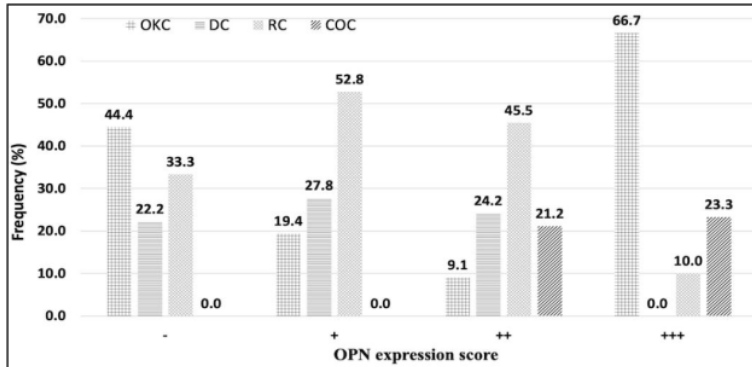


Figure 2 OPN Expression in various type of odontogenic cyst

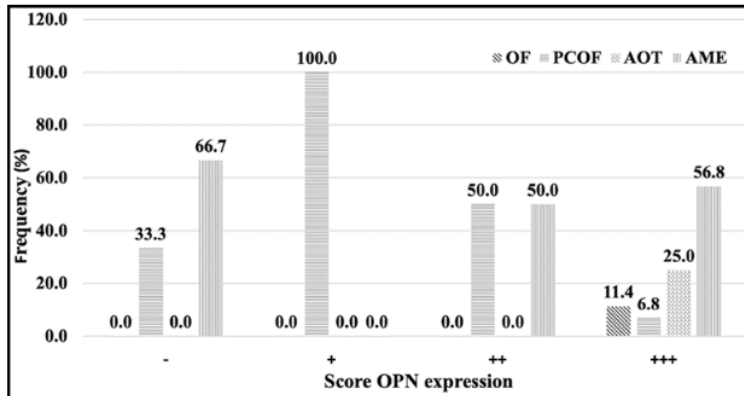


Figure 3 OPN Expression in various type of odontogenic tumor

3.4. OPN expression in odontogenic tumor

We found three studies that reported the OPN expression in odontogenic tumors [17, 22, 24]. The types of tumors included in the studies were ossifying fibroma (OF), peripheral cemento-ossifying fibromas (PCOF), adenomatoid tumor (AOT), and ameloblastoma (AME). Furthermore, we evaluated the frequency of OPN expression in each type of odontogenic tumor. The OPN expression in OF and AOT only appeared in (+++) score, but PCOF showed osteopontin expression in all scores. In (+++) score, the highest expression was seen in ameloblastoma (56.8%), followed by AOT (25%), OF (11.4%) and the lowest expression was seen in PCOF (6.8%). Interestingly, only PCOF that showed osteopontin expression in (+) score as shown in Figure 3.

4. Discussion

Osteopontin (OPN) is involved in the regulation of both physiological and pathological mineralization. In normal bone tissue, OPN is expressed by both osteoclasts and osteoblasts. Under normal conditions, OPN will direct osteoclasts to inhibit hydroxyapatite formation. OPN also affects bone resorption [25]. Under inflammatory conditions, OPN is upregulated during macrophage differentiation by regulating migration, survival, phagocytosis, and production of pro-inflammatory cytokines [26]. OPNs play a crucial role in mediating tumor progression by regulating multiple pathways. Angiogenesis is one of the essential processes for tumor development. The angiogenic process is regulated by various pro-angiogenic factors secreted by tumor cells. Overexpression of osteopontin stimulates angiogenesis via $\alpha v\beta 3$ activation [27].

In this study, we used the classification of odontogenic tumors and cysts based on the 2017 WHO classification. Odontogenic keratocyst (OKC) type is included in the odontogenic cyst group [28]. Moreover, there is actually a lot of disagreement about the re-classification of OKC into the odontogenic cyst group in the 2017 WHO classification, given the OKC is a potentially aggressive and recurrent odontogenic lesion which is different from regular odontogenic cysts [29]. According to data obtained in the present systematic review, we found that OPN was expressed in both odontogenic cysts and odontogenic tumors as shown in Table 3 and 4. This expression was seen on immunohistochemical examination. The presence of osteopontin expression in odontogenic cysts and tumors suggests that osteopontin is associated with bone remodeling and growth of dental elements [30, 31]. Osteopontin also plays a role in new tissue growth and tumor metastasis [32, 33].

In odontogenic cyst group, the highest frequency of immunohistochemical staining for osteopontin expression was scored (-) as shown in Figure 2. Based on the evaluation of each score, the frequency of OPN expression with (+++) score was highest in the OKC lesion group then followed by COC lesion group (Figure 3). According to Masloub, high expression of osteopontin may indicate neoplastic potential [12]. In various studies, it has been shown that OKC has neoplastic potential. **The difference in p53 expression in OKC and DC can explain their different growth mechanism and clinical behavior.** Changes in behavior of neoplastic epithelium of OKC occur via p53 overexpression [34]. The COC also has two different variants, either as a cyst or a solid neoplasm. From various literature, the authors state that it is difficult to classify these COC lesions as they may mimic other odontogenic tumors [35, 36]. In line with the results of this study, a study by Hong *et al.* showed a high mRNA expression of OPN and osteocalcin (OCN) in OKC cases [37]. In 2005 WHO classification, OKC and COC lesions were listed in odontogenic tumor group because their nature and characteristics were different from regular odontogenic cysts [38]. Accordingly, the results in this systematic review showed that among odontogenic cyst group, OKCs and COCs had a higher neoplastic potential than dentigerous cysts and radicular cysts. In odontogenic tumor group, samples selected in this systematic review were ossifying fibroma (OF), peripheral cemento-ossifying fibromas (PCOF), adenomatoid odontogenic tumor (AOT) and ameloblastoma (AME). The frequency of OPN expression with (+++) score was highest in ameloblastoma (Figure 2). In odontogenic tumors, high expression of OPN can **identify areas with locally invasive behavior and high risk of recurrence** [12].

Osteopontin is a multifunctional protein with important functions in normal condition such as inflammation process, biomineralization, cell viability and wound healing [26, 39]. OPN is involved in pathological conditions such as tumor invasion, progression, or metastasis [32]. In mineralized tissues, OPN is released by bones. It is produced by osteoclastic and osteoblastic cells at high levels [40]. During biomineralization phase, OPN has three major functions including modulation of adherence of osseous cells, modulation of osteoclastic function and modulation of matrix mineralization [39]. Clinical studies have shown OPN overexpression in many human cancers, and in some cases, it is associated with cancer progression [41, 42].

Figure 4 shows that (+++) score is present in all OF, PCOF, AOT and AME tumor types. Studies on tumor ossifying fibroma (OF) and peripheral cemento-ossifying fibroma (PCOF) have shown that most OFs exhibit high OPN expression. Because OPN appears at an early stage of osteogenetic maturation, this suggests that OF seems to have a more remarkable ability to form hard tissues than PCOF. From overall case of odontogenic lesions in the present study, odontogenic cysts showed the highest frequency on the (-) score, while odontogenic tumors showed that of the (+++) score. Some literature suggests that there is a strong correlation between increased OPN levels in patients with cancer and increased tumor aggressiveness, increased tumor burden, and poor prognosis or survival rates [43, 44]. The growth of tumor on the jawbone may affect bone remodeling because the process of bone resorption and apposition will run abnormally. One of the osteoclastogenic mechanisms that plays a role in the remodeling process is the RANK/RANKL/OPG system [45]. The system is variably expressed in OKC, radicular cyst, and ameloblastoma in mediating tumor-associated bone osteolysis [46]. The correlation between OPN and tumor growth most likely reflects the effect of OPN on cell migration. OPN can also support in vitro attachment for a variety of cell types and promote promote migration of inflammatory and tumor cells [47].

This study has several limitations. There are still not many studies focusing on the correlation between osteopontin and odontogenic cysts or tumors. Several parameters we would have liked to include were not or inadequately reported in the studies. For example, we could not consider the quality of life and recurrence rates in the included studies. However, despite the fact that this is the only design found on the topic, we are nevertheless convinced that essential conclusions on the pattern of osteopontin expression can be drawn from the present systematic review as the results of the review are based on the best available evidences. Further, more significant data collection and analysis are needed.

5. Conclusion

This study systematically analyzed 208 cases of odontogenic cysts and tumors. The highest frequency of osteopontin expression in odontogenic cyst group was (-) score, while in odontogenic tumors was (+++) score. In odontogenic cyst group, there were differences in the frequency pattern, especially in OKC and COC as compared to other cystic lesions. Among odontogenic tumor group, ameloblastoma had the highest frequency of (+++) score for OPN expression as compared to the other ones.

Compliance with ethical standards

Acknowledgments

The authors thank the reviewers for their insightful suggestions.

Disclosure of conflict of interest

The authors declare that they have no conflict of interest.

Author's contributions

All authors contributed equally to the conception and development of the work.

References

- [1] N. R. Johnson, O. M. Gannon, N. W. Savage, and M. D. Batstone, "Frequency of odontogenic cysts and tumors: a systematic review," *J. Investig. Clin. Dent.*, vol. 5, no. 1, pp. 9-14, 2014, doi: 10.1111/jicd.12044.
- [2] W. Jing et al., "Odontogenic tumours: a retrospective study of 1642 cases in a Chinese population," *Int. J. Oral Maxillofac. Surg.*, vol. 36, no. 1, pp. 20-25, 2007, doi: 10.1016/j.ijom.2006.10.011.
- [3] B. W. Neville, D. D. Damm, C. M. Allen, and A. C. Chi, *Oral and Maxillofacial Pathology*, Fourth Ed. Canada: Elsevier, 2016.
- [4] M. A. V. Bittencourt et al., "Accuracy of computer-aided image analysis in the diagnosis of odontogenic cysts: A systematic review," *Med. Oral Patol. Oral y Cir. Bucal*, vol. 26, no. 3, pp. e368-e378, 2021, doi: 10.4317/medoral.24238.
- [5] G. Karpinsky et al., "Osteopontin: its potential role in cancer of children and young adults," *Biomark. Med.*, vol. 11, no. 4, pp. 389-402, Mar. 2017, doi: 10.2217/bmm-2016-0308.
- [6] M. A. Icer and M. Gezmen-Karadag, "The multiple functions and mechanisms of osteopontin," *Clin. Biochem.*, vol. 59, no. July, pp. 17-24, 2018, doi: 10.1016/j.clinbiochem.2018.07.003.
- [7] C. Y. Chien et al., "Comprehensive study on the prognostic role of osteopontin expression in oral squamous cell carcinoma," *Oral Oncol.*, vol. 45, no. 9, pp. 798-802, 2009, doi: 10.1016/j.oraloncology.2008.12.006.
- [8] A. Nazarizadeh et al., "Evaluation of local and circulating osteopontin in malignant and benign primary bone tumors," *J. Bone Oncol.*, vol. 29, p. 100377, 2021, doi: 10.1016/j.jbo.2021.100377.
- [9] K. D. Hunter and P. M. Speight, "The Diagnostic Usefulness of Immunohistochemistry for Odontogenic Lesions," *Head Neck Pathol.*, vol. 8, no. 4, pp. 392-399, 2014, doi: 10.1007/s12105-014-0582-0.
- [10] A. Kilinc, N. Saruhan, B. Gundogdu, E. Yalcin, U. Ertas, and G. Urvasizoglu, "Benign tumors and tumor-like lesions of the oral cavity and jaws: An analysis of 709 cases," *Niger. J. Clin. Pract.*, vol. 20, no. 11, pp. 1448-1454, Nov. 2017, doi: 10.4103/1119-3077.187309.

- [11] R. Mehngi, K. Rajendra, P. Bhagwat, S. S. Hegde, D. Sah, and V. S. Rathod, "Clinical and Histopathological Analysis of Odontogenic Tumors in Institution-A 10 Years Retrospective Study," *J. Contemp. Dent. Pract.*, vol. 19, no. 10, pp. 1288–1292, Oct. 2018.
- [12] S. M. Masloub, A. M. Abdel-Azim, and E. S. Abd Elhamid, "CD10 and osteopontin expression in dentigerous cyst and ameloblastoma," *Diagn. Pathol.*, vol. 6, no. 1, p. 44, 2011, doi: 10.1186/1746-1596-6-44.
- [13] L. Shamseer et al., "Preferred reporting items for systematic review and meta-analysis protocols (prisma-p) 2015: Elaboration and explanation," *BMJ*, vol. 349, no. January, pp. 1–25, 2015, doi: 10.1136/bmj.g7647.
- [14] M. J. Page et al., "The PRISMA 2020 statement: An updated guideline for reporting systematic reviews," *BMJ*, vol. 372, 2021, doi: 10.1136/bmj.n71.
- [15] S. Moola et al., Chapter 7: Systematic reviews of etiology and risk. 2020.
- [16] K. A. Kechik and C. H. Siar, "Spatial distribution of osteopontin, CD44v6 and podoplanin in the lining epithelium of odontogenic keratocyst, and their biological relevance," *Ann. Diagn. Pathol.*, vol. 32, pp. 17–22, 2018, doi: 10.1016/j.anndiagpath.2017.08.002.
- [17] A. Ono et al., "An immunohistochemical evaluation of BMP-2, -4, osteopontin, osteocalcin and PCNA between ossifying fibromas of the jaws and peripheral cemento-ossifying fibromas on the gingiva," *Oral Oncol.*, vol. 43, no. 4, pp. 339–344, 2007, doi: 10.1016/j.oraloncology.2006.03.017.
- [18] J. Salehinejad et al., "Evaluation of osteopontin and CD44v6 expression in odontogenic cystic lesions by immunohistochemistry," *Pathol. Res. Pract.*, vol. 208, no. 7, pp. 410–414, 2012, doi: 10.1016/j.prp.2012.04.005.
- [19] Y. P. Wang and B. Y. Liu, "High expression of osteopontin and CD44v6 in odontogenic keratocysts," *J. Formos. Med. Assoc.*, vol. 108, no. 4, pp. 286–292, 2009, doi: 10.1016/S0929-6646(09)60068-1.
- [20] M. Wozniak et al., "A comparative study of osteopontin expression, Ki67 index and prognosis in squamous cell carcinoma and cysts of the oral cavity," *Transl. Cancer Res.*, vol. 9, no. 2, pp. 795–808, 2020, doi: 10.21037/tcr.2019.12.08.
- [21] F. Modolo, M. T. Biz, M. T. Martins, S. O. MacHado De Sousa, and N. S. De Araújo, "Expression of extracellular matrix proteins in adenomatoid odontogenic tumor," *J. Oral Pathol. Med.*, vol. 39, no. 3, pp. 230–235, 2010, doi: 10.1111/j.1600-0714.2009.00846.x.
- [22] Y. P. Wang and B. Y. Liu, "Expression of osteopontin and its receptors in ameloblastomas," *Oral Oncol.*, vol. 45, no. 6, pp. 538–542, 2009, doi: 10.1016/j.oraloncology.2008.07.015.
- [23] P. M. Speight and T. Takata, "New tumour entities in the 4th edition of the World Health Organization Classification of Head and Neck tumours: odontogenic and maxillofacial bone tumours," *Virchows Arch.*, vol. 472, no. 3, pp. 331–339, 2018, doi: 10.1007/s00428-017-2182-3.
- [24] F. Modolo, M. T. Biz, M. T. Martins, S. O. MacHado De Sousa, and N. S. De Araújo, "Expression of extracellular matrix proteins in adenomatoid odontogenic tumor," *J. Oral Pathol. Med.*, vol. 39, no. 3, pp. 230–235, 2010, doi: 10.1111/j.1600-0714.2009.00846.x.
- [25] J. Kusuyama et al., "BMP9 prevents induction of osteopontin in JNK-inactivated osteoblasts via Hey1-Id4 interaction," *Int. J. Biochem. Cell Biol.*, vol. 116, no. April, p. 105614, 2019, doi: 10.1016/j.biocel.2019.105614.
- [26] S. A. Lund, C. M. Giachelli, and M. Scatena, "The role of osteopontin in inflammatory processes," *J. Cell Commun. Signal.*, vol. 3, no. 3–4, pp. 311–322, 2009, doi: 10.1007/s12079-009-0068-0.
- [27] Y. Wang et al., "Overexpression of osteopontin induces angiogenesis of endothelial progenitor cells via the $\alpha v\beta 3$ /PI3K/AKT/eNOS/NO signaling pathway in glioma cells," *Eur. J. Cell Biol.*, vol. 90, no. 8, pp. 642–648, 2011, doi: 10.1016/j.ejcb.2011.03.005.
- [28] M. Soluk-Tekkeşin and J. M. Wright, "The world health organization classification of odontogenic lesions: A summary of the changes of the 2017 (4th) edition," *Turk Patoloji Derg.*, vol. 34, no. 1, pp. 1–18, 2018, doi: 10.5146/tjpath.2017.01410.
- [29] Y. Slusarenko da Silva, P. J. W. Stoelinga, R. Grillo, and M. da Graça Naclério-Homem, "Cyst or Tumor? A systematic review and meta-analysis on the expression of p53 marker in Odontogenic Keratocysts," *J. Cranio-Maxillofacial Surg.*, no. xxxx, 2021, doi: 10.1016/j.jcms.2021.09.015.
- [30] B. L. Foster et al., "Osteopontin regulates dentin and alveolar bone development and mineralization," *Bone*, vol. 107, pp. 196–207, 2018, doi: 10.1016/j.bone.2017.12.004.

- [31] B. Depalle, C. M. McGilvery, S. Nobakhti, N. Aldegaither, S. J. Shefelbine, and A. E. Porter, "Osteopontin regulates type I collagen fibril formation in bone tissue," *Acta Biomater.*, vol. 120, pp. 194–202, 2021, doi: 10.1016/j.actbio.2020.04.040.
- [32] P. Y. Wai and P. C. Kuo, "The role of Osteopontin in tumor metastasis," *J. Surg. Res.*, vol. 121, no. 2, pp. 228–241, Oct. 2004, doi: 10.1016/j.jss.2004.03.028.
- [33] H. Rangaswami, A. Bulbule, and G. C. Kundu, "Osteopontin: Role in cell signaling and cancer progression," *Trends Cell Biol.*, vol. 16, no. 2, pp. 79–87, 2006, doi: 10.1016/j.tcb.2005.12.005.
- [34] M. Fatemeh, A. Sepideh, B. S. Sara, and M. Nazanin, "P53 protein expression in dental follicle, dentigerous cyst, odontogenic keratocyst, and inflammatory subtypes of cysts: An immunohistochemical study," *Oman Med. J.*, vol. 32, no. 3, pp. 227–232, 2017, doi: 10.5001/omj.2017.42.
- [35] A. Buchner, "The central (intraosseous) calcifying odontogenic cyst: An analysis of 215 cases," *J. Oral Maxillofac. Surg.*, vol. 49, no. 4, pp. 330–339, 1991, doi: 10.1016/0278-2391(91)90365-S.
- [36] J. A. A. de Arruda et al., "Calcifying odontogenic cyst, dentinogenic ghost cell tumor, and ghost cell odontogenic carcinoma: A systematic review," *J. Oral Pathol. Med.*, vol. 47, no. 8, pp. 721–730, 2018, doi: 10.1111/jop.12727.
- [37] Y. Y. Hong, F. Y. Yu, J. F. Qu, F. Chen, and T. J. Li, "Fibroblasts regulate variable aggressiveness of syndromic keratocystic and non-syndromic odontogenic tumors," *J. Dent. Res.*, vol. 93, no. 9, pp. 904–910, 2014, doi: 10.1177/0022034514542108.
- [38] K. Barrios-Garay, L. F. Agudelo-Sánchez, J. M. Aguirre-Urizar, and C. Gay-Escoda, "Analyses of odontogenic tumours: The most recent classification proposed by the world health organization (2017)," *Med Oral Patol Oral Cir Bucal*, vol. 25, no. 6, pp. e732–e738, 2020, doi: 10.4317/medoral.23751.
- [39] M. A. Icer and M. Gezmen-karadag, "The multiple functions and mechanisms of osteopontin," *Clin. Biochem.*, vol. 59, no. July, pp. 17–24, 2018, doi: 10.1016/j.clinbiochem.2018.07.003.
- [40] D. T. Denhardt and M. Noda, "Osteopontin expression and function: Role in bone remodeling," *J. Cell. Biochem.*, no. SUPPL. 30/31, pp. 92–102, 1998, doi: 10.1002/(sici)1097-4644(1998)72:30/31+<92::aid-jcb13>3.3.co;2-1.
- [41] R. Jia et al., "Osteopontin facilitates tumor metastasis by regulating epithelial–mesenchymal plasticity," *Cell Death Dis.*, vol. 7, no. 12, 2016, doi: 10.1038/cddis.2016.422.
- [42] X. Hou et al., "Osteopontin is a useful predictor of bone metastasis and survival in patients with locally advanced nasopharyngeal carcinoma," *Int. J. Cancer*, vol. 137, no. 7, pp. 1672–1678, 2015, doi: 10.1002/ijc.29540.
- [43] L. A. Shevde, S. Das, D. W. Clark, and R. S. Samant, "Osteopontin: An Effector and an Effect of Tumor Metastasis," *Curr Mol Med*, vol. 10, no. 1, pp. 71–81, 2010, doi: 10.2174/156652410791065381.
- [44] T. E. Kruger, A. H. Miller, A. K. Godwin, and J. Wang, "Bone Sialoprotein and Osteopontin in Bone Metastasis of Osteotropic Cancers," *Crit Rev Oncol Hematol*, vol. 89, no. 2, pp. 330–341, 2014, doi: 10.1016/j.critrevonc.2013.08.013.
- [45] W. Liu and X. Zhang, "Receptor activator of nuclear factor- κ B ligand (RANKL)/RANK/osteoprotegerin system in bone and other tissues (Review)," *Mol. Med. Rep.*, vol. 11, no. 5, pp. 3212–3218, 2015, doi: 10.3892/mmr.2015.3152.
- [46] F. R. Andrade, D. P. Sousa, E. F. Mendonça, T. A. Silva, V. S. Lara, and A. C. Batista, "Expression of bone resorption regulators (RANK, RANKL, and OPG) in odontogenic tumors," *Oral Surgery, Oral Med. Oral Pathol. Oral Radiol. Endodontology*, vol. 106, no. 4, pp. 548–555, 2008, doi: 10.1016/j.tripleo.2008.05.042.
- [47] D. Coppola et al., "Correlation of Osteopontin Protein Expression and Pathological Stage across a Wide Variety of Tumor Histologies," *Clin. Cancer Res.*, vol. 10, no. 1 I, pp. 184–190, 2004, doi: 10.1158/1078-0432.CCR-1405-2

ORIGINALITY REPORT

8%

SIMILARITY INDEX

8%

INTERNET SOURCES

4%

PUBLICATIONS

4%

STUDENT PAPERS

PRIMARY SOURCES

1	www.science.gov Internet Source	2%
2	Submitted to Universitas Airlangga Student Paper	2%
3	www.nice.org.uk Internet Source	2%
4	www.medicinaoral.com Internet Source	2%

Exclude quotes Off

Exclude matches < 2%

Exclude bibliography On