

TURNITIN-HEALING-OF- RADIATION-DERMATITIS

by Ch Nawangsih Prihharsanti

Submission date: 11-May-2023 09:20AM (UTC+0700)

Submission ID: 2090006444

File name: DOC-20221210-WA0028..pdf (714.59K)

Word count: 4880

Character count: 25710

Original Research Report

HEALING OF RADIATION DERMATITIS WITH OZONATED *Aloe vera* OIL BY INCREASING PDGF AND EPIDERMAL THICKNESS IN SPRAGUE-DAWLEY RATS

Widoasti Putri Utami¹, Yan Wisnu Prajoko^{1,2}, Christina Hari Nawangsih Priharsanti^{1,3},
 Udadi Sadhana^{1,4}, Neni Susilaningsih^{1,5}, Maryam Restiwijaya⁶, Muhammad Nur⁶

¹Master Program of Biomedical Science, Faculty of Medicine, Universitas Diponegoro, Semarang, Indonesia

²Department of Surgical Oncology, Faculty of Medicine, Universitas Diponegoro; Dr. Kariadi Central General Hospital, Semarang, Indonesia

³Department of Radiology, Faculty of Medicine, Universitas Diponegoro; Dr. Kariadi Central General Hospital, Semarang, Indonesia

⁴Department of Anatomical Pathology, Faculty of Medicine, Universitas Diponegoro; Dr. Kariadi Central General Hospital, Semarang, Indonesia

⁵Department of Anatomy Histology, Faculty of Medicine, Universitas Diponegoro; Dr. Kariadi Central General Hospital, Semarang, Indonesia

⁶Physics Division, Faculty of Science and Mathematics, Universitas Diponegoro, Semarang, Indonesia

ABSTRACT

The long-term use of corticosteroids as a standard treatment for skin disorders, such as radiation dermatitis, can cause many side effects. Alternatively, ozonated Aloe vera oil may replace corticosteroids due to its fewer side effects and benefits in wound healing process. Re-epithelialization and the formation of growth factors, such as platelet-derived growth factor (PDGF), play an important role in the healing of dermatitis wound. This study intended to demonstrate the effect of ozonated Aloe vera oil to improve the healing of radiation dermatitis wound by increasing PDGF expression and epidermal thickness. This study used a post-test only control group design. A sample of 36 Sprague-Dawley rats was divided into 6 groups (C1=without treatment, C2=2.5% hydrocortisone ointment, P1=pure Aloe vera (AV), P2=300 mg/mL ozonated Aloe vera (OAV), P3=600 mg/mL OAV, P4=1200 mg/mL OAV). The expression of PDGF was assessed using Allred scoring with immunohistochemical staining, whereas the epidermal thickness was assessed using hematoxylin and eosin (H&E) staining at 400x microscopic magnification. The PDGF expression and epidermal thickness between the control and the treatment groups showed significant differences using a Kruskal-Wallis test ($P=0.001$) and one-way ANOVA test ($P<0.001$). The groups that was given ozonated Aloe vera oil had higher average of PDGF expression and thicker epidermis than the other groups. The Spearman's correlation test showed a strong positive relationship ($p<0.001$ and $r=0.709$) between the two variables. In conclusion, ozonated Aloe vera oil improves healing of radiation dermatitis wound by increasing PDGF expression and epidermal thickness.

Keywords: Ozonated Aloe vera; radiation dermatitis; platelet derived growth factor (PDGF); epidermal thickness; biomedics; health risk ; increasing life expectancy

Correspondence: Yan Wisnu Prajoko, Department of Surgical Oncology, Faculty of Medicine, Universitas Diponegoro, RSUP dr. Kariadi Semarang, Indonesia. Email : yanprajoko7519@gmail.com

pISSN:2355-8393 • eISSN: 2599-056x • doi: 10.20473/fmi.v58i4.38234 • Fol Med Indones. 2022;58: 336-342

• Submitted 25 Aug. 2022 • Received 29 Oct 2022 • Accepted 18 Nov 2022 • Published 5 Dec 2022

• Open access under CC-BY-NC-SA license • Available at <https://e-journal.unair.ac.id/FMI/>

INTRODUCTION

Dermatitis is one of the most common skin diseases and has various causes, one of which is radiation exposure (Paramata & Abas 2019). The side effects of ionizing radiation include various disorders, such as skin fibrosis, skin cell aging, skin cell necrosis, and the initiation of epidermal and dermal inflammatory responses (Singh et al. 2016, Robijns & Laubach 2018, Rosenthal et al. 2019). Radiation causes complications, such as delayed wound healing, reduced aesthetic appeal, and decreased quality of life. It was known that

~95% of cancer patients undergoing a radiotherapy have radiation dermatitis (Spalek 2016, Wang et al. 2020). Radiation dermatitis or radiodermatitis is the result of an imbalance of pro-inflammatory and profibrotic cytokines. It decreases the number of growth factors, such as platelet-derived growth factor (PDGF), epidermal growth factor (EGF), transforming growth factor- β (TGF- β), and fibroblast growth factor (FGF) (Han et al. 2020, Vadarli & Angelo-Khattar 2020).



18 Topical corticosteroids are standard drugs commonly used to treat various skin diseases, one of which is radiation dermatitis (Gabros et al. 2022). However, the use of topical corticosteroids in the long term was found to have side effects both locally and systemically. In this era, many alternative drugs have been developed to be used as substitutes with minimal side effects to corticosteroids (Coondoo et al. 2014, Kumar et al. 2019). *Aloe vera* is one of the alternatives for treating various skin diseases (Rao et al. 2017). Its healing properties are related to the compounds it contains, the glucomannan, which can influence fibroblast growth factors, increase cell activity and proliferation, and stimulate collagen production (Hashemi et al. 2015, Vahlepi et al. 2020, Tamba et al. 2020).

Ozone (O₃) is a classic and sterilizing oxidant that is widely applied in clinical practices. Ozone has antimicrobial, antioxidant, immunoregulatory, epigenetic modification, biosynthetic, analgesic, and vasodilatation effects. Ozone therapy in topical preparations can be used as an addition or alternative to the treatment of various types of skin wounds (Anzolin et al. 2020, Zeng et al. 2020).

This study differed from previous studies that used gentamicin ointment as control and ozonated *Aloe vera* oil of 600, 1200, and 1800 mg/mL doses on full thickness wounds (Vahlepi et al. 2020). In this study, ozonated *Aloe vera* was used at doses of 300, 600, and 1200 mg/mL as the treatment groups and 2.5% hydrocortisone ointment as the positive control. The effect of using ozonated *Aloe vera* oil as treatment for radiodermatitis has not been widely studied, while the long-term use of topical corticosteroid has many side effects. Therefore, this study was conducted to investigate the effect of ozonated *Aloe vera* oil in radiation dermatitis wound healing observed from the PDGF expression and epidermal thickness.

16 MATERIALS AND METHODS

This research was an experimental study using a post-test only control group design from August to September 2021. The use of experimental animals in this study complied to the animal ethics approval No. 66/EC/H/FK-UNDIP/VII/2021 obtained from the Health Research Ethics Commission, Faculty of Medicine, Universitas Diponegoro, Semarang, Indonesia. All Sprague-Dawley rats used as the experimental animals were treated and cared for according to animal husbandry standards. External radiation was administered to all experimental animal groups. Radiodermatitis treatment was differentiated by treatment groups.

The experimental animal research subjects were 36 Sprague-Dawley rats divided randomly into 6 groups (6 rats each) consisting of two control groups and four treatment groups. The inclusion criteria for the experimental animals were male rats, aged 2-3 months and weighed 150±50 grams, obtained from the Experimental Animal Laboratory, Universitas Sultan Agung, Semarang. The rats were habituated in individual cages for a week with a 12-hour period of light (06.00 to 18.00) and a 12-hour period of dark (18.00 to 06.00) at a room temperature of 28.0±2.0 °C. Food and water for the rats were given ad libitum. External radiation treatment to create radiation dermatitis wounds on the rats was carried out after acclimatization. In this study, after radiation, three rats died from dehydration.

Radiation dermatitis was created by irradiating a 4x4 cm area on the rats' back with gamma rays. The radiation dose used was 7 Gy in a single dose, which in the calculation of the equipment used is equivalent to 5 minutes. Radiation was administered using a Siemens Primus linear accelerator radiotherapy machine (Concord, CA, USA) at Ken Saras Hospital, Semarang, Indonesia. Prior to the irradiation, the rats were anesthetized with a dose of 80 mg/kgBW Ketamine (Ket-A-100, Peru) and 10 mg/kgBW Xylazine (Xyla, Indonesia) via the intraperitoneal route. After the irradiation, the rats were kept in a clean and warm place with the help of a lamp until they recovered from the effects of anesthetics.

21 The Common Terminology Criteria for Adverse Events (CTCAE version 5.0) from the National Cancer Institution categorizes dermatitis levels into five levels (National Institutes of Health-National Cancer Institute 2017). The severity of radiation dermatitis is very important to note in determining the appropriate management.

Table 1. Dermatitis levels according to the Common Terminology Criteria for Adverse Events (CTCAE version 5.0).

31	
Level 1	Faint erythema or dry desquamation
Level 2	Moderate to sharp erythema; uneven moist desquamation, mostly confined to skin folds and folds; moderate edema
Level 3	Moist desquamation in areas other than skin folds and folds; bleeding caused by minor trauma or abrasion
Level 4	Life-threatening consequences; full thickness skin necrosis and ulceration of the dermis; spontaneous bleeding from the involved site; skin graft indicated
1	
Level 5	Death

The ozonated *Aloe vera* oil was manufactured at the Plasma Research Laboratory of Universitas

Diponegoro. The tools used to produce the ozonated oil were an ozone generator and a magnetic stirrer. The oil was obtained by turning the ozone produced by ozone generator into oil. Potassium iodide titration method was used to measure the ozone levels in the ozonated oil. In this study, ozonated *Aloe vera* was used at 300, 600, and 1200 mg/mL doses.

In this study, the radiation dermatitis had been formed by comparing normal skin tissue and the irradiated skin, where there was a change in skin color, desquamation, amount of PDGF expression, TGF beta, epidermal thickness, and others on the irradiated skin. In this study, dermatitis level 1 occurred in the experimental animals. Ran et al. (2004) stated through their study that gamma ray irradiation of 1-8 Gy can cause radiation wound already in rats.

Ozonated *Aloe vera* oil was applied to the radiation dermatitis wounds twice a day, with 1.045 mL thinly covering the entire wound surface. A previous study applied a variety of an ozonated oil with a dose of 8 microliters on round wounds with a diameter of 3.5 mm (Valacchi et al. 2011). In this study, the diameter of the wound was 40 mm, so the required doses were 313.478 mg/mL, 626.956 mg/mL, and 1253.91 mg/mL which were equivalent to 1.045 mL per application. The interventions were carried out for seven days until the experimental animals were subjected to microscopic and immunohistochemical assessments. The interventions were given based on the division of treatment groups, i.e. C1=no therapy/intervention (negative control) and C2=2.5% hydrocortisone ointment (positive control), P1=*Aloe vera* oil, P2=300 mg/mL ozonated *Aloe vera* (OAV), P3=600 mg/mL OAV, and P4=1200 mg/mL OAV.

Excision was carried out on day 7 for each treatment group. After the Sprague-Dawley rats were terminated by placing them in a closed room and then giving them chloroform inhalation, wound tissue excision process can be carried out. The excision was performed on the widest part of the wound tissue along with the surrounding healthy skin tissue. The process of cutting the tissue was using a microtome by placing it on a paper and fixing it in 10% buffered formalin. It was followed by the immunohistochemical staining and hematoxylin-eosin staining were carried out.

Wound tissue sections (slices) were placed in neutral buffered formalin solution and fixed for 18-24 hours. The tissue fixing agent was removed with distilled water for an hour. The tissue sections were immersed in graded alcohol concentrations (80%, 95%, 95%, absolute alcohol I, II, III) for an hour each and then cleaned.

Tissue preparations were put into paraffin for two hours in an incubator at 56-58°C. Tissues in the paraffin were sectioned to a thickness of 3-6 µm using a microtome and then floated in water at 40°C. Tissue sections were transferred to a microscopic slide and dried overnight at room temperature until they were ready for hematoxylin-eosin staining and PDGF immunohistochemical staining.

PDGF expression assessment

PDGF immunohistochemical staining was performed at the Laboratory of Anatomical Pathology, Universitas Sebelas Maret, Surakarta, Indonesia. PDGF expression readings were performed by an anatomical pathologist at Universitas Diponegoro. Cells in wound tissue expressing the PDGF appeared brown on the immunohistochemical staining. These cells were semi-quantitatively measured using the Allred score by examining the percentage per 100 stained cells and the staining intensity. Then, the average per 100 cells/field was calculated from five fields of view at 400x magnification.

Epidermal thickness assessment

Epidermal thickness measurement was performed by an anatomical pathologist at Universitas Diponegoro. Epidermal thickness was measured from the thickness of the epidermis—from the stratum corneum to the stratum basale in three fields of view using a Nikon microscope with 400x magnification. Then, the mean of the results were calculated. Epidermal thickness was calculated in micrometers (µm) and processed digitally using Indomicro software.

Data analysis

Data analyses, including the descriptive analysis and hypothesis testing, were carried out using the SPSS 21.0 program. In the descriptive analysis, PDGF expression and epidermal thickness were presented in the form of a table of mean and standard deviation (SD). The Shapiro-Wilk test was used to examine the data normality. The Kruskal Wallis test was used to examine the differences in PDGF expression between each group. It turned out that the data were not normally distributed, so it were continued with the post-hoc Mann Whitney test. ANOVA test was used to examine the differences of epidermal thickness between each group because the data were normally distributed. A correlation test between variables was carried out using the Spearman correlation test. The significance limit was $p \leq 0.05$ with a 95% confidence interval.

RESULTS AND DISCUSSION

PDGF expression

Table 1 presents the results of the immunohistochemical analysis of PDGF expression from the Sprague-Dawley rats' dermatitis skin sections.

Table 1. Data normality comparison of the use of hydrocortisone, pure *Aloe vera*, and ozonated *Aloe vera* oil in radiation dermatitis healing based on the Shapiro-Wilk test

Group	N	Mean \pm SD	Median (min-max)	p	Note
C1	5	4.04 \pm 0.50	4.2 (3.2-4.4)	0.090	Normal
C2	5	4.52 \pm 1.06	4.8 (3.0-5.8)	0.913	Normal
P1	5	5.60 \pm 1.02	5.2 (5.0-7.4)	0.007	Abnormal
P2	6	5.73 \pm 0.39	5.9 (5.0-6.0)	0.033	Abnormal
P3	6	6.17 \pm 0.97	5.8 (5.4-8.0)	0.057	Normal
P4	6	6.40 \pm 0.70	6.3 (5.6-7.6)	0.478	Normal

Table 2. Differences of PDGF expression among the use of hydrocortisone pure *Aloe vera* and *Aloe vera* oil in radiation dermatitis healing based on the Kruskal Wallis test

Group	Mean \pm SD	p
C1	4.04 \pm 0.50	0.001
C2	4.52 \pm 1.06	
P1	5.60 \pm 1.02	
P2	5.73 \pm 0.39	
P3	6.17 \pm 0.97	
P4	6.40 \pm 0.70	

Table 3. Significance of the use of hydrocortisone, pure *Aloe vera* and *Aloe vera* oil in radiation dermatitis healing based on post-hoc Mann Whitney test

Group		p
I	II	
C1	C2	0.401
	P1	0.009*
	P2	0.006*
	P3	0.006*
	P4	0.006*
C2	P1	0.113
	P2	0.026*
	P3	0.028*
	P4	0.010*
P1	P2	0.264
	P3	0.081
	P4	0.066
P2	P3	0.681
	P4	0.080
P3	P4	0.329

(*)=significant

These results presented that the groups receiving ozonated *Aloe vera* oil had higher PDGF expression than other groups. These results are consistent with a previous study that wound healing and angiogenesis were better in the groups receiving ozonated oil (Valacchi et al. 2011). The effect of giving ozonated *Aloe vera* oil on PDGF expression was proven to be better than 2.5% hydrocortisone ointment as a positive control. Ozone in the *Aloe vera* oil activates the

collagen synthesis and fibroblast proliferation that help wound healing.

Ozone can assist tissues to be adaptive to oxidative stress, stimulate endogenous antioxidants, and protect against tissue damage. The reaction of polyunsaturated fatty acids and small amounts of water in the upper layer of the dermis will form reactive oxygen species (ROS) and lipo-oligopeptides including H_2O_2 that helps the healing process of wounds (Anzolin et al. 2020). Besides that, the release of endogenous factors, such as PDGF and TGF- β , as well as the re-epithelialization process, were influenced by fibroblast. The content in *Aloe vera* plant shows its effect on wound healing by activating macrophages. In addition, ozonated *Aloe vera* oil can induce the expression of PDGF and TGF- β of epidermal keratinocyte and dermal fibroblast in wound sites (Valacchi et al. 2011, Hashemi et al. 2015, Atik et al. 2019, Zeng et al. 2020, Vahlepi et al. 2020, Tamba et al. 2020). PDGF will transduce its signal through macrophages which will increase the thickness of the dermis and epidermis, thus helps accelerating the wound healing process (Kim et al. 2009, Hashemi et al. 2015, Heldin et al. 2018, Atik et al. 2019, Zeng et al. 2020, Vahlepi et al. 2020, Tamba et al. 2020). *Aloe vera* has fewer side effects than hydrocortisone as a chemical drug. Hydrocortisone has several side effects, including atrophic changes in the skin, infection, ocular changes, pharmacological side effects, and other non-specific side effects (Hengge 2017, Williams 2018).

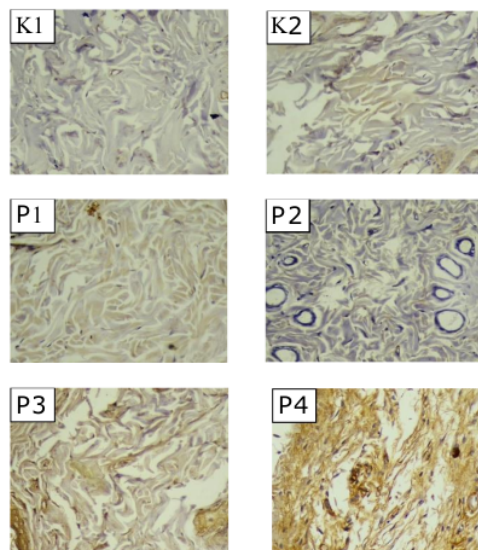


Figure 1. Results of PDGF immunohistochemical staining.

Epidermal thickness

Table 4 presents the results of histological examination using H&E staining that showed the epidermal thickness of wound tissue sections of the experimental animals.

Table 4. Epidermal thickness descriptive data and the Shapiro-Wilk normality test results

Group	N	Mean \pm SD	Median (min-max)	P	Note
C1	5	12.32 \pm 1.71	12.02 (10.69–15.21)	0.164	Normal
C2	5	13.31 \pm 2.38	12.65 (10.15–16.09)	0.707	Normal
P1	5	14.83 \pm 3.43	13.60 (11.85–20.42)	0.287	Normal
P2	6	22.82 \pm 4.18	23.52 (16.17–27.46)	0.756	Normal
P3	6	25.29 \pm 7.97	23.97 (12.70–35.46)	0.573	Normal
P4	6	29.83 \pm 6.64	29.73 (20.67–40.22)	0.990	Normal

Table 5. The result of one-way ANOVA test

Group	Mean \pm SD	p	Levene
C1	12.32 \pm 1.71	<0.001	0.150
C2	13.31 \pm 2.38		
P1	14.83 \pm 3.43		
P2	22.82 \pm 4.18		
P3	25.29 \pm 7.97		
P4	29.83 \pm 6.64		

Table 6. The result of post-hoc least significant difference (LSD) test

Group		P
I	II	
C1	C2	0.762
	P1	0.445
	P2	0.002*
	P3	<0.001*
	P4	<0.001*
C2	P1	0.643
	P2	0.005*
	P3	0.001*
	P4	<0.001*
P1	P2	0.016*
	P3	0.002*
	P4	<0.001*
P2	P3	0.411
	P4	0.025*
P3	P4	0.136

(*)=significant

Table 5 shows that the highest mean of epidermal thickness was found in the group that received 1200 mg/mL ozonated *Aloe vera* oil. This can be due to the role of ozone which has an "oxidative killing" effect on organisms. The greater the amount of ozone, the better it will react to the wound. P2, P3, and P4 groups receiving ozonated *Aloe vera* oil showed that the epithelium appeared thicker than the group without any therapy (negative control), 2.5% hydrocortisone group (positive control), and *Aloe vera* group. This was in accordance with a previous study that ozonated oil can stimulate re-epithelialization better than non-ozonated oil (Valacchi et al. 2011, Kumar et al. 2019, Tamba et al. 2020).

The content in *Aloe vera* can stimulate cell proliferation, increase collagen production, affect fibroblast growth factors, and increase keratinocyte multiplication and migration, so it can help the process of forming new epidermis. This content also plays a role in increasing the occurrence of DNA synthesis and stimulating the binding of epithelial growth factor receptors with ligands, which will activate signals to proliferate reepithelialization (Kumar et al. 2019, Alfiaturohmah et al. 2020, Tamba et al. 2020). Through the process of activation and increased metabolic activity, the amount of epidermal growth factor (EGF) receptor expression will increase. Epidermal closure of the wound tissue will occur more actively, so the re-epithelialization process is faster (Hashemi et al. 2015, Alfiaturohmah et al. 2020).

The wound healing process affected by ozone exposure in wound site can also be seen through its ability in reducing bacterial infections, improving dermal wound healing disorders, and increasing oxygen tension (Kim et al. 2009). Ozone reacts with polyunsaturated fatty acids (PUFAs) to form reactive oxygen species (ROS), such as hydrogen peroxide, by activating redox transcription factors, such as NFkB, which induce growth factor synthesis and accelerate the cell cycle (Kim et al. 2009, Valacchi et al. 2011).

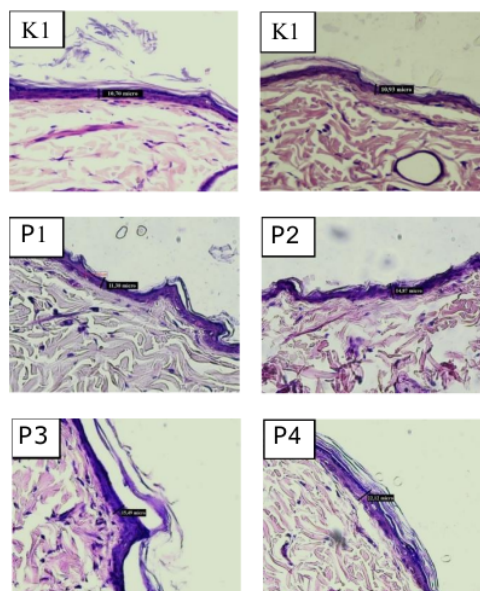


Figure 2. Epidermal thickness by H&E staining of wound tissue in the Sprague-Dawley rats

PDGF and epidermal thickness correlation test

Correlation tests were performed to determine the relationship between the variables, i.e. PDGF expression and epidermal thickness. The results are shown in Table 7 and Table 8.

Table 7. PDGF expression and epidermal thickness descriptive data and the Shapiro-Wilk normality test result

Variable	Mean \pm SD	Median (min-max)	p	Information
PDGF	5.47 \pm 1.13	5.6 (3.0-8.0)	0.623	Normal
Epidermal thickness	20.30 \pm 8.20	19.96 (10.15-40.22)	0.015	Abnormal

The Shapiro-Wilk normality test result (Table 7) showed that the PDGF expression data were normally distributed ($p>0.05$). Data obtained from the epithelial thickness were not normally distributed ($p<0.05$), so the Spearman's Rho correlation test was performed.

Table 8. The Spearman's Rho correlation test of PDGF on epidermal thickness results

Variable	p	r	Information
PDGF			
Epidermal thickness	<0.001	0.709	Significant, positive, strong

The Spearman's Rho correlation test presented $p\leq 0.001$, indicating a significant correlation between PDGF expression and epidermal thickness. The results of this study indicated the direction of strong positive correlation (Table 8).

The glycoproteins contained in *Aloe vera*, as well as the ozone content in ozonated *Aloe vera* oil, can stimulate cell proliferation and increase the expression of epidermal growth factor (EGF), platelet-derived growth factor (PDGF), fibroblast growth factor (FBF), and other growth factors that will stimulate epithelial formation (Hashemi et al. 2015, Atik et al. 2019). PDGF will induce the proliferation and migration of fibroblasts and keratinocytes which can affect the wound healing process by increasing the thickness of the dermis and epidermis (Jacobson et al. 2017). This indicates that the occurrence of keratinocyte cell proliferation may increase or decrease depending on the number and type of growth factors, thus PDGF production leads to more proliferation which accelerates the re-epithelialization process (Kim et al. 2009, Valacchi et al. 2011).

CONCLUSION

Radiation dermatitis, also known as radiodermatitis, happens as a result of skin lesion due to radiation exposure. Ozonated *Aloe vera* can improve PDGF expression and epidermal thickness. Immunohistochemical and histological examinations using H&E staining to assess PDGF expression and epidermal thickness exhibit that topical ozonated *Aloe vera* oil can increase PDGF expression and epidermal thickness in healing of radiation dermatitis wound. The healing of radiation dermatitis wound with topical administration of ozonated *Aloe vera* oil is better than without any therapy and with topical administration of 2.5% hydrocortisone.

The limitations of this study were the equipment used and the high cost, so the radiation beam was administered only once (single dose). Moreover, the cost of immunohistochemical examination was relatively high. This study was expected to be used as the basis for clinical trials of ozonated *Aloe vera* products as wound healing therapy in humans according to evidence-based medicine.

Acknowledgment

I would like to thank Yan Wisnu Prajoko, Christina H. N. Priharsanti as mentors in writing this article. I also would like to thank Muhammad Nur and Resti Wijaya for their comments and suggestion regarding the ozonated *Aloe vera* oil. In addition, I thank the Center for Plasma Research, Universitas Diponegoro for providing this research material and I also thank the Master Program of Biomedical Science, Universitas Diponegoro.

Conflict of interest

The authors declare that there was no conflict of interest regarding publication of this study.

Funding disclosure

This research was funded by the 2021 Research Grant and Community Service (*Hibah Penelitian dan Pengabdian Masyarakat*), Faculty of Medicine, Universitas Diponegoro.

Author contribution

WPU participated in the design of the study, manuscript preparation, and manuscript writing. YWP proposed the main idea, participated in the design of the study, methodology, and supervision. CHNP participated in the idea building and formal analysis. US contributed in the supervision, while NS contributed in the supervision and formal analysis. MR and MN served as the scientific advisors on the *Aloe vera* oil.

REFERENCES

- Alfiaturohmah A, Herbani M, Andriana D (2020). *Efek perasan Aloe vera L. terhadap ketebalan epitel dan kepadatan kolagen pada luka sayat tikus wistar*. J Bio Komplementer Med.
- Anzolin A, da Silveira-Kaross N, Bertol C (2020). Ozonated oil in wound healing: what has already been proven? Med Gas Res 10, 54.
- Atik N, Nandika A, Dewi PIC, et al (2019). Molecular mechanism of *Aloe barbadensis* Miller as a potential herbal medicine. Syst Rev Pharm 10, 118–25.
- Coondoo A, Phiske M, Verma S, et al (2014). Side-effects of topical steroids: A long overdue revisit. Indian Dermatol Online J 5, 416.
- Gabros S, Nessel TA, Zito PM (2022). Topical corticosteroids. StatPearls Publishing, Treasure Island, Florida.
- Han C, Cheng B, Wu P (2020). Clinical guideline on topical growth factors for skin wounds. Burn Trauma.
- Hashemi SA, Madani SA, Abediankenari S (2015). The review on properties of *Aloe vera* in healing of cutaneous wounds. Biomed Res Int 2015, 1–6.
- Heldin C, Lennartsson J, Westermark B (2018). Involvement of platelet-derived growth factor ligands and receptors in tumorigenesis. J Intern Med 283, 16–44.
- Hengge UR (2017). Topical corticosteroids. In Clinical and Basic Immunodermatology, pp. 815–30. Springer International Publishing, Cham.
- Jacobson LK, Johnson MB, Dedhia RD, et al (2017). Impaired wound healing after radiation therapy: A systematic review of pathogenesis and treatment. JPRAS Open 13, 92–105.
- Kim HS, Noh SU, Han YW, et al (2009). Therapeutic effects of topical application of ozone on acute cutaneous wound healing. J Korean Med Sci 24, 368.
- Kumar R, Singh AK, Gupta A, et al (2019). Therapeutic potential of *Aloe vera*—A miracle gift of nature. Phytomedicine 60, 152996.
- National Institutes of Health-National Cancer Institute (2017). Common Terminology Criteria for Adverse Events (CTCAE) version 5.0: U.S. Department of Health and Human Services, National Institutes of Health, National Cancer Institute.
- Paramata NR, Abas NA (2019). *Pengaruh kompres Aloe vera pada penderita dermatitis di wilayah kerja Puskesmas Sumalata Kabupaten Gorontalo Utara*. Jambura Nurs J 1, 19–23.
- Ran X, Cheng T, Shi C, et al (2004). The effects of total-body irradiation on the survival and skin wound healing of rats with combined radiation-wound injury. J Trauma Inj Infect Crit Care 57, 1087–93.
- Rao S, Hegde S, Baliga-Rao M, et al (2017). An *Aloe vera*-based cosmeceutical cream delays and mitigates ionizing radiation-induced dermatitis in head and neck cancer patients undergoing curative radiotherapy: A clinical study. Medicines 4, 44.
- Robijns J, Laubach H-J (2018). Acute and chronic radiodermatitis. J Egypt Women's Dermatologic Soc 15, 2–9.
- Rosenthal A, Israilevich R, Moy R (2019). Management of acute radiation dermatitis: A review of the literature and proposal for treatment algorithm. J Am Acad Dermatol 81, 558–67.
- Singh M, Alavi A, Wong R, et al (2016). Radiodermatitis: A review of our current understanding. Am J Clin Dermatol 17, 277–92.
- Spalek M (2016). Chronic radiation-induced dermatitis: Challenges and solutions. Clin Cosmet Investig Dermatol Volume 9, 473–82.
- Tamba US, Arifin MT, Nur M, et al (2020). The role of ozonated *Aloe vera* oil in full-thickness skin defects: Macrophage count and epithelization length parameter. F1000Research 9, 1218.
- Vadarli G, Angelo-Khattar M (2020). A fibroblast-derived human growth factor preparation for the management of acute radiodermatitis: A case report. Int Med Case Rep J Volume 13, 691–6.
- Vahlepi R, Arifin MT, Nur M, et al (2020). Ozonated *aloe vera* oil improve wound healing by decreasing neutrophil count and wound diameter in Sprague dawley rats with full-thickness skin defect. Indones J Biomed Sci 14, 48.
- Valacchi G, Lim Y, Belmonte G, et al (2011). Ozonated sesame oil enhances cutaneous wound healing in SKH1 mice. Wound Repair Regen 19, 107–15.
- Wang Y, Tu W, Tang Y, et al (2020). Prevention and treatment for radiation-induced skin injury during radiotherapy. Radiat Med Prot 1, 60–8.
- Williams DM (2018). Clinical pharmacology of corticosteroids. Respir Care 63, 655–70.
- Zeng J, Dou J, Gao L, et al (2020). Topical ozone therapy restores microbiome diversity in atopic dermatitis. Int Immunopharmacol 80, 106191.



TURNITIN-HEALING-OF-RADIATION-DERMATITIS

ORIGINALITY REPORT

15%

SIMILARITY INDEX

13%

INTERNET SOURCES

11%

PUBLICATIONS

4%

STUDENT PAPERS

PRIMARY SOURCES

- | | | |
|-------|--|------|
| 1 | <p>Emily C. Milam, Lauren K. Rangel, Miriam K. Pomeranz. "Dermatologic sequelae of breast cancer: From disease, surgery, and radiation", International Journal of Dermatology, 2020</p> <p>Publication</p> | 1 % |
| <hr/> | | |
| 2 | <p>agbiol.org</p> <p>Internet Source</p> | 1 % |
| <hr/> | | |
| 3 | <p>www.frontiersin.org</p> <p>Internet Source</p> | 1 % |
| <hr/> | | |
| 4 | <p>Submitted to West Coast University</p> <p>Student Paper</p> | 1 % |
| <hr/> | | |
| 5 | <p>Ciro Esposito, Vincenzo Coppola, Fulvia Del Conte, Mariapina Cerulo et al. "Evaluation of a New Tubular Finger Oxygen-Enriched Oil Inside-Coated Dressing Device in Pediatric Patients Undergoing Distal Hypospadias Repair: A Prospective Randomized Clinical Trial Part II", Frontiers in Pediatrics, 2021</p> <p>Publication</p> | 1 % |
| <hr/> | | |
| 6 | <p>link.springer.com</p> <p>Internet Source</p> | <1 % |

7	www.mdpi.com Internet Source	<1 %
8	ijbs-udayana.org Internet Source	<1 %
9	github.com Internet Source	<1 %
10	www.ncbi.nlm.nih.gov Internet Source	<1 %
11	Submitted to University of Hull Student Paper	<1 %
12	oatao.univ-toulouse.fr Internet Source	<1 %
13	researcherslinks.com Internet Source	<1 %
14	www.researchsquare.com Internet Source	<1 %
15	Hee Su Kim. "Therapeutic Effects of Topical Application of Ozone on Acute Cutaneous Wound Healing", Journal of Korean Medical Science, 2009 Publication	<1 %
16	repository.ubaya.ac.id Internet Source	<1 %
17	watermark.silverchair.com Internet Source	

<1 %

18

"A Treatise on Topical Corticosteroids in Dermatology", Springer Science and Business Media LLC, 2018

Publication

<1 %

19

mdpi-res.com

Internet Source

<1 %

20

ndl.ethernet.edu.et

Internet Source

<1 %

21

www.minervamedica.it

Internet Source

<1 %

22

Submitted to Universitas Muhammadiyah Surakarta

Student Paper

<1 %

23

ejournal2.litbang.kemkes.go.id

Internet Source

<1 %

24

Campanati, A., S. De Blasio, A. Giuliano, G. Ganzetti, K. Giuliodori, T. Pecora, V. Consales, I. Minnetti, and A. Offidani. "Topical ozonated oil versus hyaluronic gel for the treatment of partial- to full-thickness second-degree burns: A prospective, comparative, single-blind, non-randomised, controlled clinical trial", Burns, 2013.

Publication

<1 %

25	elifesciences.org Internet Source	<1 %
26	er.uwpress.org Internet Source	<1 %
27	download.atlantis-press.com Internet Source	<1 %
28	www.dovepress.com Internet Source	<1 %
29	Conita Yuniarifa, Joko Wahyu Wibowo, Taufiqurrachman Nasihun. "The effect of vitamin C, vitamin E, glutation and zink combination on the number of sertoli and leydig cells: Pre-clinical test in male wistar rats (Rattus norvegicus) exposed to cigarette smoke", AIP Publishing, 2019 Publication	<1 %
30	Lucrezia Zerillo, Immacolata Polvere, Romualdo Varricchio, Jessica Raffaella Madera et al. "Antibiofilm and repair activity of ozonated oil in liposome", Microbial Biotechnology, 2021 Publication	<1 %
31	kluedo.ub.uni-kl.de Internet Source	<1 %
32	www.science.gov Internet Source	<1 %

33	Anuradha Majumdar, Prajakta Sangole. "Chapter 21 Alternative Approaches to Wound Healing", IntechOpen, 2016 Publication	<1 %
----	--	------

34	Hanna Svitina, Roan Swanepoel, Jacques Rossouw, Happiness Netshimbupfe, Chrisna Gouws, Josias Hamman. "Treatment of Skin Disorders with Aloe Materials", Current Pharmaceutical Design, 2019 Publication	<1 %
----	---	------

35	Sainan Wang, Xuyan Sheng, Guibin Huang, Qiuju Li, Yanmei Dong. "Dentin remineralization induced by nanobioactive glass in association with RGDS peptide", Materials Today Communications, 2021 Publication	<1 %
----	---	------

36	docslib.org Internet Source	<1 %
----	--------------------------------	------

37	ijrrjournal.com Internet Source	<1 %
----	------------------------------------	------

38	ipindexing.com Internet Source	<1 %
----	-----------------------------------	------

39	jonuns.com Internet Source	<1 %
----	-------------------------------	------

40	moam.info Internet Source	<1 %
----	------------------------------	------

41	neuroquantology.com Internet Source	<1 %
42	www.researcherslinks.com Internet Source	<1 %
43	www.scielo.br Internet Source	<1 %
44	Bruno B. Loureiro, Paola Juber, Alessandra A. Souza, Edson M. Cezario et al. "The application of highly ozonated sunflower oil does not improve palatal wound healing: a randomized controlled clinical trial", Journal of Periodontology, 2023 Publication	<1 %
45	Ciro Esposito, Fulvia Del Conte, Mariapina Cerulo, Vincenzo Coppola et al. "Evaluation of efficacy of oxygen-enriched oil-based gel dressing in patients who underwent surgical repair of distal hypospadias: a prospective randomised clinical trial", World Journal of Urology, 2020 Publication	<1 %
46	José L. Soriano, Ana C. Calpena, Eliana B. Souto, Beatriz Clares. "Therapy for prevention and treatment of skin ionizing radiation damage: A review", International Journal of Radiation Biology, 2018 Publication	<1 %

Exclude quotes On

Exclude matches Off

Exclude bibliography On

TURNITIN-HEALING-OF-RADIATION-DERMATITIS

GRADEMARK REPORT

FINAL GRADE

/0

GENERAL COMMENTS

Instructor

PAGE 1

PAGE 2

PAGE 3

PAGE 4

PAGE 5

PAGE 6

PAGE 7