

The Effect of Topical Ozonated Aloe vera on VEGF Expression and Microvascular Density in Radiation Dermatitis

by Yan Wisnu Prajoko

Submission date: 12-Apr-2023 08:44PM (UTC+0700)

Submission ID: 2062515524

File name: C7.pdf (893.77K)

Word count: 3968

Character count: 21572



The Effect of Topical Ozonated *Aloe vera* on VEGF Expression and Microvascular Density in Radiation Dermatitis

Yan Wisnu Prajoko^{1*}, Davin Rizky Parulian Silalahi¹, Christina Hari Nawangsih Priharsanti², Tommy Supit³

¹Department of Surgical Oncology, Faculty of Medicine, Universitas Diponegoro, Dr. Kariadi General Hospital, Semarang, Indonesia;

²Department of Radiology, Faculty of Medicine, Universitas Diponegoro, Dr. Kariadi General Hospital, Semarang, Indonesia;

³Department of Surgery, Faculty of Medicine, Universitas Diponegoro, Dr. Kariadi General Hospital, Semarang, Indonesia

Abstract

BACKGROUND: Radiation dermatitis is one of the most common side effects of external radiation therapy. Ozonated *Aloe vera* oil is a novel topical intervention with immunomodulatory properties that have been proven to improve wound healing by promoting fibroblast proliferation and collagen synthesis.

AIM: The purpose of this study was to investigate the effect of topical ozonated *A. vera* oil application on the vascularization aspect of wound healing in a radiation dermatitis animal model.

METHODS: Thirty-six adult male Sprague Dawley rats were randomized into six groups of equal size ($n = 6/\text{group}$): two control and four intervention groups: Positive control (C1) rats were not given any therapy, and comparative control (C2) rats were given topical hydrocortisone cream 2.5%. Subjects in the P1 group were given non-ozonated *A. vera* therapy, P2 group was given 300 mg/mL ozonated *A. vera*, P3 group was given 600 mg/mL ozonated *A. vera*, and P4 was given 1200 mg/mL ozonated *A. vera* therapy. Subject termination and histopathological analyses of vascular endothelial growth factor (VEGF) and microvascular density were carried out after 7 treatment days.

RESULTS: Based on Weidner microvascular density scoring system, the least microvascular density was observed in C2, P3, and P4 (2.0 ± 0.0), followed by P1 (2.1 ± 0.1), P2 (2.9 ± 1.5), and C1 (3.0 ± 0.7). Based on immunoreactive immunoreactive score (IRS) VEGF scoring system, the lowest expression of VEGF was observed in group P3 (4.1 ± 1.1), followed by P4 (4.3 ± 0.8), C2 (4.3 ± 1.3), P1 (5.1 ± 1.0), P2 (5.4 ± 0.6), and C1 (6.5 ± 1.0). There was a strong positive correlation of VEGF and microvascular density.

CONCLUSION: Topical application of ozonated *A. vera* to the radiated skin of Sprague Dawley rats reduced VEGF expression and microvascular density. This anti-inflammatory effect may suggest its potential clinical application.

Edited by: Ksenija Bogoeva-Kostovska
Citation: Prajoko YW, Silalahi DRP, Priharsanti CHN, Supit T. The Effect of Topical Ozonated *Aloe vera* on VEGF Expression and Microvascular Density in Radiation Dermatitis. Open Access Maced J Med Sci. 2022 Mar 14; 10(A):493-497. <https://doi.org/10.3889/oamjms.2022.8319>
Keywords: Ozonated *Aloe vera*; Vascularization; VEGF; Microvascular density; Radiation dermatitis; Wound healing
***Correspondence:** Yan Wisnu Prajoko, Jala n Dokter Sulomo No. 16, Kota Semarang, Jawa Tengah, Indonesia. E-mail: yanprajoko7519@gmail.com
Received: 18-Dec-2021
Revised: 24-Feb-2022
Accepted: 04-Mar-2022
Copyright: © 2022 Yan Wisnu Prajoko, Davin Rizky Parulian Silalahi, Christina Hari Nawangsih Priharsanti, Tommy Supit

Funding: This research did not receive any financial support
Competing Interests: The authors have declared that no competing interests exist
Open Access: This is an open-access article distributed under the terms of the Creative Commons Attribution-NonCommercial 4.0 International License (CC BY-NC 4.0)

Introduction

The most common side effect of external radiation for cancer is radiation dermatitis, especially in patients diagnosed with skin, breast, head, and neck cancer since they are subjected to higher dose of radiation [1], [2]. The severity of radiation dermatitis ranges from faint erythema with mild symptoms, to skin ulceration or necrosis causing major discomfort and morbidity [3]. Major treatment side-effects may ultimately result in worse cancer survival since it affects treatment adherence [4]. Extensive work is being put in creating an effective and well-tolerated radiotherapy through dosing modifications, and application of modern techniques (e.g. intensity-modulated and volumetric-modulated arc radiation therapy) [5]. There are considerable studies and guidelines for maintaining skin health by preventing and treating radiation dermatitis by topical interventions. Numerous topical agents (i.e. silver sulfadiazine, ascorbic acid, allantoin, almond oil, olive oil, dexpanthenol, calendula) have been evaluated, however, the evidence for preventing and reducing the

severity of radiation dermatitis is still limited [6], [7], [8].

Aloe vera is a plant that possess various pharmacological and biochemical properties that have been proven to promote skin wound healing [9], [10], [11]. A novel approach of utilizing *A. vera* is by dissolving ozone with the plant extract creating an enriched compound. Ozone is a triatomic gas molecule that possess potent antimicrobial activity, antioxidative, immunoregulation, epigenetic modification, biosynthesis, analgesic, and vasodilatation. Based on this premise, ozone has been utilized medically in different forms: ozone hydrotherapy, ozone hydrotherapy, and ozonated water or oil for external use [12]. Topical application of ozonated water and oil has been proven to mitigate symptoms such as pruritus and edema [13]. Compared to normal non-ozonated *A. vera*, ozonated *A. vera* (OVA) was observed to promote higher fibroblast recruitment and collagen thickening in a full-thickness wound model [14]. Currently, there is no data regarding the effect of OVA on the vascularization of wound healing. This study aimed to investigate the effect of OVA on vascular endothelial growth factor (VEGF) expression and microvascular density in a radiation dermatitis animal model.

Methods

All experimental subjects used in this study were housed in a certified facility compliant with Medical and Animal Research guideline. Ethical clearance for animal experimentation was acquired from governing ethical committee (No. 107/EC/H/FK-UNDIP/IX/2021).

Experimental subjects

2 months-old, thirty-six male Sprague Dawley rats weighing 150 ± 50 grams were divided into 6 groups. All subjects were fed with standard rat chow *ad libitum* and acclimatized for 2 weeks before the start of the experiments. The six experimental groups were:

- C1 (positive control): radiation with no treatment
- C2 (comparative control): radiation + hydrocortisone acetate 2.5% cream
- P1: radiation + *A. vera* (not ozonated)
- P2: OVA 300 mg/mL
- P3: OVA 600 mg/mL
- P4: OVA 1200 mg/mL.

Radiation dermatitis and topical intervention

The rats were anesthetized using intraperitoneal injection of ketamine-xylazine (ketamine 80 mg/kg, xylazine 10 mg/kg) before radiotherapy. Each rat was laid in prone position to expose the lumbar area measuring 4×4 cm before receiving 7 Gray electron beam radiotherapy from linear accelerator (Siemens Primus™). Radiotherapy was performed by one board-certified radiooncologist. Subjects were returned to their cage after treatment, allowed to regain their consciousness spontaneously before topical intervention the next day. Grade I (NCI CTCAE version 5.0) radiation dermatitis characterized by faint erythema with dry desquamation was consistently observed in all subjects [15]. Different concentrations of OVA and normal *A. vera* oil were obtained from Diponegoro University Plasma Research Center, produced by a method previously described by Hidayat *et al.* [14]. 24 h after radiotherapy, radiation dermatitis was treated using hydrocortisone acetate 2.5% cream, *A. vera* oil, or OVA oil applied topically daily according to the assigned treatment group described above, for 7 consecutive days.

Immunohistological analysis

Euthanasia and tissue explant were conducted after 7 days of topical intervention. Tissue excision was performed on the radiated tissue along with small normal skin along its margin. Explanted tissue was fixated with 10% buffered formalin, trimmed into 3 mm slices, and prepared into paraffin block. Tissue paraffin block were cut into slices of 3 micrometers followed by

VEGF antibody (ThermoFisher™) and hematoxylin and eosin (HE) staining.

Semiquantitative immunoreactive score (IRS) system was used to evaluate the VEGF [16]. Positively stained cells are graded into 5 categories: none = 0; <1% = 1; 1–10% = 2; 11–33% = 3; 34–67% = 4; and more than 67% = 5) and the staining intensity into 3 categories: none = 0; weak = 1; intermediate = 2; and strong = 3. The staining percentage and intensity score were added together to give the final IRS score of 0 to 8. Microvascular density was evaluated and graded based on a scoring system described by Weidner *et al.* [17]. Microvascular density of 0% = 0; <5% = 1; 5–10% = 2; 11–33% = 3; 34–66% = 4; and more than 66% = 5. Qualitative assessment of both the VEGF and microvascular density were taken from three different high power (400×) magnifications field from each sample to be averaged. Immunohistochemical preparation and analyses was conducted by two independent board-certified pathologists.

Statistical analysis

Statistical analysis was performed using SPSS version 22 (IBM Corporation, USA) software. Data normality was conducted using the Shapiro-Wilk test. Based on the abnormally distributed values, the VEGF and microvascular density were analyzed using the Kruskal-Wallis test, followed by Mann-Whitney U tests after a significant main effect is found. Correlation analysis was performed using Spearman's test. A p value of <0.05 was considered to be statistically significant.

Results

Three rats each from the C1, C2, and P1 died post-radiotherapy and were excluded from the analysis. At the end of the study, there were five rats in abovementioned groups. Representative histological appearance HE and VEGF antibody staining showed in Figures 1 and 2. Based on Weidner score, the least microvascular density was observed in C2, P3, and P4 (2.0 ± 0.0), followed by P1 (2.1 ± 0.1), P2 (2.9 ± 1.5), and C1 (3.0 ± 0.7). The highest vascular density was observed in C1-no treatment group with statistically significant differences when compared to all OVA (P1-3) groups. Based on immunoreactive (IRS) score, the lowest expression of VEGF was observed in group P3 (4.1 ± 1.1), followed by P4 (4.3 ± 0.8), C2 (4.3 ± 1.3), P1 (5.1 ± 1.0), P2 (5.4 ± 0.6), and C1 (6.5 ± 1.0). The highest VEGF expression was also observed in the C1-no treatment group. However, the difference was not statistically significant when compared to the OVA (P1-3) groups. The results of

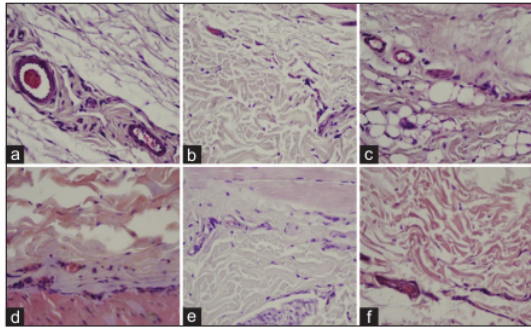


Figure 1: (a-f). Histological analysis of microvascular density. Representative histological appearance of HE stained explants at 400× magnification. (a): C1-positive control, (b): C2-hydrocortisone acetate 2.5%, (c): P1-Aloe vera, (d): P2-Ozonated Aloe vera 300 mg/mL, (e): P3-Ozonated Aloe vera 600 mg/mL, and (f): P4-Ozonated Aloe vera 1200 mg/mL

Spearman’s correlation test showed positive strong relationship between the expression of VEGF and microvascular density (r=0.7, p<0.001). The data mentioned above are presented in Tables 1-3.

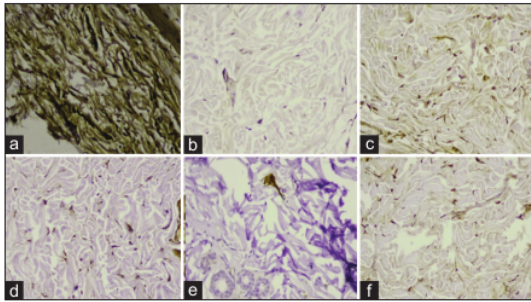


Figure 2: (a-f). Histological analysis of vascular endothelial growth factor (VEGF). Representative histological appearance of HE and VEGF antibody staining at 400× magnification. (a): C1-positive control, (b): C2-hydrocortisone acetate 2.5%, (c): P1-Aloe vera, (d): P2-Ozonated Aloe vera 300 mg/mL, (e): P3-Ozonated Aloe vera 600 mg/mL, and (f): P4-Ozonated Aloe vera 1200 mg/mL

The IRS score graded the VEGF expression from a scale of 0 (minimum) to 8 (maximum) [16]. Weidner score graded the microvascular density from the least to most dense by score 0–5 [17].

Discussion

Wound healing is a well-ordered series of cellular interactions that may be disrupted by repetitive radiation exposure resulting in prolonged inflammation and thus the wound healing. An angiogenic growth factor such as VEGF may promote closure of chronic wounds exhibiting hypoxia and compromised vascularity. It functions as an endothelial cell mitogen, chemotactic agent, and inducer of vascular permeability. The VEGF

Table 1: Histopathological results of tissue vascularity

Treatment group	Microvascular density	VEGF
	Weidner score (mean ± SD)	IRS score (mean ± SD)
C1 - no treatment	3.0 ± 0.7	6.5 ± 1.0
C2 - hydrocortisone	2.0 ± 0.0	4.3 ± 1.3
P1 - Aloe vera	2.1 ± 0.1	5.1 ± 1.0
P2 - OVA 300 mg/dL	2.9 ± 1.5	5.4 ± 0.6
P3 - OVA 600 mg/dL	2.0 ± 0.0	4.1 ± 1.1
P4 - OVA 1200 mg/dL	2.0 ± 0.0	4.3 ± 0.8

SD: Standard deviation, VEGF: Vascular endothelial growth factor, OVA: Ozonated Aloe vera, IRS: Immunoreactive score.

10

is unique for its effects on multiple components of the wound healing cascade, including angiogenesis and recently shown epithelization and collagen deposition [18]. However, high level of VEGF is associated with chronic inflammation. The expression of intercellular adhesion molecule-1 and vascular cell adhesion molecule-1 on the surface of endothelial cells is induced by VEGF production by tumor cells. Leukocyte adherence to endothelial cells is aided by these substances. Hepatocyte growth factor, apparently through suppression of NF-B, can prevent the upregulation of vascular cell adhesion molecule-1 and intercellular adhesion molecule-1 by VEGF in a model of skin inflammation. As a result, VEGF can increase the severity of inflammation by enhancing inflammatory processes. In this experiment, topical application of OVA lowered VEGF expression and microvascular density within the radiated tissue that strongly shows its’ anti-inflammatory effect. In diabetic retinopathy rats, treatment with ozone coloclisis similarly lower the production of VEGF and inflammatory cytokines [19].

Table 2: Comparison of vascularity between treatment groups

Treatment group comparison	Microvascular density (P value)	VEGF (P value)
C1 - no treatment		
C2 - hydrocortisone	0.017*	0.005*
P1 - Aloe vera	0.606	0.093
P2 - OVA 300 mg/dL	0.010*	0.002*
P3 - OVA 600 mg/dL	0.010*	0.004*
P4 - OVA 1200 mg/dL	0.041*	0.002*
C2 - hydrocortisone		
P1 - Aloe vera	0.014*	0.011*
P2 - OVA 300 mg/dL	1.000	0.009*
P3 - OVA 600 mg/dL	1.000	0.140
P4 - OVA 1200 mg/dL	0.361	0.009*
P1 - Aloe vera		
P2 - OVA 300 mg/dL	0.009*	0.034*
P3 - OVA 600 mg/dL	0.009*	0.026*
P4 - OVA 1200 mg/dL	0.045	0.034*
P2 - OVA 300 mg/dL		
P3 - OVA 600 mg/dL	1.000	0.138
P4 - OVA 1200 mg/dL	0.317	1.000
P3 - OVA 600 mg/dL		
P4 - OVA 1200 mg/dL	0.010*	0.138

VEGF: Vascular endothelial growth factor, OVA: Ozonated Aloe Vera, *statistically significant.

Previously, OVA was demonstrated to accelerate the healing process of full-thickness defects by due to the rising in fibroblasts count, collagen thickening, greater macrophage count, and longer epithelialization length [14], [20]. Previous studies have shown that ozone reduces inflammation in dermatitis. The number of inflammatory cells in the epidermal layer

Table 3: Spearman’s correlation test of VEGF expression and microvascular density

VEGF	Vascular Density			p	r
	5–10%	11–33%	34–66%		
5–25%	6	0	0	<0.001*	0.70
26–50%	17	2	0		
51–75%	1	6	0		
>75%	0	0	1		

VEGF: Vascular endothelial growth factor, *statistically significant.

of papular and edematous lesions was significantly reduced in atopic dermatitis lesions with the use of topical ozone. Ozone is a gaseous molecule that may exist in both gas and liquid forms. Ozone has the ability to induce the expression of a variety of cytokines that are necessary for wound healing, as well as antibacterial and antiviral activity. It was shown to promote diabetic ulcer healing by regulating transforming growth factor, and platelet-derived growth factor, and basic fibroblast growth factor [21], [22].

There is still much debate and controversy regarding the appropriate therapeutic dose and its effectiveness because in very low or very high concentrations, it may be useless or bring adverse effects to the individuals. Ozone therapy can when in therapeutic doses, act as a non-toxic "therapeutic shock" to the body because it tends to restore the balance of the redox state through changes in the physiological response, which may be useful in the treatment of metabolic, inflammatory, infectious and neoplastic diseases [23]. In this study, it was observed that greater reduction of vascularization was observed in the 600 and 1200 mg/dL dose; which suggests a dose-dependent results. However, the extend of its effect is comparable to the standard hydrocortisone topical therapy. This opens up the potential use of *A. vera* as an alternative therapy to the standard corticosteroid therapy, since Long-term use of corticosteroids damages and thins the cutaneous later. On the other hand, there are no data regarding the adverse effect of prolonged topical use of *A. vera*.

Our results showed a positive strong relationship between the expression of VEGF and microvascular density. Microvascular Density is associated with angiogenesis and strongly correlated with VEGF [24]. Angiogenesis, or blood vessel growth, is a fundamental phase in wound healing that involves blood vessel endothelial cells responding chemotactically to macrophage-derived substances produced in the wound region. Numerical simulations of the full model reveal the steady propagation of the healing unit through the wound space, the development of a dense band of fine, tipped capillaries near the leading edge of the wound-healing unit (the brush-border effect), and an elevated vessel density associated with newly healed wounds prior to vascular remodeling [25]. Our results showed a decrease in microvascular density on OVA groups compare to control. This was due to the decrease of VEGF expression to reduce inflammatory process during inflammation period on wound healing. This study showed the ability of OVA in reducing VEGF level and microvascular density on wound healing due to radiation therapy. There are several limitations to this study. Other than limited sample size, this study was restricted to an animal model, and only explored a single dose of external radiation. Further studies are required to ensure it save application, ideal therapeutic doses, and a model of repeated radiation therapy to better mimic real clinical application.

Conclusion

In conclusion, 7-day topical applications of 600 to 1200 mg/dL of OVA reduced VEGF and microvascular density within the subcutaneous tissue of externally irradiated Sprague Dawley rats. The extent of this anti-vascularization effect was similar to the standard hydrocortisone therapy; which may suggest OVA's as an alternative treatment for radiation dermatitis.

References

1. Suresha N, Dandekeri S. A clinico-epidemiological study on radiation induced dermatitis of head and neck malignancy patients at a tertiary care centre in south India. *IP Indian J Clin Exp Dermatol*. 2019;5(4):327-31. <https://doi.org/10.18231/ij.ijced.2019.068>
2. Ding J, Guo Y, Li Q, Chen J, Hu P, Liu Q, *et al*. The incidence of postoperative radiotherapy-induced acute dermatitis in breast cancer and its influencing factors for Chinese women. *Onco Targets Ther*. 2018;11:1665-70.
3. Hymes SR, Strom EA, Fife C. Radiation dermatitis: Clinical presentation, pathophysiology, and treatment 2006. *J Am Acad Dermatol*. 2006;54(1):28-46. <https://doi.org/10.1016/j.jaad.2005.08.054>
PMid:16384753
4. Dilalla V, Chaput G, Williams T, Sultanem K. Radiotherapy side effects: Integrating a survivorship clinical lens to better serve patients. *Curr Oncol*. 2020;27(2):107-12. <https://doi.org/10.3747/co.27.6233>
PMid:32489253
5. Iacovelli NA, Galaverni M, Cavallo A, Naimo S, Facchinetti N, Iotti C, *et al*. Prevention and treatment of radiation-induced acute dermatitis in head and neck cancer patients: A systematic review. *Future Oncol*. 2018;14(3):291-305. <https://doi.org/10.2217/fon-2017-0359>
PMid:29153015
6. McQuestion M. Evidence-based skin care management in radiation therapy: Clinical update. *Semin Oncol Nurs*. 2011;27(2):e1-17. <https://doi.org/10.1016/j.soncn.2011.02.009>
PMid:21514477
7. Salvo N, Barnes E, van Draanen J, Stacey E, Mitera G, Breen D, *et al*. Prophylaxis and management of acute radiation-induced skin reactions: A systematic review of the literature. *Curr Oncol*. 2010;17(4):94-112. <https://doi.org/10.3747/co.v17i4.493>
PMid:20697521
8. Wong RKS, Bensadoun RJ, Boers-Doets CB, Bryce J, Chan A, Epstein JB, *et al*. Clinical practice guidelines for the prevention and treatment of acute and late radiation reactions from the MASCC skin toxicity study Group. *Supportive Care in Cancer*. 2013;21(10):2933-48. <https://doi.org/10.1007/s00520-013-1896-2>
PMid:23942595
9. Haddad P, Amouzgar-Hashemi F, Samsami S, Chinichian S, Oghabian MA. *Aloe vera* for prevention of radiation-induced dermatitis: A self-controlled clinical trial. *Curr Oncol*. 2013;20(4):e345-8. <https://doi.org/10.3747/co.20.1356>
PMid:23904773
10. Liang J, Cui L, Li J, Guan S, Zhang K, Li J. *Aloe vera*: A medicinal plant used in skin wound healing. *Tissue Eng Part B Rev*.

- 2021;27(5):455-74. <https://doi.org/10.1089/ten.TEB.2020.0236>
PMid:33066720
11. Hekmatpou D, Mehrabi F, Rahzani K, Aminiyan A. The effect of aloe vera clinical trials on prevention and healing of skin wound: A systematic review. *Iran J Med Sci.* 2019;44(1):1-9. PMid:30666070
 12. Zeng J, Lu J. Mechanisms of action involved in ozone-therapy in skin diseases. *Int Immunopharmacol.* 2018;56:235-41. <https://doi.org/10.1016/j.intimp.2018.01.040>
PMid:29414657
 13. Sagai M, Bocci V. Mechanisms of action involved in ozone therapy: Is healing induced via a mild oxidative stress? *Med Gas Res.* 2011;1:29. <https://doi.org/10.1186/2045-9912-1-29>
PMid:22185664
 14. Hidayat AT, Arifin MT, Nur M, Muniroh M, Susilaningsih N. Ozonated *Aloe vera* oil effectively increased the number of fibroblasts and collagen thickening in the healing response of full-thickness skin defects. *Int J Inflamm.* 2021;2021:6654343. <https://doi.org/10.1155/2021/6654343>
PMid:33628417
 15. Cancer Institute N. Common Terminology Criteria for Adverse Events (CTCAE) Common Terminology Criteria for Adverse Events (CTCAE) v5.0. 2017. Available from: <https://www.meddra.org> [Last accessed on 2022 Jan 27].
 16. Cvetkovic D, Movsas B, Dicker AP, Harlan AL, Greenberg RE, Chapman JD, et al. Increased hypoxia correlates with increased expression of the angiogenesis marker vascular endothelial growth factor in human prostate cancer. *Urology.* 2001;57(4):821-5. [https://doi.org/10.1016/s0090-4295\(00\)01044-x](https://doi.org/10.1016/s0090-4295(00)01044-x)
PMid:11306422
 17. Weidner N. Current pathologic methods for measuring intratumoral microvessel density within breast carcinoma and other solid tumors. *Breast Cancer Res Treat.* 1995;36(2):169-80. <https://doi.org/10.1007/BF00666038>
PMid:8534865
 18. Bao P, Kodra A, Tomic-Canic M, Golinko MS, Ehrlich HP, Brem H. The role of vascular endothelial growth factor in wound healing. *J Surg Res.* 2009;153(2):347-58. <https://doi.org/10.1016/j.jss.2008.04.023>
PMid:19027922
 19. Xie TY, Yan W, Lou J, Chen XY. Effect of ozone on vascular endothelial growth factor (VEGF) and related inflammatory cytokines in rats with diabetic retinopathy. *Genet Mol Res.* 2016;15:15027558. <https://doi.org/10.4238/gmr.15027558>
PMid:27323014
 20. Tamba US, Arifin MT, Nur M, Muniroh M, Susilaningsih N. The role of ozonated *Aloe vera* oil in full-thickness skin defects: Macrophage count and epithelization length parameter. *F1000Research.* 2020;9:1218. <https://doi.org/10.12688/f1000research.25063.1>
 21. Taşdemir Z, Alkan BA, Albayrak H. Effects of ozone therapy on the early healing period of deepithelialized gingival grafts: A randomized placebo-controlled clinical trial. *J Periodontol.* 2016;87(6):663-71. <https://doi.org/10.1902/jop.2016.150217>
PMid:26777769
 22. Moon EJ, Lee YM, Lee OH, Lee MJ, Lee SK, Chung MH, et al. A novel angiogenic factor derived from *Aloe vera* gel: β -sitosterol, a plant sterol. *Angiogenesis.* 1999;3(2):117-23. <https://doi.org/10.1023/a:1009058232389>
PMid:14517429
 23. Bocci VA. Scientific and medical aspects of ozone therapy. *State of the art. Arch Med Res.* 2006;37(4):425-35. <https://doi.org/10.1016/j.arcmed.2005.08.006>
PMid:16624639
 24. Chand R, Chandra H, Chandra S, Verma SK. Role of microvessel density and vascular endothelial growth factor in angiogenesis of hematological malignancies. *Bone Marrow Res.* 2016;2016:5043483. PMid:26998362
 25. Pettet GJ, Byrne HM, Mcelwain DL, Norbury J. A model of wound-healing angiogenesis in soft tissue. *Math Biosci.* 1996;135(1):35-63. [https://doi.org/10.1016/0025-5564\(96\)00044-2](https://doi.org/10.1016/0025-5564(96)00044-2)
PMid:8755336

The Effect of Topical Ozonated Aloe vera on VEGF Expression and Microvascular Density in Radiation Dermatitis

ORIGINALITY REPORT

24%

SIMILARITY INDEX

20%

INTERNET SOURCES

22%

PUBLICATIONS

7%

STUDENT PAPERS

PRIMARY SOURCES

1	smiledesigncenter.us Internet Source	3%
2	coek.info Internet Source	2%
3	repository.medri.uniri.hr Internet Source	2%
4	Yenny Salmah, Harun Achmad, Bayu Indra Sukmana, Ummi Wajdiyah, Nirwana Dachlan, Zia Nurul Zahbia, En Nadia, Try Diana Utamy. "The Effect of Periapical Radiography X-Ray Radiation on the Number of Leukocytes in Mice (Mus musculus)", Open Access Macedonian Journal of Medical Sciences, 2022 Publication	1%
5	balimedicaljournal.org Internet Source	1%
6	www.thieme-connect.de Internet Source	1%

7

Dusica Cvetkovic, Benjamin Movsas, Adam P Dicker, Alexandra L Hanlon et al. "Increased hypoxia correlates with increased expression of the angiogenesis marker vascular endothelial growth factor in human prostate cancer", *Urology*, 2001

Publication

1 %

8

Ahsanu Taqwim Hidayat, Muhamad Thoar Arifin, Muhammad Nur, Muflihatul Muniroh, Neni Susilaningih. "Ozonated Aloe vera Oil Effective Increased the Number of Fibroblasts and Collagen Thickening in the Healing Response of Full-Thickness Skin Defects", *International Journal of Inflammation*, 2021

Publication

1 %

9

www.berlmathges.de

Internet Source

1 %

10

alexandriadentaljournal.com

Internet Source

1 %

11

Submitted to University of Mosul

Student Paper

1 %

12

Dorota Kiprian, Agata Szykut-Badaczewska, Agnieszka Gradzińska, Joanna Czuwara, Lidia Rudnicka. "How to manage radiation-induced dermatitis?", *Nowotwory. Journal of Oncology*, 2022

Publication

1 %

13	www.atlantis-press.com Internet Source	1 %
14	Submitted to Universitas Sebelas Maret Student Paper	1 %
15	brieflands.com Internet Source	<1 %
16	Suhartini Suhartini, Atjo Wahyu, Apik Indarty. "The Effect of Participatory Ergonomic on Fatigue Disorders of Workers in PT. Industri Kapal Indonesia (Persero)", Open Access Macedonian Journal of Medical Sciences, 2022 Publication	<1 %
17	garuda.kemdikbud.go.id Internet Source	<1 %
18	ijbms.mums.ac.ir Internet Source	<1 %
19	www.science.gov Internet Source	<1 %
20	YUNG-SHUO KAO, KEVIN SHENG-KAI MA, MIN-YOU WU, YAO-CHENG WU, YU-KANG TU, CHENG-HSIEN HUNG. "Topical Prevention of Radiation Dermatitis in Head and Neck Cancer Patients: A Network Meta-analysis", In Vivo, 2022 Publication	<1 %

www.ncbi.nlm.nih.gov

21

Internet Source

<1 %

22

bmcoralhealth.biomedcentral.com

Internet Source

<1 %

23

diagnosticpathology.biomedcentral.com

Internet Source

<1 %

24

Yoon Dong Kim. "Correlation between Prostate Volume and Metabolic or Anthropometric Factors in Male Visitors to a Health Promotion Center", Korean Journal of Urology, 2008

Publication

<1 %

25

www.uptodate.com

Internet Source

<1 %

26

Ashraf Shoma, Waleed Eldars, Nashat Noman, Mohamed Saad et al. "Pentoxifylline and Local Honey for Radiation-Induced Burn Following Breast Conservative Surgery", Current Clinical Pharmacology, 2010

Publication

<1 %

27

Mark Rippon, Angie Perrin, Richard Darwood, Karen Ousey. "The potential benefits of using aloe vera in stoma patient skin care", British Journal of Nursing, 2017

Publication

<1 %

28

bmccomplementmedtherapies.biomedcentral.com

Internet Source

<1 %

29

[f1000research.com](https://www.f1000research.com)

Internet Source

<1 %

30

translational-medicine.biomedcentral.com

Internet Source

<1 %

31

ueaeprints.uea.ac.uk

Internet Source

<1 %

32

Aleksandra Palatyńska-Ulatowska, Marta Michalska, Anna Drelich, Aleksandra Sałagacka-Kubiak et al. "Systemic Antibiotic and Nonsteroidal Anti-Inflammatory Drug Treatment Decreases the Level of Endogenous Angiogenic Vascular Endothelial Growth Factor in Inflamed Human Periapical Tissues", Applied Sciences, 2021

Publication

<1 %

33

Júlia dos Santos Vianna Néri, Erielma Lomba, Alexandre Melo Karam, Silvia Regina de Almeida Reis et al. "Ozone therapy influence in the tissue repair process: A literature review", JORDI - Journal of Oral Diagnosis, 2017

Publication

<1 %

34

T El Hady, S Karam, A El Sawa, N Saad. "EXPRESSION OF VASCULAR ENDOTHELIAL GROWTH FACTOR DURING HEALING OF EXTRACTION SOCKETS IN DIABETIC RATS", Alexandria Dental Journal, 2015

<1 %

35

Alaadin Naji, Saman SarKo, Sama Atta. "Current Sites of Infections and Types of Microorganisms in Patient with Febrile Neutropenia in Hematological Wards – Single Center Study", Open Access Macedonian Journal of Medical Sciences, 2022

Publication

<1 %

36

Hamidreza Mehdizadeh, Sami I. Somo, Elif S. Bayrak, Eric M. Brey, Ali Cinar. "Design of Polymer Scaffolds for Tissue Engineering Applications", Industrial & Engineering Chemistry Research, 2015

Publication

<1 %

37

Shirin Nour, Rana Imani, G. Rasul Chaudhry, Ali Mohammad Sharifi. "Skin wound healing assisted by angiogenic targeted tissue engineering: A comprehensive review of bioengineered approaches", Journal of Biomedical Materials Research Part A, 2020

Publication

<1 %

Exclude quotes On

Exclude matches Off

Exclude bibliography On

The Effect of Topical Ozonated Aloe vera on VEGF Expression and Microvascular Density in Radiation Dermatitis

GRADEMARK REPORT

FINAL GRADE

/0

GENERAL COMMENTS

Instructor

PAGE 1

PAGE 2

PAGE 3

PAGE 4

PAGE 5
