

# TOPICAL OZONATED ALOE VERA REDUCE THE INFLAMMATION IN RADIATION DERMATITIS

Dimas Susilo Waridiarto<sup>1</sup>, Yan Wisnu Prajoko<sup>2\*</sup>, C.H. Nawangsih Priharsanti<sup>3</sup>, Udadi Sadhana<sup>4</sup>, Neni Susilaningsih<sup>5</sup>

General Surgery Resident, Faculty of Medicine Diponegoro University / Kariadi Central Hospital, Semarang, Indonesia<sup>1</sup>

Surgical Oncology Division, Surgery Department, Faculty of Medicine Diponegoro University / Kariadi Central Hospital, Semarang, Indonesia<sup>2</sup>

Oncology Radiology Division, Radiology Department, Faculty of Medicine Diponegoro University / Kariadi Central Hospital, Semarang, Indonesia<sup>3</sup>

Anatomic Pathology Department, Faculty of Medicine Diponegoro University / Kariadi Central Hospital, Semarang, Indonesia<sup>4</sup>

Biomedic Department, Faculty of Medicine Diponegoro University, Semarang, Indonesia<sup>5</sup>

Corresponding Author: 2\*



---

**Keywords:**

radiation dermatitis, ozonated aloe vera, TNF- $\alpha$  expression

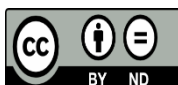---

---

**ABSTRACT**

Radiation dermatitis is a side effect is the most common side effect of external radiation with varied clinical features. Applying topical ozonated aloe vera can reduce the inflammatory reaction in radiation dermatitis by decreasing neutrophil migration and TNF- $\alpha$  expression. This study aims to improve the healing response of radiation dermatitis with ozonated aloe vera therapy based on TNF- $\alpha$  face and the ratio of neutrophils to lymphocytes. Experimental study with post-test only randomized control group design on 36 male *Sprague Dawley* rats weighing 150 $\pm$ 50 grams and given a single dose of 7 Gy radiation. After radiation, acclimatization was carried out for seven days and followed by randomization and divided into six groups, namely negative control, positive control given hydrocortisone cream 2.5%, treatment groups 1, 2, 3, and 4 were given aloe vera, aloe vera, respectively ozonated doses of 300 mg/mL, 600 mg/ml, and 1200 mg/mL for seven days. After the treatment, the rats were terminated, and histological preparations were made with HE staining and immunohistochemistry to see the NL ratio and TNF- $\alpha$ . Three rats were dead on external radiation administration. In the Kruskal-Wallis test, there were significant differences in the NL ratio and TNF- $\alpha$  expression based on the type of treatment ( $p < 0.05$ ). In the Mann-Whitney test, there were significant differences between treatment groups ( $p < 0.05$ ). Ozonated aloe vera increases radiation dermatitis's healing response in *Sprague Dawley* rats by decreasing TNF- $\alpha$  expression and neutrophil-lymphocyte ratio.

---



This work is licensed under a Creative Commons Attribution Non-Commercial 4.0 International License.

---

## 1. INTRODUCTION

Radiation dermatitis is the most common side effect and presented in up to 95% of patients after external radiation administration [1]. The clinical feature of radiation dermatitis varies from skin reactions such as mild erythema and desquamation to skin necrosis. In chronic conditions, lesions appear in the form of skin atrophy and telangiectasis [2- 4]. Incidence and severity vary depending on extrinsic factors such as the type of radiation such as local and locoregional, radiation dose, and the area of radiation administration [5], [6].

Skin is an organ that is constantly dividing. The layer that contains keratinocytes and melanocytes is radiosensitive. Hence radiation exposure can affect the cell division cycle. Repeated radiation exposure led to decreased time for cell repair and increased cell injury [2], [3]. Cell damage after radiotherapy causes changes in the cell cycle, cytokine production, and DNA damage. In the early phase of inflammation, proinflammatory cytokines appear, such as IL-1, IL-3, IL-5, IL-6, and Tumor Necrosis Factor- $\alpha$  (TNF- $\alpha$ ), which cause infiltration eosinophils and neutrophils so that the tissue damage is getting worse. Excessive inflammatory cell response can interfere with wound healing due to disruption of granulation tissue formation, fibrogenesis, and angiogenesis [1], [4], [6], [7].

Aloe vera is widely used as a topical therapy for skin tissue inflammation due to its anti-inflammatory and antioxidant properties. The mechanism of cyclooxygenase inhibition and pro-inflammatory cytokines, thereby reducing neutrophil infiltration and the ability to reduce platelet aggregation, leads to repairment of tissue inflammation and acceleration of wound healing [8]. Ozonated aloe vera has a remarkable effect because it can provide oxygen and regulate antioxidant enzymes to protect against oxidative reactions and increase healing factors [9- 12]. Administration of topical ozonated aloe vera aid the regulation of wound healing without causing toxic effects because the ozone acts immediately with fat in the stratum corneum layer of the skin and is absorbed as an antioxidant through the skin, [9]

Topical ozonated aloe vera provides significant benefits in cancer patients with radiation dermatitis [13]. Therefore, the authors tried to elaborate an increased healing response of radiation dermatitis based on TNF- $\alpha$  expression and the neutrophils lymphocytes ratio in Sprague Dawley rats treated with ozonated aloe vera therapy compared to no treatment and 25% hydrocortisone cream.

## 2. METHODS

This was an experimental study with a post-test-only control group design. The 36 male Sprague Dawley rats from the Experimental Animal Laboratory, Sultan Agung University, Semarang, aged 2-3 months, weighing  $150 \pm 50$  grams, were acclimatized for a week. Rats with physical abnormalities appearing inactive and dead were excluded from the study. The rats were anesthetized intraperitoneally using a mixture of ketamine 80 mg/kg BW and xylazine 10 mg/kg BW. They received 7 Gray electron beam radiotherapy from a linear accelerator (Siemens Primus<sup>TM</sup>) on the 4x4 cm area of the back of the rats. Ozonated aloe vera was obtained from the Plasma Research Laboratory of Diponegoro University. The rats were randomly divided into six groups consisting of 6 rats in each group and treated with:

- i. C1 (Negative control): radiation without therapy
- ii. C2 (Positive control): radiation + topical hydrocortisone 2,5%
- iii. T1; radiation + topical aloe vera
- iv. T2; Radiation + 300 mg/mL of ozonated aloe vera
- v. T3; radiation + 600 mg/mL of ozonated aloe vera
- vi. T4; radiation + 1200 mg/mL of ozonated aloe vera

After seven days of treatment, the rats were then terminated. The wound tissue was incised; then histological preparations were made. The staining was performed using hematoxylin-eosin (HE) to see the ratio of neutrophils and lymphocytes and immunohistochemical staining to see the expression of TNF- $\alpha$  (Figure 1). The assessment of TNF- $\alpha$  was conducted using the Allred score (Table 1). The Faculty of Medicine Universitas Diponegoro Health Research Ethics Committee approved this study (No. 70/EC/H/FK-UNDIP/VII/2021).

Data analysis includes descriptive analysis and hypothesis testing. In the descriptive analysis, the dependent variable is presented in the form of a table of mean, SD, median, and box plot graphs. The hypothesis was tested using the Kruskal Wallis Non-Parametric test, followed by the Mann-Whitney test to determine the differences between groups. It was considered significant if  $p < 0.05$  with a 95% confidence interval.

### 3. RESULTS

Three of the 36 rats given radiation died, leaving 33 rats. The rats were then randomly divided into six groups, namely 5 in the NCG, PCG, and T1 groups and 6 in the T2, T3, and T4 groups. After seven days of treatment, termination was carried out and continued with histopathological examination for the total neutrophil-lymphocyte ratio and TNF $\alpha$  expression. In HE staining, the lowest number of NL ratios was found in the PCG group ( $1.15 \pm 0.77$ ), followed by the treatment group, which was given ozonated aloe vera at a dose of 600 mg/ml, 300 mg/ml, 1200 mg/ml, aloe vera and the lowest ( $0.02 \pm 0.04$ ) in PCG (Figure 2).

In the Kruskal Wallis test, there was a significant difference in the NL ratio based on the type of treatment with  $p < 0.05$ . The Mann-Whitney test was performed to determine the differences between the treatment groups. Based on the Mann-Whitney test, there were significant differences between the treatment and control groups, except in the PCG and T2 groups, where the differences were not significant ( $p = 0.072$ ,  $p < 0.05$ ) (Table 2).

In histopathological examination with immunohistochemical staining, TNF- $\alpha$  expression was measured using the Allred score, and the result obtained was a decrease in TNF- $\alpha$  expression (Figure 3). The results of statistical analysis with the Kruskal Wallis test obtained a  $p$ -value  $< 0.05$ , so it can be concluded that there is a significant difference in TNF- $\alpha$  based on the type of treatment, with the highest TNF- $\alpha$  average ( $6.76 \pm 0.41$ ) in NCG and the lowest TNF- $\alpha$  average ( $3.72 \pm 1.13$ ) in the PCG group (Figure 4). Mann Whitney test was performed to determine differences between treatment groups. From the results of the Mann Whitney test, the difference between the P2 and P3 groups was not significant ( $P = 0.935$ ,  $p < 0.05$ ), while between other treatment groups, significant differences were obtained (Table 2).

### 4. DISCUSSION

Radiation dermatitis occurs due to the inflammatory response and oxidative stress reactions that cause cell damage, causing changes in proinflammatory cytokines, cell cycle changes, and DNA damage. One of the proinflammatory cytokines that appear in the early phase of inflammation is TNF- $\alpha$  due to macrophage activation [1], [4], [6], [7]. A significant increase in TNF- $\alpha$  has indicated the cardinal signs of inflammation in heat, pain, swelling, and redness. TNF- $\alpha$  enhances and prolongs the inflammatory process by activating pro-inflammatory cytokines and other mediators such as nitric oxide and reactive oxygen species (ROS) that cause continued inflammation and tissue injury [14]. When inflammation occurs, neutrophils migrate to the site of tissue damage by chemotaxis. Neutrophils are recruited in large numbers to phagocytize debris. They are the body's first line of defense against infection, including ROS [15]. Neutrophils play a role in amplifying inflammation in the early stages of healing and providing signals in the late stages of healing against inflammation. Continued recruitment of neutrophils or the accumulation of apoptotic neutrophils that are

unregulated by macrophages can prolong inflammation and contribute to the development of chronic inflammation [10].

The effect of ozone in this study was reviewed by looking at the amount of TNF- and the NL ratio in adult male Sprague Dawley with radiation dermatitis. The healing phase of the inflammatory process is usually marked by a decrease in the Allred score, [16], and a reduction in the recruitment of neutrophils to tissues. A high NL ratio can indicate tissue damage and can be used to evaluate the excitatory and inhibitory activity of the immune system in the healing phase of inflammation [17].

Based on previous research, ozone content can reduce inflammation in dermatitis. The use of topical ozone in atopic dermatitis lesions significantly reduced the number of inflammatory cells in the epidermal layer of papular lesions and edema in atopic dermatitis [18]. The results of data analysis between the negative control group compared the group given ozonated aloe vera at doses of 300 mg/ml and 600 mg/ml found a significant difference. Meanwhile, there was an excess dose in the administration of ozonated aloe vera at 1200 mg/ml, so the anti-inflammatory effect was ineffective. The results of this study are in line with the research of [10] where the administration of ozonated aloe vera on open wounds of Sprague Dawley rats showed wound healing in the form of a decrease in the number of neutrophils compared to the negative control group.

Ozone influences wound healing, a multiphase process consisting of four phases: hemostasis, inflammation, proliferation, and remodeling [19]. This effect occurs because of an immunoregulatory mechanism, which improves local perfusion and oxygen diffusion, antioxidant defense, and epigenetic modification [11], [18]. Increased oxygen perfusion at the wound site can increase granulation tissue formation, increasing the speed of wound closure [20]. A high neutrophil count in the area around the wound indicates that inflammation is still active. Neutrophils will produce TNF- $\alpha$  and IL-6, pro-inflammatory cytokines, so inflammation will continue to occur [21]. A decrease in the number of neutrophils in the area around the wound indicates an inhibition of the body's immune system to reduce the inflammatory reaction and suggests that wound healing has started. The decrease in neutrophils will impact the amount of TNF- $\alpha$  around the wound, reducing the inflammatory process, so wound healing occurs.

Our study showed that ozonated aloe vera exhibit a wound-healing effect on radiation dermatitis by reducing TNF- $\alpha$  expression and NLR ratio following a single radiation exposure on the skin. However, our study was only conducted with single radiation exposure and measured on a single-time event. Further study regarding the long-term effect on a more extended evaluation period would be beneficial.

## 5. CONCLUSION

Ozonated aloe vera increases radiation dermatitis's healing response in Sprague Dawley rats by decreasing TNF- $\alpha$  expression and neutrophil-lymphocyte ratio.

## DECLARATION

### Ethics approval

Ethics was obtained from the Ethical Commission for Health Research, Faculty of Medicine, Diponegoro University with the Ethical Clearance number No. 70 / EC / H / FK.UNDIP / VII / 2021. All experimental animals had been cared and managed accordingly to animal maintenance standards

### Consent for publication

Not applicable

#### Availability of data and material

The datasets used and/or analysed during the current study are available from the corresponding author on reasonable request.

#### Competing interests

All authors report no competing interest

#### Funding

This study was funded by Faculty of Medicine, Universitas Diponegoro

#### Acknowledgment

The authors would like to thank the Experimental Animal Laboratory at Sultan Agung University and Ken Saras Hospital for providing the necessary facilities and instruments for the duration of the study

### 6. REFERENCES

- [1] Khanna N, Kumar D, Laskar S, Laskar S. Radiation dermatitis: An overview. *Indian Journal of Burns*. 2013;21(1):24-31.
- [2] Suresha N, Dandekeri S. A clinical-epidemiological study on radiation-induced dermatitis of head and neck malignancy patients at a tertiary care centre in South India. 2019.
- [3] Ding J, Guo Y, Li Q, Chen J, Hu P, Liu Q, et al. The incidence of postoperative radiotherapy-induced acute dermatitis in breast cancer and its influencing factors for Chinese women. *Onco Targets Ther*. 2018;11:1665-70.
- [4] Wei J, Meng L, Hou X, Qu C, Wang B, Xin Y, et al. Radiation-induced skin reactions: mechanism and treatment. *Cancer Manag Res*. 2018;11:167-77.
- [5] Iacovelli NA, Galaverni M, Cavallo A, Naimo S, Facchinetti N, Iotti C, et al. Prevention and treatment of radiation-induced acute dermatitis in head and neck cancer patients: a systematic review. *Future Oncol*. 2018;14(3):291-305.
- [6] Dilalla V, Chaput G, Williams T, Sultanem K. Radiotherapy side effects: integrating a survivorship clinical lens to better serve patients. *Curr Oncol*. 2020;27(2):107-12.
- [7] Kabashima K, Honda T, Ginhoux F, Egawa G. The immunological anatomy of the skin. *Nature Reviews Immunology*. 2019;19(1):19-30.
- [8] Haddad P, Amouzgar-Hashemi F, Samsami S, Chinichian S, Oghabian MA. Aloe vera for prevention of radiation-induced dermatitis: a self-controlled clinical trial. *Curr Oncol*. 2013;20(4):e345-e8.
- [9] Wang X. Emerging roles of ozone in skin diseases. *Zhong Nan Da Xue Xue Bao Yi Xue Ban*. 2018;43(2):114-23.
- [10] Vahlepi R, Arifin MT, Nur M, Muniroh M, Susilaningsih N. Ozonated aloe vera oil improve wound healing by decreasing neutrophil count and wound diameter in Sprague dawley rats with full-thickness skin defect. 2020. 2020;14(2):7.

- [11] Valacchi G, Lim Y, Belmonte G, Miracco C, Zanardi I, Bocci V, et al. Ozonated sesame oil enhances cutaneous wound healing in SKH1 mice. *Wound Repair Regen*. 2011;19(1):107-15.
- [12] Tamba U, Arifin M, Nur M, Muniroh M, Susilaningsih N. The role of ozonated Aloe vera oil in full-thickness skin defects: Macrophage count and epithelization length parameter [version 1; peer review: awaiting peer review]. *F1000Research*. 2020;9(1218).
- [13] Rosenthal A, Israilevich R, Moy R. Management of acute radiation dermatitis: A review of the literature and proposal for treatment algorithm. *J Am Acad Dermatol*. 2019;81(2):558-67.
- [14] Rijal S, Nur M. Analisa Pengaruh Ozonisasi Hasil Lucutan Plasma Berpenghalang Dielektrik pada Beras terhadap Perubahan Amilografi, Kekerasan, dan Warna. *Youngster Physics Journal*. 2015;4(1):61-6.
- [15] Wilgus TA, Roy S, McDaniel JC. Neutrophils and wound repair: positive actions and negative reactions. *Advances in wound care*. 2013;2(7):379-88.
- [16] Mescher AL. Junqueira's basic histology : text and atlas. 2013.
- [17] Connell PP, Hellman S. Advances in Radiotherapy and Implications for the Next Century: A Historical Perspective. *Cancer Research*. 2009;69(2):383-92.
- [18] Zeng J, Lu J. Mechanisms of action involved in ozone-therapy in skin diseases. *International immunopharmacology*. 2018;56:235-41.
- [19] Standring S. *Gray's anatomy : the anatomical basis of clinical practice*. 2016.
- [20] Travagli V, Zanardi I, Valacchi G, Bocci V. Ozone and ozonated oils in skin diseases: a review. *Mediators of inflammation*. 2010;2010.
- [21] Patel S, Maheshwari A, Chandra A. Biomarkers for wound healing and evaluation. *Journal of wound care*. 2016;25(1):46-55.

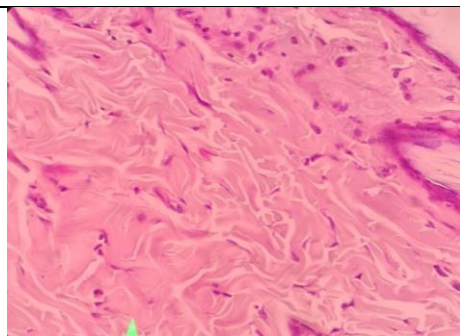
**Table 1.** Assessment of TNF- $\alpha$  using the Allred score [24]

Stained cell (%)	Proportion	Intensity	Intensity	Final Score
	Score (A)		Score (B)	(A+B)
0	0	None	0	0
<1	1	Weak	1	1-2
1 - 10	2	Medium	2	3-4
11 - 33	3	Strong	3	4-6
34 - 66	4	-	-	4-7
>67	5	-	-	5-8

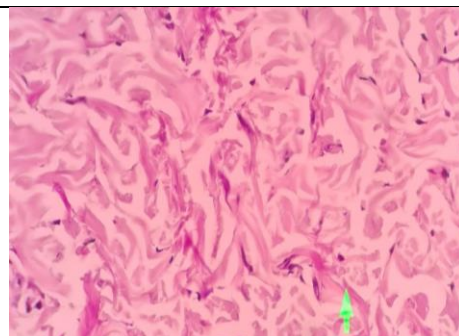


**Table 2.** Mann Whitney test results of the NL ratio and TNF- $\alpha$ .

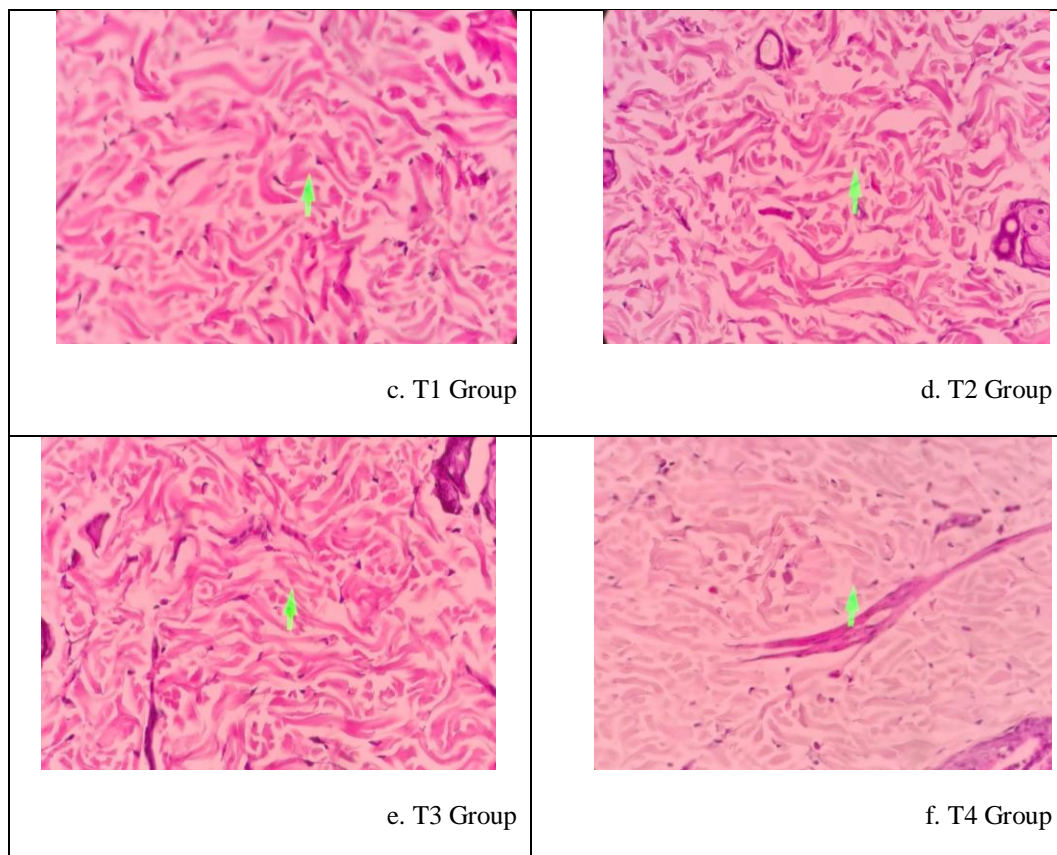
Treatment Type		P	P
I	II	(NL Ratio)	(TNF- $\alpha$ Expression)
NCG	PCG	0,007*	0,007*
	T1	0,012*	0,012*
	T2	0,006*	0,008*
	T3	0,006*	0,007*
	T4	0,009*	0,005*
PCG	T1	0,007*	0,005*
	T2	0,005*	0,005*
	T3	0,072	0,007*
	T4	0,007*	0,005*
T1	T2	0,006*	0,005*
	T3	0,006*	0,005*
	T4	0,015*	0,027*
T2	T3	0,007*	0,935
	T4	0,005*	0,029*
T3	T4	0,006*	0,007*

 Significant  $p < 0,05$ , \*significant


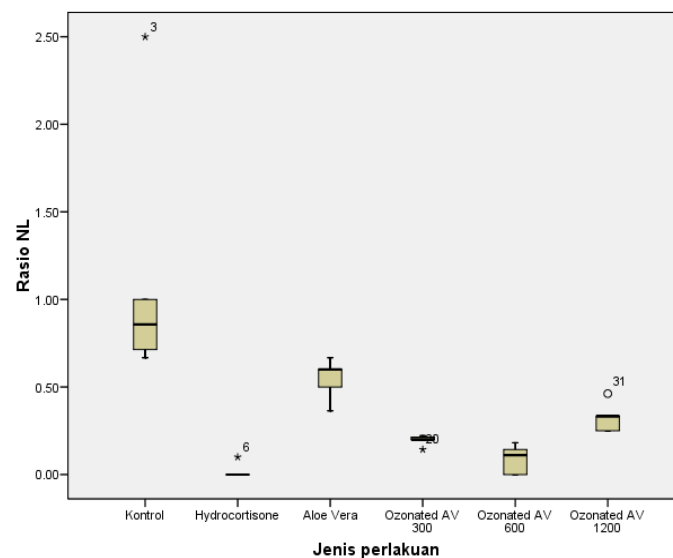
a. NCG



b. PCG

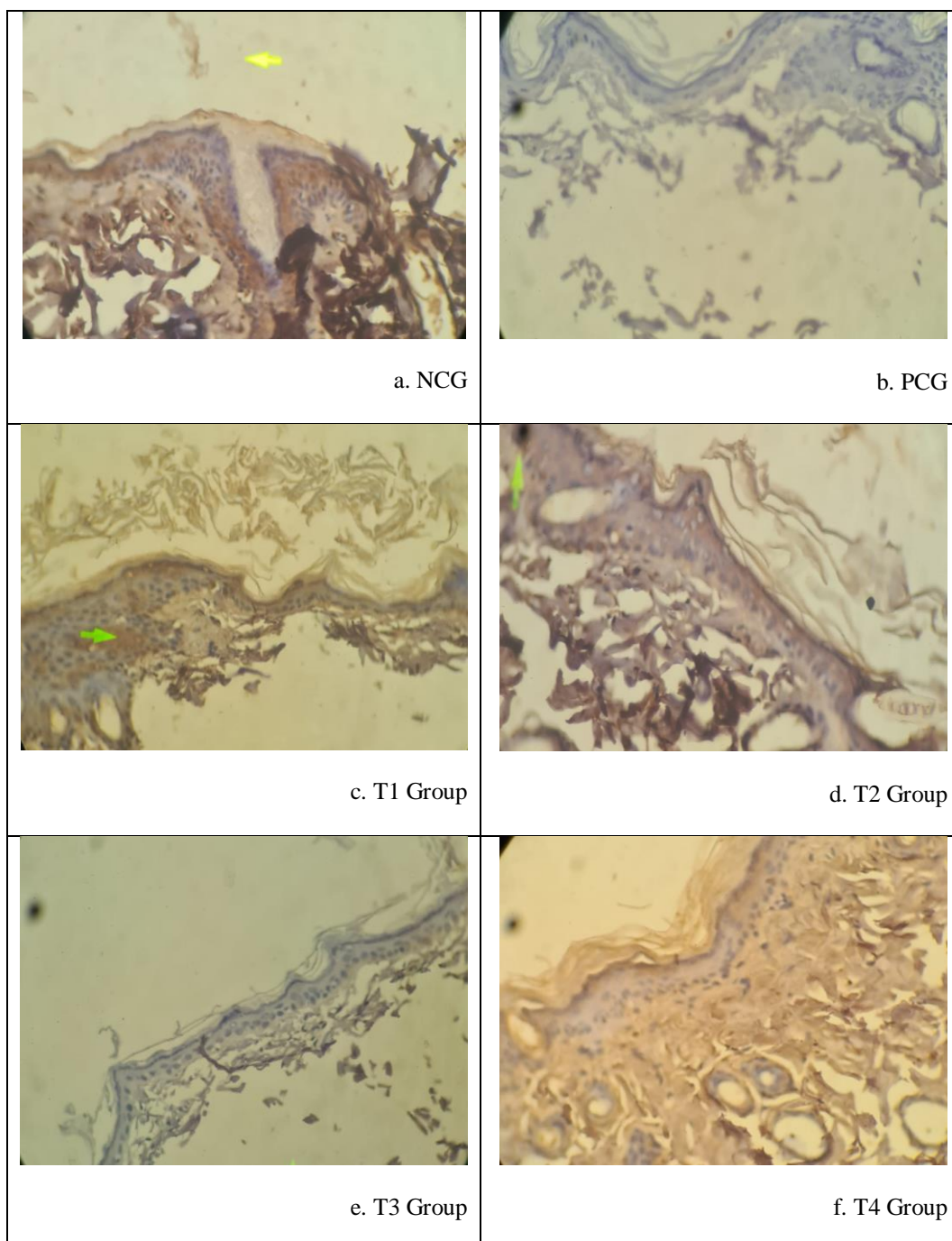


**Figure 1.** Histopathological appearance of neutrophils (green arrows) with HE staining at 400x magnification.

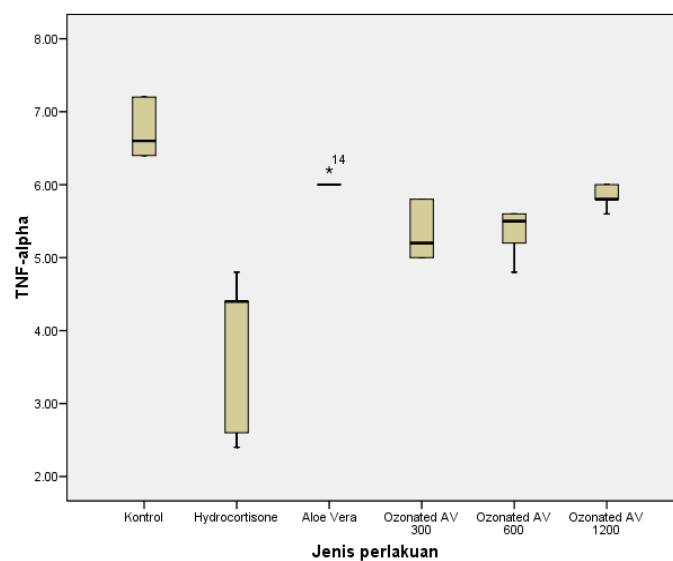


**Figure 2.** NL ratio on box plot graphic.





**Figure 3.** Histopathological appearance of TNF- $\alpha$  expression by immunohistochemical staining at 400x magnification.



**Figure 4.** TNF- $\alpha$  expression on boxplot graphic.