

TURNITIN-Right-hepatic-artery- pseudoaneurysm

by A. Gunawan Santoso

Submission date: 15-May-2023 11:01AM (UTC+0700)

Submission ID: 2093335651

File name: 2106-7953-1-PB.pdf (950.59K)

Word count: 1387

Character count: 8271

Right hepatic artery pseudoaneurysm after choledocoduodenostomy: a case report



Erik Prabowo¹, Ahmad Fathi Fuadi^{2*}, Antonius Gunawan Santoso³

ABSTRACT

Background: Pseudoaneurysm of right hepatic artery is a rare complication after *bile duct injury* (BDI) repair. An unidentified rupture of pseudoaneurysm will lead to mismanagement of this fatal complication. Massive haemorrhage can present and causes high mortality

Case Description: We report a 60-year-old female who suffered jaundice and massive upper gastrointestinal bleeding two weeks after choledocoduodenostomy bypass surgery in rural hospital. That procedure was done because of BDI after laparoscopic cholecystectomy. Embolisation was carried out after identifying an pseudoaneurysm of right hepatic artery to stop bleeding. Bleeding was transiently stopped, and rebleeding occurred several weeks later. Surgery was performed because of repeated bleeding after third embolization in Kariadi hospital. Ruptured pseudoaneurysm to choledocoduodenostomy anastomosis was found. Pseudoaneurysm was resected and right hepatic artery was sutured. Choledocoduodenostomy was closed. Continuity of biliary tract was maintained by re-reconstruction *choledoco-jejunostomy roux n Y*. Upper gastrointestinal bleeding symptom was disappeared, and bilirubin level was returned to normal at outpatient follow up after operation.

Conclusion: This patient had a hemobilia because of ruptured right hepatic artery pseudoaneurysm. Triad Quincke which consist of right upper quadrant pain, jaundice and upper gastrointestinal bleeding, occurs in 30% of patient with hemobilia. This sign of hemobilia after biliary tract procedure must be managed quickly and accurately. Angiography is main diagnostic procedure. Arterial embolisation is first line intervention to stop the bleeding. Surgery is preserved in case where rebleeding occurs. Good anatomical knowledge can prevent this complication.

Keywords: Hemobilia, Pseudoaneurysma, Choledocoduodenostomy.

Cite This Article: Prabowo, E., Fuadi, A.F., Santoso, A.G. 2021. Right hepatic artery pseudoaneurysm after choledocoduodenostomy: a case report. *Bali Medical Journal* 10(1): 35-37. DOI: 10.15562/bmj.v10i1.2106

¹Digestive Consultant Surgeon, Dr. Kariadi Hospital, Semarang, Indonesia

²Digestive Trainee Surgeon, Faculty of Medicine, Dr. Kariadi Hospital, Semarang, Indonesia

³Interventional Radiologist Consultant, Dr. Kariadi Hospital, Semarang, Indonesia

*Corresponding author:
Ahmad Fathi Fuadi;
Digestive Consultant Surgeon, Dr. Kariadi Hospital, Semarang, Indonesia;
fathi_doc@yahoo.co.id

Received: 2020-12-07

Accepted: 2021-01-15

Published: 2020-02-21

INTRODUCTION

Vascular injury or vasculobiliary injury following cholecystectomy had been reported in open and laparoscopic surgery.^{1,2,3} Minimal invasive surgery in hepatobiliary procedure also played a role in increasing number of vascular injury.⁴ Vascular injury after laparoscopic cholecystectomy had been reported around 0.8%.² Pseudoaneurysm is one of the rare complication after vasculobiliary injury, and had been reported in 2.6-5.4% vasculobiliary injury cases.^{5,6} Rupture of pseudoaneurysm can cause massive hemorrhage.⁷ Rupture of pseudoaneurysm to the biliary tract will cause haemobilia. Quincke triad (QT) which consist of

right upper abdominal pain, jaundice and upper gastrointestinal (UGI) bleeding will occur in 22-35% patient with haemobilia.⁴ The most common artery involved in vasculobiliary injury was right hepatic artery (RHA).^{1,6} Angiography is the main diagnostic tool for pseudoaneurysm in vasculobiliary injury.^{6,8}

CASE REPORT

A 60 year-old woman had massive UGI bleeding and admitted to hospital. Her condition started a month after Common Bile Duct (CBD) procedure because of bile leakage following open cholecystectomy two weeks earlier in regional hospital. She also had jaundice

and complained right upper abdominal pain before the bleeding occurred. She got massive blood transfusion, and once fell in shock condition. UGI endoscopy couldn't identify the source of bleeding. Abdominal MRI with contrast and Angiography revealed pseudoaneurysm in RHA (figure 1). Hemobilia was also found which indicates the presence of bilio-digestive bypass. Patient was diagnosed with haemobilia because of ruptured RHA pseudoaneurysm after bilio-digestive bypass. Embolization was done to occlude pseudoaneurysm. Unfortunately, UGI bleeding re-occurred two months after first embolization. Second and third embolization was carried out because of recurrence of UGI bleeding with 2 months

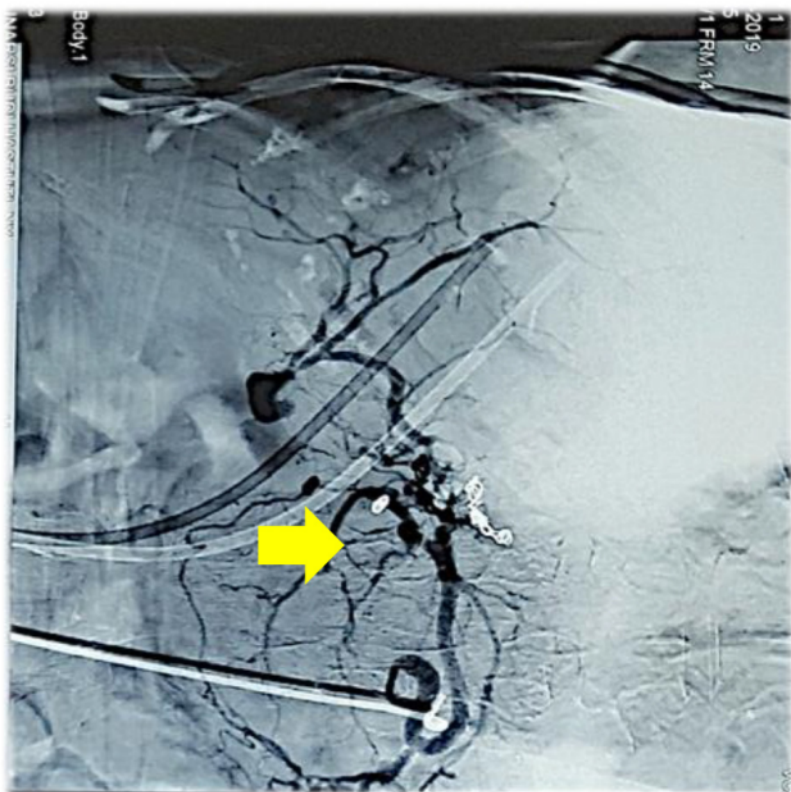

Figure 1. Pseudoaneurysm (yellow arrow) of right hepatic artery

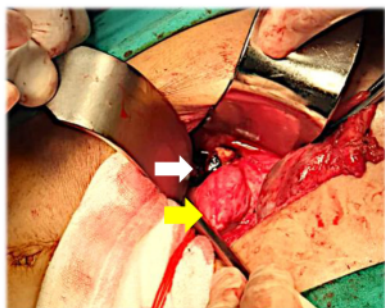


Figure 2. Pseudoaneurysm (white arrow) adhered to choledocoduodenostomy bypass (yellow arrow)

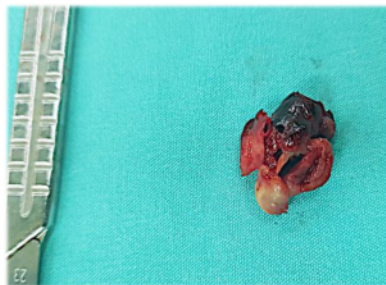


Figure 3. Pseudoaneurysm wall was excised

interval. A month after last embolization, UGI re-occured and accompanied with right upper abdominal pain and jaundice. She was consulted to digestive surgery and underwent surgical exploration. RHA pseudoaneurysm was identified at the

time of surgery (figure 2). It adhered and ruptured to the choledocoduodenostomy bypass. Pseudoaneurysm was excised (figure 3), and the artery was sutured. Choledocoduodenostomy was changed to choledocojejunostomy roux n Y to

maintain biliary continuity. The patient had uneventful recovery. She was followed up until six months after surgery. There was no complain of UGI bleeding, Bilirubin and Haemoglobin level were normal.

DISCUSSION

Pseudoaneurysm of RHA is a rare complication of vasculobiliary injury. This complication can occur after cholecystectomy and increase after bile duct injury (BDI) repair. It can develop from several weeks to months after surgery.^{5,9} In our case, pseudoaneurysm occurred four weeks after CBD procedure. Pseudoaneurysm is initiated by direct or indirect vascular injury (eg. clip erosion, thermal injury).⁹ In our case it was initiated by direct vascular injury when suturing bilio-digestive bypass. Lesion that appeared near the clip after laparoscopic cholecystectomy with UGI bleeding should raise the suspicion of pseudoaneurysm.² Rupture of RHA pseudoaneurysm into biliary tract will cause haemobilia, and in our case haemobilia was characterized by the presence of QT. All QT only occurs in about 22-35% patient with haemobilia. The absence of either QT should not rule out hemobilia, the history of a patient with suspected hemobilia plays a key role for diagnosis.⁴ Pseudoaneurysm can be diagnosed with CT angiography, in our case abdominal MRI followed by angiography was used. Embolization should be first management, and it can be repeated several times.^{5,8} In our case embolization was done three times. Surgical exploration was chosen because of repeated UGI bleeding after several embolization. This complication may occur because of altered anatomy of liver hilum after existing inflammation or because of high incision of choledocotomy that reached RHA level. Good anatomical knowledge of liver hilum can help avoid this complication.

CONFLICT OF INTEREST

The authors declare that there is no conflict of interest.

FUNDING

The authors received no financial support for the authorship of this article.

AUTHOR CONTRIBUTIONS

2
first author wrote the manuscript with input from all authors. All authors provided critical feedback and helped shape the final manuscript.

REFERENCE

1. Halasz NA. Cholecystectomy and Hepatic Artery Injuries. *Arch Surg*. 1991; 126: 137–138 <https://doi.org/10.1001/archsurg.1991.01410260021002>
2. Kassem TW. Right hepatic artery pseudoaneurysm as complication of laparoscopic cholecystectomy. *Egypt J RadiolNucl Med*. 2017; 48:931–933 <https://doi.org/10.1016/j.ejrnm.2017.08.006>
3. Tsai CH, Mo LR, Chiou CY, Ko QY, Hwang HS, Hwang MH, Yang CT, Liang TK. Therapeutic embolization of post-cholecystectomy hepatic artery aneurysm. *Hepatogastroenterology*. 1992; 39: 158–160
4. Berry R, Han J, Kardashian AA, LaRusso NF, Tabibian JH. Hemobilia: Etiology, diagnosis, and treatment. *Liver Res*. 2018; 2: 200–208 <https://doi.org/10.1016/j.livres.2018.09.007>
5. Senthilkumar MP, Battula N, Perera MTPR, Marudanayagam R, Isaac J, Muiesan P, Olliff SP, Mirza DF. Management of pseudo-aneurysm in the hepatic artery after laparoscopic cholecystectomy. *Ann R Coll Surg Engl*. 2016; 98: 456–460 <https://doi.org/10.1308/rcsann.2016.0182>
6. Strasberg SM, Helton WS. An analytical review of vasculobiliary injury in laparoscopic and open cholecystectomy. *Hpb*. 2011; 13: 1–14 <https://doi.org/10.1111/j.1477-2574.2010.00225.x>
7. Cheung HYS, Tang CN. Bleeding pseudoaneurysms complicating upper abdominal surgery. *Hong Kong Med J*. 2007; 13: 449–452
8. Regalado S, Funaki B. Radiological reasoning: Postoperative hemorrhage after open cholecystectomy and common bile duct exploration. *Am J Roentgenol*. 2008; 190: 69–74 <https://doi.org/10.2214/ajr.07.7006>
9. Milburn JA, Hussey JK, Bachoo P, Gunn IG. Right Hepatic Artery Pseudoaneurysm Thirteen Months Following Laparoscopic Cholecystectomy. *EJVES Extra*. 2007; 13: 1–3 <https://doi.org/10.1016/j.ejvsextra.2006.09.005>



This work is licensed under a Creative Commons Attribution

TURNITIN-Right-hepatic-artery-pseudoaneurysm

ORIGINALITY REPORT

6%

SIMILARITY INDEX

5%

INTERNET SOURCES

5%

PUBLICATIONS

2%

STUDENT PAPERS

PRIMARY SOURCES

1	nottingham-repository.worktribe.com Internet Source	2%
2	alzres.biomedcentral.com Internet Source	2%
3	www.journalijar.com Internet Source	1%
4	Ø. Mathisen, O. Søreide, A. Bergan. "Laparoscopic Cholecystectomy: Bile Duct and Vascular Injuries: Management and Outcome", Scandinavian Journal of Gastroenterology, 2009 Publication	1%

Exclude quotes On

Exclude matches Off

Exclude bibliography On

TURNITIN-Right-hepatic-artery-pseudoaneurysm

GRADEMARK REPORT

FINAL GRADE

/0

GENERAL COMMENTS

Instructor

PAGE 1

PAGE 2

PAGE 3
