

# ARC cushing syndrome

*by* Heri Nugroho

---

**Submission date:** 10-May-2023 03:22PM (UTC+0700)

**Submission ID:** 2089324967

**File name:** ARC\_cushing\_syndrome.pdf (607.61K)

**Word count:** 1124

**Character count:** 6866

## Cushing's Syndrome Related a Giant Adrenal Adenoma

Moh Adi Soedarso<sup>1\*</sup>, Erik Prabowo<sup>2</sup>, Danu Sulistyowati<sup>3</sup>, A Gunawan Santoso<sup>4</sup>, Devia E Listiana<sup>5</sup>, K Hery Nugroho<sup>6</sup>

<sup>1</sup>Urology Division, Surgery Department, Academic Medical Center Dr. Kariadi Hospital, Diponegoro University, Indonesia

<sup>2</sup>Digestive Division, Surgery Department, Academic Medical Center Dr. Kariadi Hospital, Diponegoro University, Indonesia

<sup>3</sup>Anesthesia Department, Academic Medical Center Dr. Kariadi Hospital, Diponegoro University, Indonesia

<sup>4</sup>Radiology Department, Academic Medical Center Dr. Kariadi Hospital, Diponegoro University, Indonesia

<sup>5</sup>Pathology Anatomy Department, Academic Medical Center Dr. Kariadi Hospital, Diponegoro University, Indonesia

<sup>6</sup>Endocrinology Division, Internal Medicine Department, Academic Medical Center Dr. Kariadi Hospital, Diponegoro University, Indonesia

\*Corresponding Author: Moh Adi Soedarso, Urology Division, Surgery Department, Academic Medical Center Dr. Kariadi Hospital, Diponegoro University, Indonesia, Email: drsoedarso@gmail.com

### Abstract

A large adrenal adenoma case that shows a complete picture of Cushing's syndrome. Clinically led to malignant right adrenal tumor. Endocrine manipulation, laparoscopic adrenalectomy surgery performed. No event adrenal crisis, syndrome disappear.

**Keywords:** Adrenal adenoma, Cushing's syndrome, laparoscopic adrenalectomy

### 1. INTRODUCTION

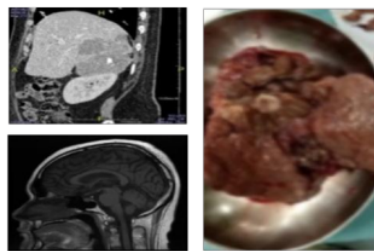
Adrenal adenomas are responsibility of approximately 10-15% of cases of Cushing's syndrome. It can be either ACTH-dependent (pituitary adenoma or ACTH independent (extra pituitary adenoma). Multidisciplinary approach: endocrine manipulation, surgery, specific anesthetic procedure is needed in management of this case.

### 2. CASE REPORT

A 20-year-old man was admitted for evaluation of Cushing's syndrome. He presented history of headache, fatigue, mood disorder, hypertension (Blood Pressure 170/120 mmHg), moon face, buffalo hump, striae rubrae. Cortisol serum laboratory increased 33,53  $\mu$ gr/dl (Normal range: 3,09 – 16,6 $\mu$ gr/dl). Abdominal CT Scan showed a right adrenal mass diameter 10,53 x 6,83 cm, heterogeneous pattern with calcified and necrotized area.

Level of ACTH < 5 pg/ml (Normal range: 6 – 50 pg/ml), absence hypothalamus pituitary

defect in brain MRI angiography led to the primary site on adrenal (figure 1, bottom-left)



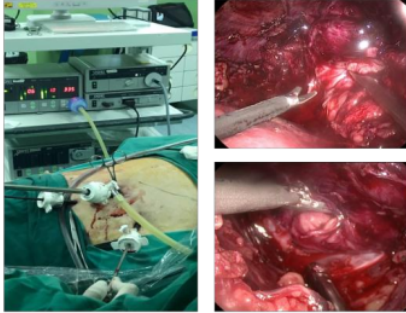
**Figure1.** MSCT noted large adenoma, MRI hypothalamus hypophise normal. Large resected adrenal compare with large kidney basin ( right )

### 2.1. Treatment

Manipulation with ketoconazole 600 mg daily to treat hypercortisolemia. The patient underwent laparoscopic right adrenalectomy. Preparation of hydrocortisone 100 mg during anesthesia-surgery to prevent occurrence adrenal crisis.

Patient position LLD, 11mm trocar port with 0, 30-degree optic, 2 port 5mm for working

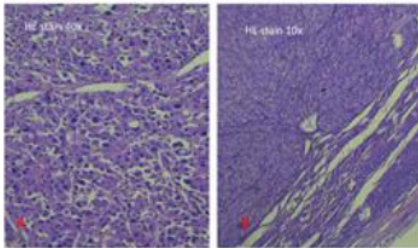
element. Harmonic ultrasound shear used to dissection, hemoLock clip to control vascular. Right subcostal incision makes to remove adrenal gland. EBL 1000 cc, close monitoring in ICU ward. 5



**Figure 2.** Left: trocar optic, working element. Right, laparoscopic view

Hydrocortison continued 5 days after surgery. Ventilatory support remove in 2 day after surgery. Fifth day condition stabil without sign of adrenal crisis, patient send to elective ward. Gross specimen appear giant adrenal, 15 x 10 cm (figure 1, right). Cortex area has a solid elasticity consistency. Some areas of necrosis are suspected of malignancy. But systematic microscopic investigations shown no visible mitosis or malignant signs (fig 3 A)

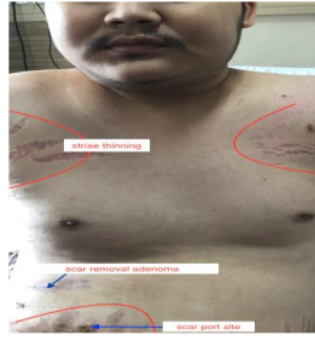- A. Proliferation of polygonal cells with oval round, clear cytoplasm to eosinophilic, normochromatic, prominent nucleoli. No visible mitosis or malignant signs.  
B. No visible infiltration to the capsule, angioinvasi



**Figure 3A.** Proliferation of polygonal cells with oval round, clear cytoplasm to eosinophilic, normochromatic, prominent nucleoli. No visible mitosis or malignant signs B. No visible infiltration to the capsule, angioinvasi

## 2.2. Outcome and Follow-up

On the fifth day after surgical intervention, postoperative cortisol level at 12  $\mu$ gr/dl. Seventh day, surgical wound healing well with minimum dose NSAID orally. Striae thinning, gynecomastia, buffalo hump, moon face reduced.



**Figure 4.** striae in abdomen, axilla thins. Noted removal site and trocar scar

The patient was regularly followed up at Endocrine division, Internal medicine department. Moon face have been eliminated, no striae and good mood condition. Blood pressure was 130/ 70 mmHg (without antihypertensive drugs) and cortisol serum was 4,52  $\mu$ gr/dL and independent from steroid medication.

## 3. DISCUSSION

We manipulated with ketoconazole by considering the hypothalamic adrenal pituitary axis to overcome due to excess cortisol. Endocrinologist can make a normal cortisol titer, and laparoscopic surgery can be performed. Another problem is that both clinical and heterogeneous physical imaging and large > 8 cm should be suspected and managed as a case of malignancy. Ibrahim, Agrusa also Zografos reported that laparoscopic adrenalectomy for giant size adrenal to be feasible and safe so we did this procedure.

Gross specimens also show heterogeneous features, there is a solid chewy part and calcification microscopic histopathology examination does not show specific malignancy signs. Also the area of necrosis that was originally thought to be strong focus malignancy we examined carefully only showed a dead cell collection.

Post-operative Cushing's symptom disappears, normotension without antihypertension, weakness, bad emotion, thinning striae. Buffalo hump, obesity, gynecomasti in next follow-up seems to be reduced. This convinced us that these patients were purely functional benign lesions of the giant adrenal.

## 4. CONCLUSION

Multidisciplinary approach including endocrine treatment, prevention adrenal crisis and

laparoscopic adrenalectomy procedure have good result for Cushing's syndrome due to adenoma of giant adrenal gland.

#### REFERENCES

- [1] Nieman LK, Bilier BM, Finding JW. The diagnosis of Cushing's syndrome: an endocrine society clinical practice guideline. *J Clin Endocrinol Metab.* 2008; 93:1526-40
- [2] Castinetti F, Guignat L.,Giraud P et al.Ketoconazole in Cushing's disease: is it worth a try?. *J Clin Endocrinol Metab.*2014;99:1623
- [3] Aggarwl S,Yadav S Sharma AP, Sethi V. Laparoscopic bilateral transperitoneal adrenalectomy for Cushing's syndrome: surgical challenges and lessons leamt. *SurglaparoscEndoscPercutanTech.*2013;23(3):32 4-8
- [4] Debillon E, Velayoudom-Cephise FL, Salenave S. Unilateral adrenalectomy as a first line treatment of Cushing's syndrome in patients with primary bilateral macronodular adrenal hyperplasia. *J Clin Endocrinol Metab.* 2015 Dec; 100(12):4417-24. <http://dx.doi.org/10.1210/jc.2015-2662>. Epub 2015 Oct 9
- [5] Zografos George N et al. Laparoscopic resection of Large Adrenal Tumor: Journal of the Society of Laparoscopic Surgeon. (2010) 14:364-368. DOI: 10.4293/108680810X12924466007160
- [6] Agrusa A et al. Laparoscopic adrenalectomy for Large adrenal masses: Single team experience. *International Journal of Surgery* 12(2014). <http://dx.doi.org/10.1016/j.ijsu.2014.05.050>
- [7] Bozkurt H Ibrahim et al. Laparoscopic adrenalectomy for a Large adrenal masses: Is it really more complicated? *KJMS.* 2015. <http://dx.doi.org/10.1016/j.kjms.2015.09.005>

**Citation** Moh Adi Soedarso, Erik Prabowo, Danu Sulistyowati, A Gunawan Santoso, Devia E Listiana & K Hery Nugroho. Cushing's Syndrome Related a Giant Adrenal Adenoma. *ARC Journal of Urology.*2018; 3(2):15-17. doi:[dx.doi.org/10.20431/2456-060X.0302003](http://dx.doi.org/10.20431/2456-060X.0302003).

**Copyright:** © 2018 Authors. This is an open-access article distributed under the terms of the Creative Commons Attribution License, which permits unrestricted use, distribution, and reproduction in any medium, provided the original author and source are credited.

# ARC cushing syndrome

---

## ORIGINALITY REPORT

---

24%

SIMILARITY INDEX

18%

INTERNET SOURCES

23%

PUBLICATIONS

7%

STUDENT PAPERS

---

## PRIMARY SOURCES

---

- 1** Mohamad Adi Soedarso, YinYin Wahyuni, Maria Immaculata Tjahjati. "Comparison of Nuclear Matrix Protein-22 and Urine Cytology in Diagnosing Bladder Cancer", Indonesian Journal of Cancer, 2019  
Publication 5%
- 2** [jcp.bmj.com](http://jcp.bmj.com)  
Internet Source 3%
- 3** [healthdocbox.com](http://healthdocbox.com)  
Internet Source 2%
- 4** [www.ncbi.nlm.nih.gov](http://www.ncbi.nlm.nih.gov)  
Internet Source 2%
- 5** Akpunonu, B.E.. "Secondary hypertension: Evaluation and treatment", Disease-a-Month, 199610  
Publication 2%
- 6** Submitted to Australian Catholic University  
Student Paper 1%
- 7** De Venanzi, Agostino, Guilherme Asmar Alencar, Isabelle Bourdeau, Maria Candida 1%

Barisson Villares Fragoso, and André Lacroix.  
"Primary bilateral macronodular adrenal  
hyperplasia :", Current Opinion in  
Endocrinology Diabetes and Obesity, 2014.

Publication

8

"The Impact of Smoking on Urologic  
Outcomes", ARC Journal of Urology, 2016

Publication

1 %

9

[www.acarindex.com](http://www.acarindex.com)

Internet Source

1 %

10

Submitted to Baylor University

Student Paper

1 %

11

[moscow.sci-hub.se](http://moscow.sci-hub.se)

Internet Source

1 %

12

[kimdir-biyografi.nedir.kim](http://kimdir-biyografi.nedir.kim)

Internet Source

1 %

13

[mail.eurekaselect.com](http://mail.eurekaselect.com)

Internet Source

1 %

14

"VIDEO FORUM", Journal of Endourology,  
08/2002

Publication

1 %

15

[ec.bioscientifica.com](http://ec.bioscientifica.com)

Internet Source

1 %

16

Binbin Gong, Ming Ma, Wenjie Xie, Xiaorong  
Yang, Ting Sun. "Retroperitoneal laparoscopic  
adrenalectomy with transient renal artery

1 %

# occlusion for large adrenal tumors ( $\geq 8$ cm)", Journal of Surgical Oncology, 2018

Publication

---

---

Exclude quotes Off

Exclude matches Off

Exclude bibliography Off

# ARC cushing syndrome

---

## GRADEMARK REPORT

---

FINAL GRADE

**/0**

GENERAL COMMENTS

**Instructor**

---

PAGE 1

---

PAGE 2

---

PAGE 3

---