

# A Case Report : Addison disease caused by adrenal tuberculosis

*by* Heri Nugroho

---

**Submission date:** 06-Sep-2022 10:43AM (UTC+0700)

**Submission ID:** 1893427877

**File name:** 1-s2.0-S2214442018300810\_DR\_HERI\_tambahn.pdf (850.78K)

**Word count:** 1478


**Character count:** 8404



ELSEVIER

Contents lists available at ScienceDirect

## Urology Case Reports

journal homepage: [www.elsevier.com/locate/eucr](http://www.elsevier.com/locate/eucr)

## Oncology

## A case report: Addison disease caused by adrenal tuberculosis

Moh Adi Soedarso<sup>a,\*</sup>, K Hery Nugroho<sup>b</sup>, Meira Dewi K.A.<sup>c</sup><sup>a</sup> Division of Urology, Surgery Department, Academic Medical Center Dr. Kariadi Hospital, Faculty of Medicine, University of Diponegoro, Semarang, Indonesia<sup>b</sup> Division of Endocrinology, Internal Medicine Department, Academic Medical Center Dr. Kariadi Hospital, Faculty of Medicine, University of Diponegoro, Semarang, Indonesia<sup>c</sup> Department of Anatomy Pathology, Academic Medical Center Dr. Kariadi Hospital, Faculty of Medicine, University of Diponegoro, Semarang, Indonesia

## ARTICLE INFO

## Keywords:

Addison's disease  
Adrenal gland tuberculosis  
Laparoscopic adrenalectomy

## ABSTRACT

We report middle age man with skin hyperpigmentation oral and lip mucous membranes, general malaise and depression. Further examinations lead to adrenal insufficiency, Addison's disease. Imaging studies show bilateral adrenal hyperplasia, show negative result for tuberculosis.

We perform laparoscopic adrenalectomy. Multiple caseosa necrosis in gross specimen and Langhan's giant cells microscopic appearance ensure patient suffered Addison's disease cause by adrenal gland tuberculosis.

1 First Addison's disease (AD) or primary adrenocortical insufficiency by Thomas Addison in patients with adrenal tuberculosis (adrenal TB).<sup>2,3,5</sup> Currently in developed countries, about 75–80% of AD cases are caused by autoimmune destruction, ie autoimmune adrenalitis, whereas tuberculosis and other cases is the cause for 7–20% cases. TB still be a major cause of Addison in developing countries. CT and MR are useful for distinguishing between Addison's adrenal TB and others. CT or MR features of adrenal TB are enlarged bilateral masses, peripheral rim enhancement and calcification.<sup>4,5</sup>

## 5 Case report

A 43-year-old man was admitted for the evaluation of Addison's disease. He complain of depression, nausea, fatigue, weight loss, decreased appetite, abdominal pain, joint pain, skin hyper-pigmentation, nails, mouth and mucous membranes of the lips. Cardiac, respiratory, abdominal and neurologic examination showed no abnormalities. Laboratory serum cortisol < 0.05 µg/dl (Normal range: 3.09–16.6 µg/dL). Investigation of the causes of this adrenal hypofunction due to tuberculosis by blood sedimentation rate, Mantoux test show negative results. Following to Interferon Gamma Release Assay, IGRA test also show negative results. Upper abdominal MRI shows bilateral adrenal (right AP 5.59 × LL 5.56 × CC 4.46 cm; left AP 4.74 × LL 4.12 × CC 5.66 cm) with regular edges, bilateral adrenal hypertrophy suspects with differential diagnosis of adrenal adenomas (see Fig. 1).

The patient underwent laparoscopic left adrenalectomy. RLD position, trocar 11 mm optic, with 2 working elements 5 mm.<sup>1</sup>

Durante laparoscopic operation is obtained the adrenal gland enlarges, the consistency of various soft density, adhesions with around.

The gross specimen macroscopically appears tubercle caseous (see Fig. 2).

Preparation of hydrocortisone 100 mg a day before surgery to prevent the occurrence of adrenal crisis, serum cortisol increase to 32.18 µg/dl.<sup>2,3</sup> The pathology report revealed tuberculosis of the adrenal gland (see Fig. 3).

The cortisol level was measured at 30.85 µg/dl, the second post-operative day. Patients are routinely followed up in the Endocrine division. Hydrocortisone continued after surgery tapering down 10 mg/h; 7.5 mg/h; 5 mg/h; 2.5 mg/hr; 1 mg/hr and continue with oral hydrocortisone 25 mg daily. Blood pressure is 120/70 mmHg (without anti-hypertensive medication) and hypo cortisol symptom release.

After the pathology results (adrenal TB) the patient is treated with a fixed drug combination of tuberculosis 5 tabs daily.

## Discussion

Since 1855, after Thomas Addison first explained the main cause of adrenal failure is bilateral adrenal failure due to *Mycobacterium tuberculosis* infection. For instance, in 1930 Guttman reported that tuberculosis main causes of Addison's disease are caused by.<sup>2</sup> Currently, with wide use of anti-TB drugs, the incidence of adrenal TB is reduced, otherwise in developing countries, tuberculosis is still the main cause of AD. Nomura et al. observed that 93% of patients with adrenal TB had previously suffered from classical TB mostly from the lungs and pleura, but in these patients there was no classical TB.<sup>2,3,5</sup> Pulmonary and pleural examination showed negative results from tuberculosis.

Patient presented with hormonal deficiency and any concurrent illness. The most common symptoms such as fatigue, weakness,

\* Corresponding author.

E-mail address: [drsoedarso@gmail.com](mailto:drsoedarso@gmail.com) (M.A. Soedarso).

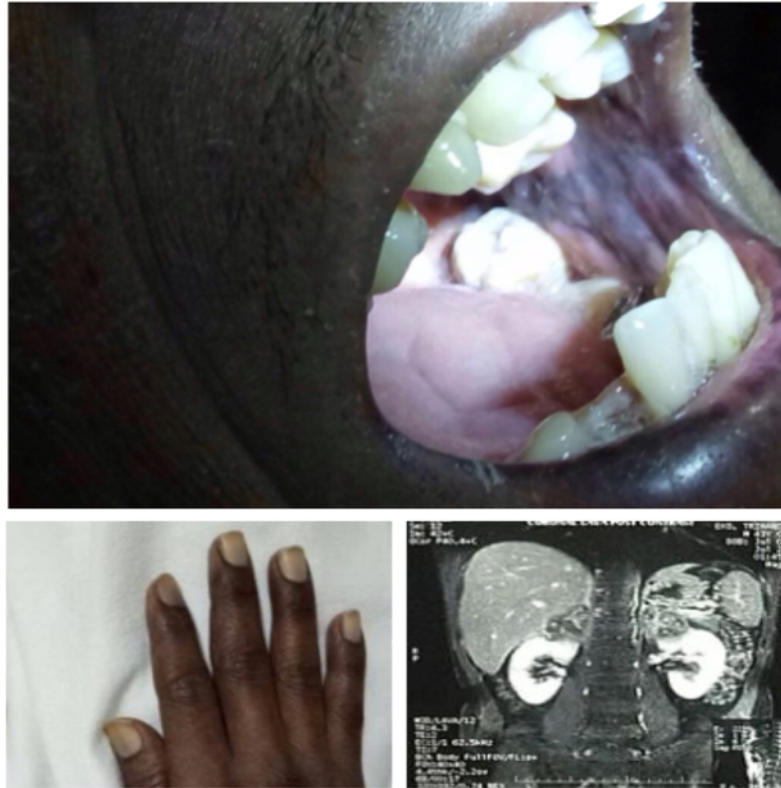

Fig. 1. Hyper pigmentation lip oral mucosa, nail, MSCT bilateral adrenal hyperplasia.

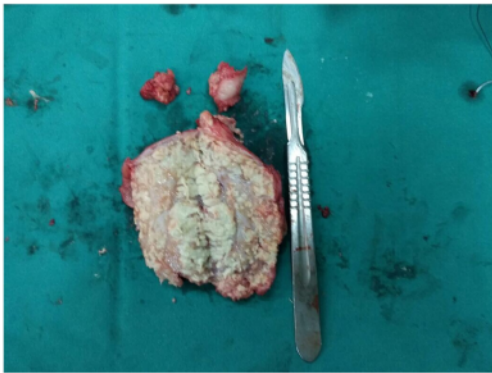


Fig. 2. Tubercle in gross specimen.

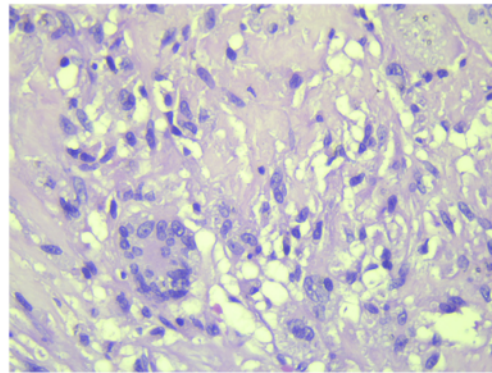


Fig. 3. Langhan's Datia cell.

anorexia, nausea, vomiting and psychological disorder also hyper-pigmentation are accompanied by severe adrenal hypo-function syndromes presented. Adrenal imaging looking for etiology that leads to TB are mild adrenal enlargement and adrenal calcifications in the apical region. As Zhang et al. reported in 2008 first reported the characteristics of MR and explained its usefulness in diagnosing adrenal TB.<sup>2</sup> The most common MR manifestations include bilateral involvement, mass-like enlargement, T2 hypo or iso intense signals from the central zone, and peripheral edge enhancement.<sup>4,5</sup>

Lam and Lo thought that histologic examination of the adrenal is important for diagnostic of adrenal TB.<sup>2</sup> A definitive diagnosis of tuberculosis is found in *Mycobacterium tuberculosis*, necrosis caseosa area,

Datia-Langhans cell. Provision of medical therapy without found any specific thing is not wise. Imaging's shows the right adrenal appears covered in the liver and the left adrenal is seen attached to the large vessels. Imagings lead to adrenal TB but lack the support of laboratory to tuberculosis confuses the etiology of adrenal insufficiency.

Interferon- $\gamma$  release assays (IGRAs) have been developed for the diagnosis infection tuberculosis, approximately 8–19% of patients have a negative IGRA result when presenting with active tuberculosis. Immunodeficiency, one of risk factors were associated with false negative IGRAs.<sup>6</sup> Preoperative hydrocortisone administration is a pitfall for false negative results.

Heterogeneity surface, calcification, necrosis area suspicious

malignancy could not be excluded. We do not use guided CT or MRI adrenal fine needle biopsy because it does not possible to reach the adrenal without injure the visceral organ. Nirag present inaccurate percutaneous core needle biopsy 0–30%.<sup>3</sup>

The unilateral laparoscopic adrenalectomy perform to obtaining etiology. Necrosis area pattern imaging which suspected malignancy, in gross-specimen seen as liquefaction necrosis. It proven reduce the symptoms of adrenal hypo-function. Common symptoms such as fatigue, nausea, decreased appetite, abdominal pain, joint pain and depression are reduced.

The labs is negative, whether it is show has never suffered classic TB ? Addison's adrenal TB as primary infection is also still questionable. Availability such as adrenal autoantibodies and endoscopic ultrasound for guide needle biopsy may be able to sharpen the lack of diagnostic procedures in order to reduce an unnecessary surgery.

### Conclusion

**A combination of clinical symptoms, laboratory results, CT or MR features and laparoscopic adrenalectomy can be performed to establish a final diagnosis, with pathological findings. Despite fine needle biopsy is low risk procedure when access is not possible still require adrenalectomy. Prompt treatment with anti tuberculosis chemotherapy, biochemical monitoring of adrenal function and appropriate steroid**

**therapy are essential for the management of adrenal TB.**

### Appendix A. Supplementary data

Supplementary data related to this article can be found at <http://dx.doi.org/10.1016/j.eucr.2018.05.015>.

### References

1. Andrea Balla, Silvia Quaresima, Ardit Seitaj, Andrea M. Isidori, Franco Iafrate and Alessandro M. Paganini. Laparoscopic left adrenalectomy with submesocolic and retropancreatic approach. *Laparoscopic Surgery*, Chapter 4, 91–103 (<https://doi.org/10.5772/66457>).
2. Dąbrowska Anna, Tarach Jerzy, Prystupa Andrzej, Kurowska Maria. Addison's disease due to the adrenal glands. *Journal of Pre-Clinical and Clinical Research*. 2012;6(No 2):88–92.
3. Nakaoka K, Branch J, Yamaguchi M, et al. A case of primary adrenal tuberculosis - a diagnostic quandary. *Endocrinol Metab Syndrome*. 2012;1(1)(<https://doi.org/10.4172/2161-1017.1000103>).
4. Ferreira Sara, Freitas-Silva Margarida. The importance of computed tomography findings in detecting tuberculous Addison's disease. *European Journal of Case Reports in Internal Medicine*. 2017;4([https://doi.org/10.12890/2017\\_000622](https://doi.org/10.12890/2017_000622)).
5. Maller VV, Afzal MO, Shankar S. Primary adrenal tuberculosis causing adrenal insufficiency. *Hong Kong J Radiol*. 2016;19 e6–9.
6. Visser Veerle de, Sotgiu Giovanni, Lange Christoph, et al. False-negative interferon-γ release assay results in active tuberculosis: a TBNET study. *Eur Respir J*. 2014. <http://dx.doi.org/10.1183/09031936.00120214>.

# A Case Report : Addison disease caused by adrenal tuberculosis

## ORIGINALITY REPORT

26%

SIMILARITY INDEX

17%

INTERNET SOURCES

5%

PUBLICATIONS

12%

STUDENT PAPERS

## PRIMARY SOURCES

1	<a href="http://www.jpccr.eu">www.jpccr.eu</a> Internet Source	12%
2	Submitted to Universidad San Francisco de Quito Student Paper	8%
3	<a href="http://erj.ersjournals.com">erj.ersjournals.com</a> Internet Source	3%
4	Submitted to University of Glamorgan Student Paper	2%
5	<a href="http://synapse.koreamed.org">synapse.koreamed.org</a> Internet Source	1%
6	van Rongen, Anne, Janelle D. Vaughns, Ganesh Moorthy, Jeffrey S. Barrett, Catherijne A. J. Knibbe, and John N. van den Anker. "Population pharmacokinetics of midazolam and its metabolites in overweight and obese adolescents : Pharmacokinetics of midazolam in obese adolescents", British Journal of Clinical Pharmacology, 2015. Publication	1%

---

Exclude quotes      On

Exclude matches      Off

Exclude bibliography      On

# A Case Report : Addison disease caused by adrenal tuberculosis

---

## GRADEMARK REPORT

---

FINAL GRADE

**/0**

GENERAL COMMENTS

**Instructor**

---

PAGE 1

---

PAGE 2

---

PAGE 3

---