

Preoperative sensory aura predicts risk for seizure in temporal lobe epilepsy surgery

by Muhamad Thohar Arifin

Submission date: 24-Jun-2021 04:24PM (UTC+0700)

Submission ID: 1611501142

File name: tive_sensory_aura_predicts_risk_for_seizure_in_temporal_lobe.pdf (962.2K)


Word count: 4226

Character count: 22391



Contents lists available at ScienceDirect

Epilepsy & Behavior

journal homepage: www.elsevier.com/locate/yebeh

Preoperative sensory aura predicts risk for seizure in temporal lobe epilepsy surgery

Muhamad Thohar Arifin ^{a,*}, Ryosuke Hanaya ^b, Yuriz Bakhtiar ^a, Aris Catur Bintoro ^c, Koji Iida ^d, Kaoru Kurisu ^d, Kazunori Arita ^b, Jacob Bunyamin ^a, Rofat Askoro ^a, Surya P. Brilliantika ^a, Zainal Muttaqin ^a

^a Department of Neurosurgery, Faculty of Medicine, Diponegoro University, Indonesia

^b Department of Neurosurgery, Graduate School of Medical and Dental Sciences, Kagoshima University, Japan

^c Department of Neurology, Faculty of Medicine, Diponegoro University, Indonesia

^d Department of Neurosurgery, Graduate School of Biomedical and Health Sciences, Hiroshima University, Japan

ARTICLE INFO

Article history:

Received 17 April 2020

Revised 11 June 2020

Accepted 12 June 2020

Available online xxxx

Keywords:

Temporal lobe epilepsy

Drug-resistant

Aura

Sensory aura

ABSTRACT

Background: Patients with temporal lobe epilepsy (TLE) often report viscerosensory and experiential auras, with substantial epilepsy localization. However, few previous studies have investigated the epileptic preoperative aura, particularly with regard to its effect on surgical outcomes in patients with drug-resistant epilepsy.

Objective: This study investigated the potential role of preoperative aura in predicting outcomes after surgery for TLE.

Material and methods: This study included consecutive patients diagnosed with TLE who underwent anterior temporal lobectomy (ATL) for drug-resistant TLE during the period from January 1999 to December 2017. Data pertaining to patient age at the time of surgery, sex, age at initial seizure onset, duration of epilepsy, presence of preoperative aura, comprehensive clinical semiology, side of surgery, and type of pathology were analyzed. Preoperative auras were classified as autonomic, sensory, mental and affective, or multiple manifestations. Patients were followed at 3 and 12 months after surgery and at regular intervals thereafter.

Results and conclusions: A total of 498 patients were included in the study. Positive preoperative aura was observed in 386 patients (77.51%). The correlation of each variable with seizure outcomes was analyzed, and the only variable found to correlate with seizure outcome was the presence of preoperative aura. Compared with those with negative preoperative aura, those with positive preoperative aura were 1.74-fold more likely to be seizure-free after surgery for TLE. The analysis of patient data suggested a later onset of initial seizure in those with positive preoperative aura, compared with those without ($p = 0.04$, 95% confidence interval (CI): 0.55–3.24). Patients with a shorter duration of disease prior to TLE surgery were more likely to achieve seizure-free status postoperatively. Preoperative sensory aura was a good predictor that a patient would be seizure-free during follow-up ($p = 0.022$).

© 2020 Elsevier Inc. All rights reserved.

1. Introduction

Temporal lobe seizures often manifest as partial seizures. Approximately two-thirds of people with intractable seizures require surgical treatment. Auras (from Latin for “wind” and Greek for air) are, in general, important partial seizures that may appear in isolation but occur in a large proportion of patients at the beginning of complex partial seizure (CPS). The duration of an aura before the impairment of consciousness ranges from a few seconds to 2 min. Auras arise from the excitation of a functionally activated cortex near the ictal onset zone and play a

well-recognized role in localization and, under other circumstances, lateralization of the ictal onset region [1–5].

Patients with temporal lobe epilepsy (TLE) commonly report viscerosensory and experiential auras, which have substantial epilepsy localization [6]. However, only a limited number of previous studies have investigated the importance of the epileptic aura, particularly with regard to its effect on surgical outcomes in patients with drug-resistant epilepsy. Although recent studies have analyzed the significance of postoperative aura, few of these reports have investigated the associated clinical variables, radiological and pathological substrates, and electrophysiological characteristics in patients with aura. An even smaller number of studies have classified such findings on the basis of aura subtype. In this study, we sought to determine whether the presence of preoperative aura could be used to predict seizure outcomes in patients who had undergone surgery for drug-resistant TLE.

* Corresponding author at: Department of Neurosurgery, Faculty of Medicine, Diponegoro University, Jl. Prof Soedarto Tembalang, Indonesia.
E-mail address: thohar@fkundip.ac.id (M.T. Arifin).

2. Methods

2.1. Patient selection

Consecutive patients who undertook a preliminary assessment and underwent temporal lobe surgery for drug-resistant TLE were evaluated during the period from January 1999 to December 2017. Patients were followed at 3 and 12 months postoperatively, then annually thereafter. In all cases, the presurgical assessment included clinical examination, 1.5-T magnetic resonance imaging (MRI), and routine electroencephalography (EEG). In some cases, the preliminary assessment included long-term video-EEG monitoring and a neuropsychological evaluation. The surgery consisted of en-bloc standard anterior temporal lobectomy (ATL) with lesion resection when lesions other than mesial temporal sclerosis (MTS) were present and selective amygdalohippocampectomy (SAH). The procedure was performed according to standard protocols [7], and all surgeries were performed by the same team of neurosurgeons (Zainal Muttaqin and Muhamad Thohar Arifin), who had expertise in epilepsy surgery. In this study, ATL was performed as a 4- to 6-centimeter block resection of the lateral temporal cortex, followed by microsurgical resection of the amygdala and full-block resection of the hippocampus and parahippocampal gyrus. The transylvian SAH was performed for all cases [8].

The all-surgical specimens were submitted for histopathological examination. This study was approved by the Joint Ethics Committee of the Kariadi General Hospital. Written informed consent was obtained from all patients for being included in the study, or a parent/legal guardian of patients under the age of 18 years.

2.2. Assessment of variables and postoperative outcomes

The variables analyzed included age at the time of surgery, sex, age at onset of the first seizure, duration of epilepsy, presence of preoperative aura, comprehensive clinical semiology, side on which surgery was performed, and type of pathology. Patients were assessed for the presence/absence of preoperative aura, and aura was classified as autonomic, sensory, mental and affective, or multiple manifestations. Outcomes were assessed at 3 and 12 months after surgery and at regular intervals thereafter. All patients were examined in depth for the recurrence of seizures, and the date of any recurrence was recorded. The cohort was divided into two broad categories: those who were "seizure-free (Engel I)", with or without antiepileptic drugs (AEDs) at any time during follow-up, were considered to have good outcomes and those who experienced seizures of any kind postoperatively (Engel II, III, IV) were considered to have "poor outcomes".

2.3. Statistical analysis

Pearson's Chi-square test and Fisher's exact test were used to compare patients' positive vs. negative preoperative aura in terms of baseline characteristics. Univariate logistic regression analysis was used to assess the prognostic importance of aura subtype with regard to seizure outcome. Variables significant at the 10% level in the preliminary analysis were included in the Cox proportional hazards regression model. Kaplan-Meier plots were used to analyze outcomes (likelihood of one year free of seizures) for each type of preoperative aura. A p-value of less than 0.05 was considered statistically significant. All analyses were performed using a computerized statistical model.

3. Results

3.1. Correlation between preoperative aura and surgical outcomes in patients with TLE

The patient population included 498 patients diagnosed with TLE who underwent surgery for TLE during the period from January 1999

to December 2017. Among this group, 196 (39.35%) were male. Median age, age at onset of the first seizure, and duration with TLE prior to surgery were 23 years (2–62 years), 11 years (0.16–40 years), and 10 years (1–62 years). Positive preoperative aura was reported by 386 patients (77.51%); 112 (22.48%) did have negative preoperative aura. The most common etiologies were focal impaired awareness seizure (FIAS) 275 (55.22%) and focal to bilateral tonic-clonic seizure (FBTCS) 183 (36.74%), followed by "other" (n = 35, 7.02%), generalized tonic-clonic seizure (GTCS) 3 (0.60%), and focal awareness seizure (FAS) 2 (0.40%). Anterior temporal lobectomy was the most common type of surgery performed (n = 417, 83.73%), followed by SAH (n = 55, 11.04%), lesionectomy (n = 20, 4.01%), and "other" (n = 6, 1.20%) (Table 1). Over years of follow-up, we evaluated the outcomes of epilepsy surgery using the Engel classification and stratified patients into a seizure-free group and a group with seizure. Flow-chart of this study was presented in Fig. 1.

Using the Pearson Chi-Square test, we analyzed the correlation of each variable with seizure outcomes. The only variable found to correlate with seizure outcome was the presence of aura (Table 2). We analyzed the correlation between aura and seizure-free status after TLE surgery. The results showed that patients with positive preoperative aura were 1.74-fold more likely to be seizure-free after TLE surgery (p = 0.03, Odd Ratio (OR): 1.74) (Table 3).

We compared patients with positive vs. negative preoperative aura in terms of mean age at the time of initial seizure onset. Mean age at the time of initial seizure onset was 12.35 + 7.01 years in those with positive preoperative aura and 10.70 + 7.22 years in those with negative preoperative aura (p = 0.04, 95% confidence interval (CI): 0.55–3.24). These results indicate that patients with positive preoperative aura have a later onset of epilepsy, compared with those with negative preoperative aura (Table 4).

Between-group comparisons revealed that those with a longer duration of disease were less likely to be seizure-free after TLE surgery, compared with those with a shorter duration of disease [12.018.00 years in the seizure-free group vs. 13.959.29 years in the group with seizure; p = 0.04, 95% CI: -3.85(-0.02)] (Table 5).

3.2. Correlation between preoperative aura subtype and outcomes after TLE surgery

We stratified the 386 patients included in the study based on preoperative aura subtypes: autonomic, sensory, mental and affective, or multiple manifestations. A total of 118 patients (30.6%) were classified as having preoperative autonomic aura. Among this group, palpitation was reported by 41, Gastro Intestinal (GI) issues by 65, and suffocation by 12. A total of 47 patients (12.2%) were classified as having

Table 1
Demographic characteristics of patients who underwent TLE surgery.

| Variable | | N (%) | Median (min-max) |
|-------------------|---------------------|-------------|------------------|
| Sex | Male | 196 (39.35) | |
| | Female | 302 (60.64) | |
| Age | Age | | 23 (2-62) |
| | Age at onset | | 11 (0.16-40) |
| | Duration of disease | | 10 (1-62) |
| Preoperative aura | Positive aura | 386 (77.51) | |
| | Negative aura | 112 (22.48) | |
| Seizure semiology | FAS | 2 (0.40) | |
| | FIAS | 275 (55.22) | |
| | FBTCS | 183 (36.74) | |
| | GTCS | 3 (0.60) | |
| | Others | 35 (7.02) | |
| | Type of surgery | ATL | 417 (83.73) |
| | SAH | 55 (11.04) | |
| | Lesionectomy | 20 (4.01) | |
| | Others | 6 (1.20) | |

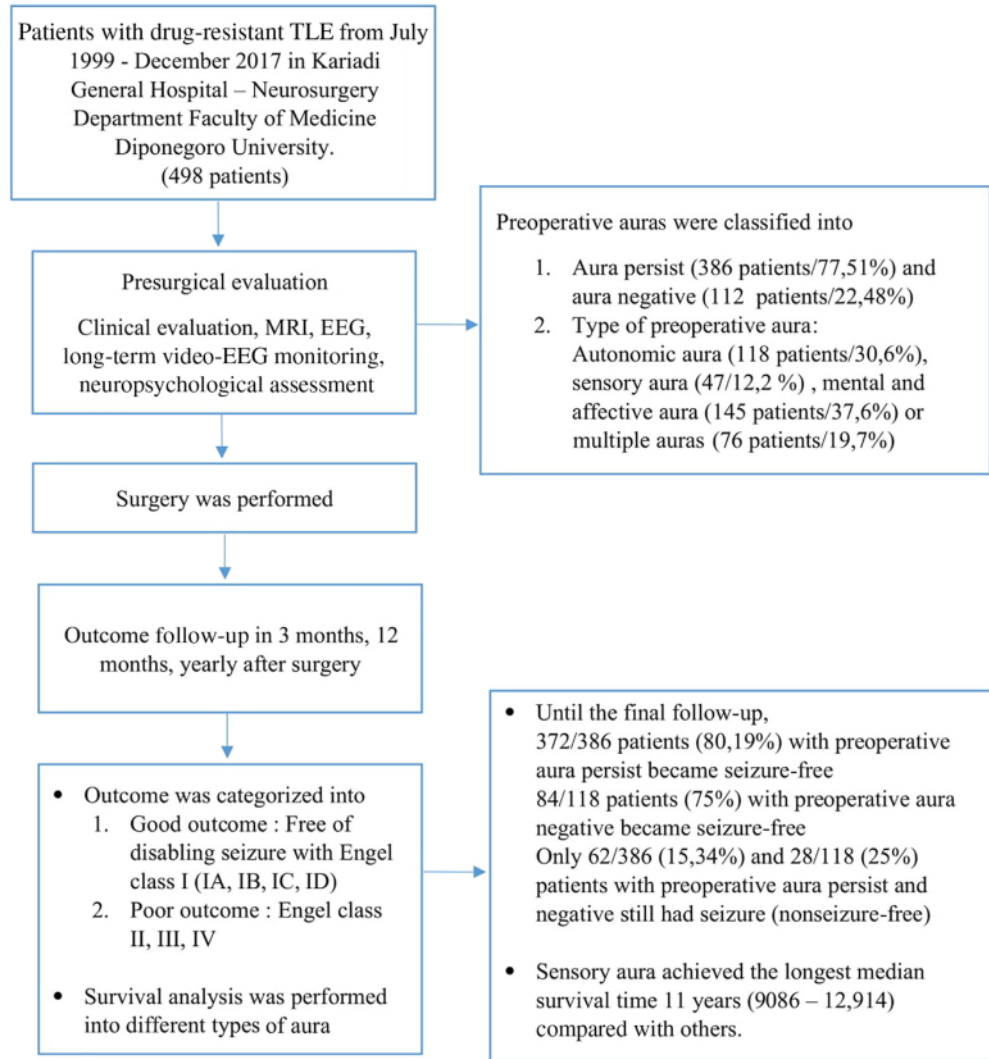


Fig. 1. Flow-chart study.

preoperative sensory aura. Among this group, visual aura was reported by 16 patients, olfactory aura by 1 patient, gustatory aura by 0 patients, auditory aura by 2 patients, and general somatosensory aura by 28 patients. A total of 145 patients (37.6%) were classified as having preoperative mental and affective aura. Among this group, feelings of fear were reported by 22 patients, depressed mood by 2 patients, experimental sensory (deja vu) by 55 patients, vertigo by 1 patient, cognitive aura

Table 2
Correlations with seizure outcome in patients with TLE.

| | p |
|----------------------|--------|
| Type of seizure | 0.529 |
| Preoperative aura | 0.030* |
| Type of operation | 0.195 |
| Duration of epilepsy | 0.299 |
| Sex | 0.104 |

* Significant difference, $p < 0.05$.

Table 3
Correlation between preoperative aura and seizure-free status after TLE surgery.

| | | Event of seizure after TLE surgery | | p-Value | OR |
|-------------------|----------|------------------------------------|------------|---------|------|
| | | Seizure-free | Seizure | | |
| Preoperative aura | Positive | 324 (80.19) | 62 (15.34) | 0.03* | 1.74 |
| | Negative | 84 (75) | 28 (25) | | |

* Significant difference, $p < 0.05$.

Table 4
Mean age at onset of initial seizure in patients with positive vs. negative preoperative aura after TLE surgery.

| Preoperative aura | | N (mean ± SD) | p-Value | 95% CI |
|-------------------|-------------------|---------------|---------|--------|
| | | Positive | | |
| Negative | 95 (10.70 ± 7.22) | | | |

* Significant difference, $p < 0.05$.

Table 5
Correlation between duration of disease and seizure-free status after TLE surgery.

| | N (mean ± SD) | p-Value | 95% CI |
|--------------|--------------------|---------|---------------|
| Outcome | | | |
| Seizure-free | 397 (12.01 ± 8.00) | 0.04* | -3.85 (-0.02) |
| Seizure | 87 (13.95 ± 9.29) | | |

* Significant difference, $p < 0.05$.

by 9 patients, and unspeakable feeling/malaise (odd feeling) by 54 patients. Preoperative multiple aura manifestations were reported by 76 patients (19.7%) (Table 6).

We used Kaplan–Meier analysis to predict median overall survival time and to compare outcomes among aura subgroups. The results showed that median time without a seizure after TLE surgery was 10 years for those with preoperative autonomic aura (95% CI: 8.327–11.673 years), 11 years for those with preoperative sensory aura (95% CI: 9.086–12.914 years), 9 years for those with preoperative mental and affective aura (95% CI: 7.667–10.333 years), and 9 years for those with preoperative multiple aura manifestations (95% CI: 7.692–10.887 years) ($p = 0.022$) (Table 7).

In the preoperative autonomic aura group, the likelihood of being seizure-free after 3, 5, 10, and 15 years of follow-up was 94.8%, 84.0%, 48.4%, and 19.7%, respectively. In the preoperative sensory aura group, the likelihood of being seizure-free after 3, 5, 10, and 15 years of follow-up was 93.9%, 83.2%, 59.7%, and 30.1%, respectively. In the preoperative mental and affective aura group, the likelihood of being seizure-free after 3, 5, 10, and 15 years of follow-up was 90.3%, 77.6%, 42.5%, and 11.4%, respectively. In the preoperative multiple aura manifestations group, the likelihood of being seizure-free after 3, 5, 10, and 15 years of follow-up was 94.7%, 72.0%, 33.7%, and 12.1%, respectively (Table 8).

The results of Kaplan–Meier analysis showed significantly different outcomes among groups ($p = 0.022$). Preoperative sensory aura was associated with the greatest likelihood of seizure-free status after surgery for TLE, followed by the preoperative autonomic aura group, preoperative multiple auras groups, and preoperative mental and affective aura group (Fig. 2).

4. Discussion

The correlation between type of preoperative aura and surgical outcomes was examined in patients with TLE. The results showed that

Table 7
Seizure-free status among patients with different preoperative aura subtypes.

| Type of preoperative aura | Median survival time (95% CI) | p-Value |
|---------------------------|-------------------------------|---------|
| Autonomic | 10 (8.327–11.673) | 0.022* |
| Sensory | 11 (9.086–12.914) | |
| Mental and affective | 9 (7.667–10.333) | |
| Multiple | 9 (7.692–10.887) | |

* Significant difference, $p < 0.05$.

patients with positive preoperative aura who underwent TLE surgery had a 1.74-fold increase in the likelihood of seizure-free status. Patients with positive preoperative aura had a later onset of epilepsy than patients without preoperative aura. These results support those in previous studies, which showed that patients with medically refractory TLE-MTS who reported abdominal auras prior to seizures had better postoperative seizure control than those who did not report auras [6,9,10]. Seizure-free status is more common among patients with a shorter period of TLE disease, as reported previously [11,12]. People with shorter epilepsy duration are more likely to have seizure-free follow-up. In addition, there is a favorable correlation among shorter duration of disease and freedom from seizures among patients with relatively long durations of epilepsy. Patients who can benefit from epilepsy surgery should also be recommended for preliminary examination without further delay, regardless of the duration since the epilepsy diagnosis [6].

Patients with preoperative sensory auras had greater likelihood of remaining seizure-free during the follow-up period, followed by those with preoperative autonomic auras, preoperative multiple auras, and preoperative mental and affective auras. Similar findings were reported previously in a study that described favorable surgical outcomes in patients with TLE with somatosensory auras [13]. We conclude that preoperative sensory aura is a good indicator for seizure-free status postoperatively. Possible mechanism for the production of somatosensory aura is the spread of seizure activity from the temporal lobe to the perisylvian region by stimulation of the insular cortex or the second sensory area. The insular cortex has extensive connections to temporal lobe structures, and temporal lobe seizures tend to enter the insular cortex. After seizure in the temporal lobe, several anatomical regions can generate somatosensory phenomena. First, somatosensory auras may emerge directly from seizure activity in the temporal medial lobe. The

Table 6
Preoperative aura types among patients who underwent TLE surgery.

| Manifestations | Number of patients | Percentage | Areas with abnormal electroencephalography | | | | | Nonlesional findings |
|-----------------------------------|--------------------|------------|--|---------|----------|----------|-----------|----------------------|
| | | | Frontal | Central | Parietal | Temporal | Occipital | |
| Autonomic auras | | | | | | | | |
| • Palpitation | 41 | 10.6% | 6 | 1 | 2 | 37 | 0 | 1 |
| • GI | 65 | 16.8% | 5 | 1 | 0 | 64 | 0 | 0 |
| • Suffocation | 12 | 3.1% | 1 | 0 | 0 | 11 | 0 | 0 |
| Total | 118 | 30.6% | 12 | 2 | 2 | 112 | 0 | 1 |
| Sensory auras | | | | | | | | |
| • Visual | 16 | 4.1% | 0 | 0 | 0 | 16 | 0 | 0 |
| • Olfactory | 1 | 0.3% | 0 | 0 | 0 | 1 | 0 | 0 |
| • Gustatory | 0 | 0.0% | 0 | 0 | 0 | 0 | 0 | 0 |
| • Auditory | 2 | 0.5% | 0 | 0 | 0 | 2 | 0 | 0 |
| • General somatosensory | 28 | 7.3% | 5 | 0 | 0 | 27 | 0 | 0 |
| Total | 47 | 12.2% | 5 | 0 | 0 | 46 | 0 | 0 |
| Mental and affective auras | | | | | | | | |
| • Feeling of fear | 22 | 5.7% | 4 | 0 | 0 | 21 | 0 | 0 |
| • Depressed mood | 4 | 1.0% | 0 | 0 | 0 | 4 | 0 | 0 |
| • Experiential sensory | 55 | 14.2% | 6 | 0 | 0 | 55 | 1 | 0 |
| • Vertigo | 1 | 0.3% | 0 | 0 | 0 | 1 | 0 | 0 |
| • Cognitive auras | 9 | 2.3% | 0 | 0 | 0 | 9 | 0 | 0 |
| • Unspeakable feeling/malaise | 54 | 14.0% | 7 | 2 | 1 | 51 | 1 | 0 |
| Total | 145 | 37.6% | 17 | 2 | 1 | 141 | 2 | 0 |
| Multiple symptoms | | | | | | | | |
| Total | 386 | 100.0% | 44 | 6 | 4 | 373 | 3 | 1 |

Table 8
Likelihood of seizure-free status after TLE surgery.

| Preoperative aura type | Likelihood of seizure-free status (%) | | | |
|------------------------|---------------------------------------|---------|----------|----------|
| | 3 years | 5 years | 10 years | 15 years |
| Autonomic | 94.8 | 84.0 | 48.4 | 19.7 |
| Sensory | 93.9 | 83.2 | 59.7 | 30.1 |
| Mental and affective | 90.3 | 77.6 | 42.5 | 11.4 |
| Multiple | 94.7 | 72.0 | 33.7 | 12.1 |

10 electrical stimulation of discrete mesial temporal structures in patients undergoing brain surgery may induce somatosensory aura or numbness. Induced somatosensory anomalies may be positive or negative and may occur unilaterally or bilaterally [14–16]. Somatosensory phenomena associated with temporal lobe seizures are considered by some investigators to be a proxy for neocortical or lateral lobe seizures [17]. The most important clinical consequences of this research are that preoperative auras with somatosensory signs do not necessarily imply extratemporal seizure onset. We found that patients with preoperative somatosensory aura associated with TLE had a favorable prognosis for seizure remission after partial temporal lobe resection. Thus, the frequency of preoperative somatosensory aura, whether bilateral or unilateral, should not serve as a barrier to temporal lobe resection in patients with refractory epilepsy in whom etiology and/or electrophysiological and imaging findings support a unilateral temporal lobe seizure focus.

20 There were several limitations to our report. First, this was a single-center analysis. A multicenter study with a wider group of patients from different institutions or areas is required to further analyze aura subtype and its association with epilepsy outcomes. Second, all of our patients were tested by scalp EEG, not intracranial EEG, which renders our conclusion less reliable.

5. Conclusion

Patients who underwent TLE surgery with positive preoperative aura had a 1.74-fold increase in the likelihood of seizure-free status postoperatively, compared with patients who had seizures during the postoperative period. Patients who had positive preoperative aura also had later onset of epilepsy than patients without preoperative aura. In the case of patients with TLE with positive preoperative aura who are candidates for surgery, the greatest likelihood of seizure-free status postoperatively is observed in those with preoperative sensory aura, followed by those with preoperative autonomic aura, those with preoperative multiple auras, and those with preoperative mental and affective auras. Preoperative sensory auras are a good predictor of seizure-free status and better outcomes after TLE surgery.

Author contributions

2 Muhamad Thohar Arifin: conception and design of the study, data analysis, preparation of the manuscript, final drafting/proofing.

Ryosuke Hanaya: collection of data, critical revision, manuscript editing.

Yuriz Bakhtiar: collection of data, reanalysis of statistical results, graphics.

Aris Catur Bintoro, Koji Iida, Kaoru Kurisu, Kazunori Arita Zainal Muttaqin: critical revision, final manuscript editing.

6 Jacob Bunyamin: Rofat Askoro, Surya P Brilliantika: statistical analysis, data analysis, analysis of surgical outcomes, editing the manuscript.

Funding

This research did not receive any specific grant from funding agencies in the public, commercial, or not-for-profit sectors.

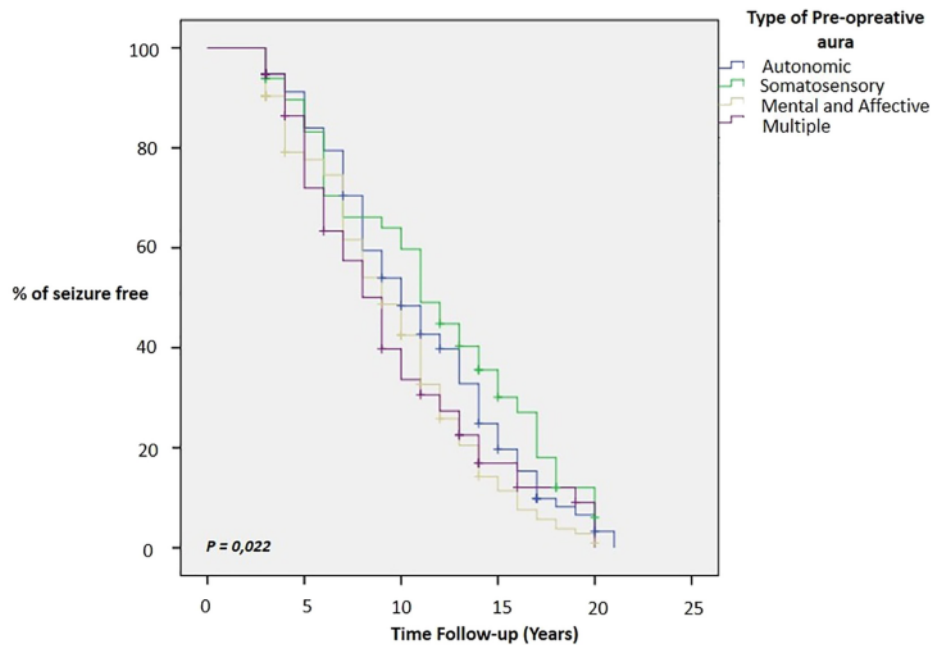


Fig. 2. Kaplan–Meier plot for survival free of seizures, according to aura type.

Declaration of competing interest

No relevant conflict of interest was reported by the authors for this study. We confirm that we have read the Journal's position on issues involved in ethical publication and affirm that this report is consistent with those guidelines.

Acknowledgment

We would like to thank all medics, paramedics, staff, and patients involved in our epilepsy surgery program and Dr. Sopiudin Dahlan who helped with statistical analysis.

References

- [1] Panayiotopoulos CP. A clinical guide to epileptic syndromes and their treatment. 2nd ed.. New York: Springer; 2010; 24.
- [2] Niedemeyer E. The Epilepsies. Diagnosis and management. Baltimore, Munich: USA: Urban and Schwarzenberg; 1990. p. 70.
- [3] Spencer D. Auras are frequent in patients with generalized epilepsy. *Epilepsy Curr*. 2015;15:75–7. <https://doi.org/10.5698/1535-7597-15.2.75>.
- [4] Henkel A, Noachtar S, Pfänder M, Lüders HO. The localizing value of the abdominal aura and its evolution: a study in focal epilepsies. *Neurology*. 2002;58:271–6. <https://doi.org/10.1212/WNL.58.2.271-1526-632X>.
- [5] Schulze-Bonhage A, Kurth C, Carius A, Steinhoff BJ, Mayer T. Seizure anticipation by patients with focal and generalized epilepsy: a multicentre assessment of premonitory symptoms. *Epilepsy Res*. 2006;70:83–8. <https://doi.org/10.1016/j.epilepsyres.2006.02.001>.
- [6] Asadi-Pooya AA, Nei M, Sharan A, Sperling MR. Type of preoperative aura may predict postsurgical outcome in patients with temporal lobe epilepsy and mesial temporal sclerosis. *Epilepsy Behav*. 2015;50:98–100. <https://doi.org/10.1016/j.yebeh.2015.06.041>.
- [7] West S, Nolan SJ, Cotton J, Gandhi S, Weston J, Sudan A, et al. Surgery for epilepsy. *Cochrane Database Syst Rev*. 2015;7:CD010541.
- [8] Kovanda TJ, Tubbs RS, Cohen-Gadol AA. Transsylvian selective amygdalohippocampectomy for treatment of medial temporal lobe epilepsy: surgical technique and operative nuances to avoid complications. *Surg Neurol Int*. 2014;5 Supplement.
- [9] Asadi-Pooya AA, Nei M, Sharan A, Sperling MR. Auras in patients with temporal lobe epilepsy and mesial temporal sclerosis. *J Neurol Sci*. 2016;364:24–6. <https://doi.org/10.1016/j.jns.2016.03.006>.
- [10] Adry RARC, Meguins LC, Pereira CU, Silva Júnior SC, Araújo Filho GM, Marques LHN. Auras as a prognostic factor in anterior temporal lobe resections for mesial temporal sclerosis. *Eur J Neurol*. 2018;25(11):1372–7. <https://doi.org/10.1111/ene.13740>.
- [11] Meguins LC, Adry RA, Silva-Junior SC, Araújo Filho GM, Marques LH. Shorter epilepsy duration is associated with better seizure outcome in temporal lobe epilepsy surgery. *Arq Neuropsiquiatr*. 2015;73(3):212–7. <https://doi.org/10.1590/0004-282X20140230>.
- [12] Bjellvi J, Olsson I, Malmgren K, Wilbe Ramsay K. Epilepsy duration and seizure outcome in epilepsy surgery: a systematic review and meta-analysis. *Neurology*. 2019; 93(2):e159–66. <https://doi.org/10.1212/WNL.0000000000007753>.
- [13] Erickson JC, Clapp LE, Ford G, Jabbari B. Somatosensory auras in refractory temporal lobe epilepsy. *Epilepsia*. 2006;47(1):202–6. <https://doi.org/10.1111/j.1528-1167.2006.00388.x>.
- [14] Fish DR, Gloor P, Quesney L, Olivier A. Clinical responses to electrical brain stimulation of the temporal and frontal lobes in patients with epilepsy. *Brain*. 1993;116: 397–414.
- [15] Friedman DP, Murray EA, O'Neill JB, Mishkin M. Cortical connections of the somatosensory fields of the lateral sulcus of macaques: evidence for a corticolimbic pathway for touch. *J Comp Neurol*. 1986;252:323–47.
- [16] Isnard J, Guenet M, OstrowskyK, et al. The role of the insular cortex in temporal lobe epilepsy. *Ann Neurol*. 2000;48:614–23.
- [17] Elwan S, Alexopoulos A, Silveira DC, Kotagal P. Lateralizing and localizing value of seizure semiology: comparison with scalp EEG, MRI and PET in patients successfully treated with resective epilepsy surgery. *Seizure*. 2018;61:203–8. <https://doi.org/10.1016/j.seizure.2018.08.026>.

Preoperative sensory aura predicts risk for seizure in temporal lobe epilepsy surgery

ORIGINALITY REPORT

17%

SIMILARITY INDEX

10%

INTERNET SOURCES

15%

PUBLICATIONS

1%

STUDENT PAPERS

PRIMARY SOURCES

- 1** [docplayer.net](#) 4%
Internet Source
- 2** Ashalatha Radhakrishnan, Ramshekhar Menon, Sanjeev V. Thomas, Mathew Abraham et al. "'Time is Brain"- How early should surgery be done in drug-resistant TLE?", Acta Neurologica Scandinavica, 2018 3%
Publication
- 3** [n.neurology.org](#) 1%
Internet Source
- 4** Perven, Ghazala, Ruta Yardi, Juan Bulacio, Imad Najm, William Bingaman, Jorge Gonzalez-Martinez, and Lara Jehi. "The relevance of somatosensory auras in refractory temporal lobe epilepsies", Epilepsia, 2015. 1%
Publication
- 5** [repositorio.unicamp.br](#) 1%
Internet Source

| | | |
|----|---|------|
| 6 | arxiv.org Internet Source | 1 % |
| 7 | "December 9, 2003", <i>Epilepsia</i> , 10/2003 Publication | 1 % |
| 8 | jdc.jefferson.edu Internet Source | 1 % |
| 9 | www.actaitalica.it Internet Source | 1 % |
| 10 | Jay C. Erickson, Lawrence E. Clapp, Gwendolyn Ford, Bahman Jabbari. "Somatosensory Auras in Refractory Temporal Lobe Epilepsy", <i>Epilepsia</i> , 2006 Publication | <1 % |
| 11 | archive.org Internet Source | <1 % |
| 12 | www.e-sc.org Internet Source | <1 % |
| 13 | www.sjkdt.org Internet Source | <1 % |
| 14 | Maha Gashlan, D. Keene, Inge Loy-English, Enrique C. G. Ventureyra. "Predictors of seizure outcome following cortical resection in pediatric and adolescent patients with medically refractory epilepsy", <i>Child's Nervous System</i> , 1999 Publication | <1 % |

15 "AES Proceedings. Annual Meeting of the American Epilepsy Society San Diego, California, December 6-9, 1998", *Epilepsia*, 6/1998
Publication <1 %

16 www.aetna.com
Internet Source <1 %

17 "Abstracts", *Epilepsia*, 2012
Publication <1 %

18 es.scribd.com
Internet Source <1 %

19 koreascience.or.kr
Internet Source <1 %

20 Lasse Dührsen, Thomas Sauvigny, Patrick M. House, Stefan Stodieck et al. "Impact of focal cortical dysplasia Type IIIa on seizure outcome following anterior mesial temporal lobe resection for the treatment of epilepsy", *Journal of Neurosurgery*, 2018
Publication <1 %

21 Musa M. Watila, Fenglai Xiao, Mark R. Keezer, Anna Miserocchi, Andrea S. Winkler, Andrew W. McEvoy, Josemir W. Sander. "Epilepsy surgery in low- and middle-income countries: A scoping review", *Epilepsy & Behavior*, 2019
Publication <1 %

22

Submitted to University of Liverpool

Student Paper

<1 %

23

epdf.pub

Internet Source

<1 %

24

Hidenori Sugano, Yasushi Iimura, Ayuko Igarashi, Mika Nakazawa et al. "Extent of Leptomeningeal Capillary Malformation is Associated With Severity of Epilepsy in Sturge-Weber Syndrome", *Pediatric Neurology*, 2021

Publication

<1 %

25

R. A. R. C. Adry, L. C. Meguins, C. U. Pereira, S. C. Silva Júnior, G. M. Araújo Filho, L. H. N. Marques. "Auras as a prognostic factor in anterior temporal lobe resections for mesial temporal sclerosis", *European Journal of Neurology*, 2018

Publication

<1 %

26

Asadi-Pooya, Ali A., Cyrus Rostami, Amin H. Rabiei, and Michael R. Sperling. "Factors associated with tonic-clonic seizures in patients with drug-resistant mesial temporal epilepsy", *Journal of the Neurological Sciences*, 2015.

Publication

<1 %

27

Jay C. Erickson. "Somatosensory Auras in Refractory Temporal Lobe Epilepsy", *Epilepsia*, 1/2006

Publication

<1 %

Exclude quotes On

Exclude matches Off

Exclude bibliography On

Preoperative sensory aura predicts risk for seizure in temporal lobe epilepsy surgery

GRADEMARK REPORT

FINAL GRADE

/0

GENERAL COMMENTS

Instructor

PAGE 1

PAGE 2

PAGE 3

PAGE 4

PAGE 5

PAGE 6
