

Phlebotropic Effect of Graptophyllum Pictum (L.) Griff on Experimental Wistar Hemorrhoids

by Yan Wisnu Prajoko

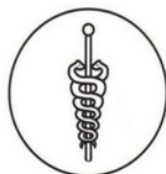Submission date: 13-Jan-2021 09:20AM (UTC+0700)

Submission ID: 1486644360

File name: Phlebotropic_Effect.pdf (280.2K)

Word count: 3026

Character count: 15911



JOURNAL OF BIOMEDICINE AND TRANSLATIONAL RESEARCH

Copyright ©2019 by Faculty of Medicine Diponegoro University and Indonesian Medical Association, Central Java Region

Research Article

Phlebotropic Effect of *Graptophyllum pictum* (L.) Griff. on Experimental Wistar Hemorrhoids

Mario Sadar Bernitho Hutagalung¹, Parish Budiono², Sigit Adi Prasetyo², Ignatius Riwanto^{2*}, Eriawan Agung Nugroho², Yan Wisnu², Neni Susilaningsih³

¹ Department of Surgery, Faculty of Medicine Diponegoro University, Semarang, Indonesia

² Department of Surgery, Faculty of Medicine Diponegoro University, Semarang, Indonesia

³ Department of Histology, Faculty of Medicine Diponegoro University, Semarang, Indonesia

Article Info

History

Received : 13 Nov 2018

Accepted : 17 March 2019

Available : 25 July 2019

Abstract

Background : *Graptophyllum pictum* extract (GPE) has already been used widely in Indonesia to treat hemorrhoid with good result, however, the mechanism is not supported by the molecular research. GPE has the potential effect as an anti-hemorrhoidal drug through the phlebotropic mechanism.

Objective : To study the phlebotropic effects of GPE by measuring the degree of edema and extra vassal leucocytes of experimental Wistar hemorrhoid.

Methods : An experimental study in male Wistar rats, weight around 200 gr, induced for the development of a disease-like condition of hemorrhoids by 6% croton oil induction on the anus for 3 days. Fourteen Wistar rat were randomly allocated into 2 groups. Group I got normal saline, group II was treated with GPE 100mg/kgbw, started on day 4th for 5 consecutive days. On 9th day blood was extracted from retroorbital fossa and anus was resected up to 2 cm from anal verge and weighted. The degree of anal edema was measured by recto anal coefficient and the number of extra vassal leucocytes was measured from HE staining of anal specimen under 400 HPF. All of the data showed normal distribution, therefore, pool t-test was used to test the mean difference between groups.

Results : The mean (\pm SD) of recto anal coefficient in the treatment group was 2.46 (\pm 0.41) and it was significantly lower than control group (3.13 \pm 0.85) (p = 0.029). The mean (\pm SD) of extra vassal leukocytes in the treatment group was 900.14 (\pm 48.09) and it was significantly lower than the control (1003.28 \pm 99.30) (p = 0.042).

Conclusions : *Graptophyllum pictum* extract shows a phlebotropic effect in terms of decreased recto anal coefficient (edema) and decreased of extra vassal leukocytes in Wistar rats.

Keywords : *Graptophyllum pictum*; hemorrhoids; croton oil; recto anal coefficient; extra vassal leucocytes

Permalink/ DOI: <https://doi.org/10.14710/jbtr.v5i1.3704>

INTRODUCTION

The number of patients diagnosed with hemorrhoids is increasing annually. Treatment options are based on their pathological degree. First, 2nd and small 3rd degree of hemorrhoid can be managed non-operatively.⁴ Medical treatment given is a drug that has the effect of being anti-inflammatory and phlebotropic.^{2,5}

Micronized purified flavonoid fraction (MPFF) has been known to reduce the symptoms of bleeding, pain, and recurrence of hemorrhoids,^{11,12} the effectiveness has already been proved on meta-analysis of RCT study.⁸ However, this drug is not included yet in the Indonesian national formulary, therefore it is not allowed to be given to patients covered by national insurance.

Graptophyllum pictum (L.) Griff. or purple leaves extract has been widely used in Indonesia as an alternative medicine to treat several kinds of diseases,

* Corresponding author:

E-mail: iriwanto@gmail.com (Ignatius Riwanto)

including hemorrhoid, is potential to be developed as an alternative hemorrhoid therapy. Purple leaves contain alkaloids, flavonoids, tannins and steroids and antioxidants. The entire content above will be produced well by extracting with 70% ethanol.⁶ Review of various studies conducted by Singh et al., showed that purple leaves contain alkaloids, glycoside, pectin, formic acid, steroids, saponins, tannins, flavonoids and alcohol.¹⁰ Purple leaves as anti-inflammatory have been proven to play a role, through intervention studies in experimental rats, and concluded that the strength is equivalent to indomethacin.^{7,8,9} An experimental study in rats which also made artificial hemorrhoids by anal induction with 6% croton oil, but treated with topical cream a combination of several herbal extracts showed anti-inflammatory and antioxidant effects compared to control.¹⁰ Referring to previous studies, purple leaf has the potential to be developed as an anti-hemorrhoidal drug as anti-inflammatory and phlebotropic. The previous study on Wistar rat use *Graptophyllum pictum* (L.) Griff. extract at dose 100 mg, 150 mg and 200 mg/kg body weight, and at dose 100 mg/kg body weight had already shown to reduce the blood level of TNF- α and IL-6 significantly,¹⁰ therefore this study used dose 100 mg/kg body weight. This study is expected to show the role of purple leaves even deeper as phlebotropic in terms of reducing vascular leak by measuring number of leukocyte extra-vassal and degree of anal edema.

MATERIALS AND METHODS

Subject

This study was an animal experimental research model. The animal were healthy male adult Wistar rats at the age of 10-12 weeks, with the weight around 200 g. The Wistar were obtained from the animal house unit of the Lembaga Pengembangan Penelitian Terapan (LPPT) University of Gajahmada, Jogjakarta, and the experiment was also done in LPPT. The animal were excluded if during 7 days observation appeared to be sick or death. All rats came from the same strain, and received the same treatment during the trial period. Both the control group and the treatment group were given the same amount of food and drink and were placed in 2 different cages. Guide for the care and use of Laboratory Animals were applied completely to all Wistar rats under experiment.¹⁵ We used "resource equation" method to calculate the sample size.¹⁶ According to this method a value "E" is the degree of freedom of analysis of variance. The value of E should lie between 10 and 20. E can be measured by following formula: $E = \text{Total number of animals} - \text{Total number of groups}$. In our study the total number of animals were 14, and total number groups were 2, mean E was 12, it is meet the requirement. This study has obtained Ethical Clearance from "Komisi Etik Penelitian Kesehatan, Fakultas Kedokteran Universitas Diponegoro dan RSUP dr Kariadi Semarang" no 72/EC/H/FK-RSDK/IX/2017.

Croton oil

The croton oil was provided from Sigma Aldrich company, catalog number C6719-10G. Croton oil for anal application was prepared as combine mixture of Deionized water, pyridine, diethyl ether, and 6% croton oil in diethyl ether at a ratio of 1: 4: 5: 10. The night

before, all of the Wistar were refrained from foods, and then with sterile cotton, 6% croton oil were put into the anus at 1.5 cm deep and maintained for 30 seconds, in 3 consecutive days¹⁵.

Graptophyllum pictum (L.) Griff. extract

Graptophyllum pictum (GP) is member of Acanthaceae family or *Justicia picta*, is believe to be native of New Guinea,¹⁰ but nowadays it can be found in tropical country including Indonesia. GP leaves were harvested from the Sido Muncul herbal medicine factory farm, in Semarang, Indonesia. The extraction processes were also done in this factory. GP powder was extracted with 70% ethanol using soxhlet extractor, which was then concentrated in a vacuum container to achieve 95% concentration, and stored at 15-20° C.^(18,19) The dose of GPE was 100 mg/kg given twice daily intravenous, as already been used by the previous research.^{17,20}

Experimental design

On the day 4, the day after finishing anal induction with 6% croton oil, the Wistar rats were randomly allocated into 2 groups. Group I (control), starting from the 4th day was given physiological saline for 5 consecutive days. Group II (treatment group), on the 4th days was given GPE at a dose of 100 mg/kgbw for 5 consecutive days. GPE was given intravenously.

During the treatment period, all animals were cage based on group and feed accordingly with plenty water. On the 9th day after induction, all rats were terminated by cervical dislocation under ether anesthesia. The Wistar rat was weighted by using gram scales. The anus was resected up to 2 cm above anal verge, and weight by using milligram scales. The anal specimen was saved in the formalin buffer container, and preparing for microscopic examination by HE staining under 400 HPF.

To evaluate the edema, because the walls are very thin, it is not accurate if the anal wall is measured with a millimeter ruler. It was believed that edema will increase the anal weight, and anal weight will also dependent to the Wistar weight. Therefore, recto anal coefficient would be more reliable. Based on previous study, the degree of anal edema could be measured using recto-anal coefficient, that is ratio between anal weight (in miligram) to Wistar body weight (in gram).¹⁷ This study examined extra vasa leukocyte counts and recto anal coefficient.

Statistical analysis

Both variables were normally distributed based on Kolmogorov-Smirnov test. Pool t test was used to test the differences on extra vasa leukocyte counts and recto anal coefficient between control and treatment groups.

RESULTS

All Wistar rats were still in good health until the end of the study. At the end of the experiment, we measured body weight using gram scales, where the control group was 173.84 ± 13.37 and the treatment group was 171.70 ± 13.10 , and statistically it was no significant different between the two groups ($p = 0.833$). Figure 1 showed that recto anal coefficients in the group of GPE was 2.46 ± 0.41 , and was significantly lower than the control group 3.13 ± 0.85 ($p = 0.029$). Figure 2 showed that number of

extra vassal leukocyte in the group GPE was 900.14 ± 48.09 and was significantly lower than the control group 1003.28 ± 99.30 ($p=0.042$).

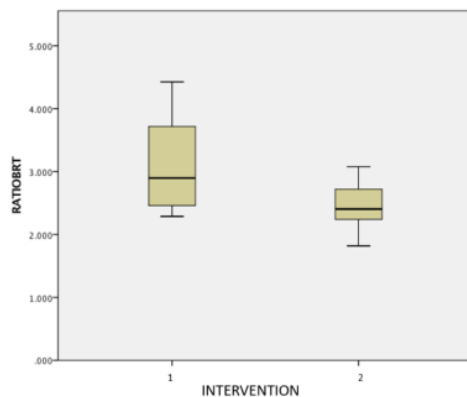


Figure 1. Recto anal coefficients in the GPE group (2) was 2.46 ± 0.41 and control group (1) was 3.13 ± 0.85 , (pool t test $p = 0.029$).

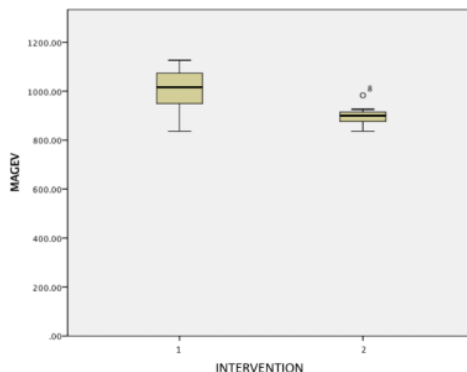


Figure 2. Number of extra vassal leukocytes in the GPE group (2) was 900.14 ± 48.09 , and the control group (1) was 1003.28 ± 99.30 , (pool t test $p = 0.042$)

DISCUSSION

This experimental research can be carried out well, because 14 male Wistar rats aged 2-3 months, which were randomized into 2 groups (each of 7 tails), could survive all at the end of the study and all seemed healthy and active. This research is to see the phlebotropic effect of purple leaf extract. Second hemorrhoid degree arised as a result of the induction of 6% croton oil, and inflammation in the anus occurred, where one component is edema due to vascular leakage, so that the anal wall would be thicker and heavier¹⁵. Acute inflammation resembled to acute hemorrhoid. Using 6% croton oil to induce hemorrhoid was in accordance with previous research.^(21, 22) Irritation by croton oil may damage mucous cell that will release alarmin or danger associated molecular patterns (DAMPs). DAMPs has capacity to induce innate and adaptive immunity by activating inflammation-related pathways. The proinflammatory interleukin induce vasodilatation and vascular leak.⁽²³⁾

In this study, purple leaves has a significantly lower recto anal coefficient than the control group, which was indicated by reduced edema after administration of purple leaf extract 100 mg / kg body weight. Because edema occurs due to vascular leakage, so it can be said, purple leaves have a phlebotropic effect. The presence of leukocyte extravasation is also an indicator of a state of vascular leakage and inflammation³. In this study, the number of extra vassal leukocytes was significantly lower in the group of purple leaf extracts compared to the control group. This can be concluded that administration of 100 mg/kgbw of purple leaf extract can reduce leukocyte extravasation, and purple leaf has plebophtopic effect. It was in accordance with the research of Ozaki et al and Sari et al.^{11,12}

Mechanism of decreasing edema and extravasal leukocyte by purple leaf extract is not known yet. The active component of purple leaf extract is flavonoid. MPFF significantly reduced the extent of pain and bleeding in the selected subjects of this study with acute haemorrhoids. The active component of MPFF is also flavanoid, therefore it can be suspected that the mechanism action of purple leaf extract may be resemble with MPFF. From the review of previous study, MPFF inhibits endothelial activation and prevents inflammatory cascade resulting from leukocyte-endothelium interaction.²⁴ Curcumin from curcuma longa, sulfuraphane and iberin from cruciferous vegetables have anti inflammatory effect through their antagonist activity of Toll-Like Receptor 4.^(24,25) Study to know whether MPFF has Toll-Like Receptor 4 antagonist activity should be done.

CONCLUSION

Purple leaf extract shows a phlebotropic effect on artificial hemorrhoids of Wistar rats by decreasing recto anal coefficient and decreasing extra vassal leukocytes. Further study to elaborate the role of purple leaves extract on inhibiting endothelial activation or has Toll-Like Receptor 4 antagonist activity is proposed.

ACKNOWLEDGEMENTS

Thank you to the Diponegoro University Faculty of Medicine for funding this research, based on research contract No:398/UN7.3.4/D/PG/2017. Thank you to LPPT UGM for providing the Wistar rats and place for implementation of this research, based on contract no 13.01/VII/UN1/LPPT/2017, and the Anatomical Pathology department of Diponegoro National Hospital which has helped microscopic evaluation of extra vassal leukocytes. Thank also addressed to PT Sidomuncul who has donated purple leaf extract for this research.

REFERENCES

1. Kaidar-Person, Orit, Benjamin Person and SDW. Hemorrhoidal disease: a comprehensive review. J Am Coll Surg. 2017;204(1):102–17.
2. Lohsiriwat V. Hemorrhoids: From basic pathophysiology to clinical management. World J Gastroenterol. 2017;18(17):2009–17.
3. Han, W. et al. Pathologic change of elastic fibers with difference of microvessel density and expression of angiogenesis-related proteins in

- internal hemorrhoid tissues. *Chinese J Gastrointest Surg.* 2010;8(1):56–9.
4. Davis BR, Lee-Kong SA, Migaly J, Feingold DL, Steele SR. The American Society of colon and rectal surgeons clinical practice guidelines for the management of hemorrhoids. *Dis Colon Rectum.* 2018;61(3):284–92.
 5. Sanchez C, Chinn BT. Hemorrhoids. *Clin Colon Rectal Surg.* 2011;1(212):5–13.
 6. A ba-bai-ke-re M, Huang HG, Re WN, Fan K, Chu H, Ai EHT et al. How we can improve patient's comfort after Milligan-Morgan open Hemorrhoidectomy. *World J Gastroenterol* 2011 March 21;17(11):1448-1456. Doi:10.3748/wjg.v17.i11.1448
 7. Bergan JJ, Diego S. Chronic Venous Insufficiency and the Therapeutic Effects of Daflon 500 mg. 2011;56:21–4.
 8. Alonso-Coello P, Zhou Q, Martinez-Zapata MJ, Mills E, Heels-Ansdell D, Johanson JF, et al. Meta-analysis of flavonoids for the treatment of haemorrhoids. *Br J Surg.* 2016;93(8):909–20.
 9. Winata H. 2011. "Aktivitas Antioksidan dan Kandungan Kimiawi Ekstrak Daun Wungu (*Graptophyllum pictum* L.Griff.)". Fakultas Matematika dan Ilmu Pengetahuan Alam. IPB. Bogor
 10. Azeemuddin M, Viswanatha GL, Rafiq M, Thippeswamy AH, Baig MR, Kavva KJ, et al. An improved experimental model of hemorrhoids in rats: evaluation of antihemorrhoidal activity of an herbal formulation. *ISRN Pharmacol* 2014; Article ID 530931:1-7. Doi 10.1155/2014/53093
 11. Sari DRP. Pengaruh Pemberian Ekstrak Daun Wungu (*Graptophyllum pictum* Griff) dan Pegagan (*Centella asiatica* (L.) Urb.) pada Penderita Wasir di Desa Payaman Solokuro Lamongan. *Dr Diss Univ AIRLANGGA.* 2011;
 12. Ozaki Y, Sekita S, Soedigdo S, Harada M. Antiinflammatory effect of *Graptophyllum pictum* (L.) Griff. *Chem Pharm Bull (Tokyo)* [Internet]. 2010;37(10):2799–802. Available from: <http://www.ncbi.nlm.nih.gov/pubmed/2611941>
 13. Sumarny, R., Rohani M. Efek antiinflamasi dan antidiare ekstrak etanol herba meniran (*Phyllanthus niruri* L.) dan daun wungu (*Graptophyllum pictum* L. Griff). *Pros Semin Nas Perkemb Terkini Sains Farm dan Klin III.* 2013;
 14. Gurel E, Ustunova S, Ergin B, Tan N, Caner M, Tortum O, et al. Herbal Haemorrhoidal Cream for Haemorrhoids. 2013;56(June 2011):253–62.
 15. Anonymous. Guide-for-the-Care-and-use-of-laboratory-animals. National academic press. 2010 (500 Fifth Street, NW Washington, DC 20001) www.national-academies.org
 16. Charan J and Kantharia ND. How to calculate sample size in animal studies. *J Pharmacol Pharmacother* 2013 Oct-Dec;4(4):303-306.
 17. Singh P, Khosa RL, Mishra Ga, Tahseen MA. A phytopharmacological review on *Justicia picta* (Acanthaceae): A well known tropical folklore medicinal plant. *Journal of Coastal Life Medicine* 2015;3(12):1000-2. Doi 10.12980/jclm.3.2015jclm-2015-0054
 18. Olagbende-Dada SO, Ukpo GE, and CHAB, S.A. A. Oxytocic and anti-implantation activities of the leaf extracts of *Graptophyllum pictum* (Linn.) Griff. (Acanthaceae). *African Journal of Biotechnology* 2015;8(21):5979-86. Doi <http://www.academicjournals.org/AJB>
 19. Srinivasan KK, Mathew JE, D'Silva KJA, Lobo R, Kumar N. Nephroprotective potential of *Graptophyllum pictum* against renal injury induced by gentamycin. *Iran J Basic Med Sci* 2015;18(4):412-7.
 20. Srinivasan KK, Mathew JE, Joseph K, Vachala SD, Malini S. Effect of ethanol extract of *Graptophyllum pictum* (L.) Griff. on cisplatin induced nephrotoxicity in rats. *Herba Polonica* 2011;57(2):51-63.
 21. Gurel E, Ustunova S, Ergin B, Tan N, Caner M, Tortum O, et al. Herbal haemorrhoidal cream for haemorrhoids. *Chin J Physiol* 2013;56(5):253-62. Doi 10.4077/CJP.2013.BAB127
 22. Al Ajmi MF, Al-Hadiya BM, K.E.H. E-T. Some pharmacological actions of *Myrica rubra* part 1: Effect on experimentally-induced gastric ulcers, inflammation and haemorrhoids in rats. *African Journal of Pharmacy and Pharmacology* 2013;7(9):512- 6. Doi 10.5897/ajpp12.1204
 23. Hirsiger S, Simmen HP, Werner CM, Wanner GA, Rittirsch D. Danger signals activating the immune response after trauma. *Mediators Inflamm* 2012; Article ID 315941:1-7. Doi 10.1155/2012/315941
 24. Jiang ZM, Jin-Duo C. The impact of micronized purified flavonoid fraction on the treatment of acute haemorrhoidal episodes. *Curr Med Res Opin* 2010 Jun;22(6):1141-7. Doi 10.1185/030079906X104803
 25. Aziz Z, Weng KH, Muhammad DBH, Wei LT, Saodah Y. Efficacy and tolerability of micronized flavonoid fractions (MPFF) for haemorrhoids: A systematic review and meta-analysis. *Comp Ther in Med* 2018 Aug;39(5):49-55.

Phlebotrophic Effect of Graptophyllum Pictum (L.) Griff on Experimental Wistar Hemorrhoids

ORIGINALITY REPORT

8%

SIMILARITY INDEX

4%

INTERNET SOURCES

6%

PUBLICATIONS

3%

STUDENT PAPERS

PRIMARY SOURCES

1

Submitted to Cork Institute of Technology

Student Paper

1%

2

Jiang, Zhu-Ming, and Jin-Duo Cao. "The impact of micronized purified flavonoid fraction on the treatment of acute haemorrhoidal episodes", Current Medical Research and Opinion, 2006.

Publication

1%

3

Zoriah Aziz, Weng Kit Huin, Muhammad Danish Badrul Hisham, Wei Ling Tang, Saodah Yaacob.. "Efficacy and tolerability of micronized purified flavonoid fractions (MPFF) for haemorrhoids: A systematic review and meta-analysis", Complementary Therapies in Medicine, 2018

Publication

1%

4

www.spandidos-publications.com

Internet Source

1%

5

Submitted to University of Queensland

Student Paper

1%

6	www.ijdr.in Internet Source	1%
7	www.ambulancenews.com Internet Source	1%
8	worldwidescience.org Internet Source	<1%
9	www.indexintelligence.org Internet Source	<1%
10	S Roy. "Anti-inflammatory activity of aqueous methanolic extract of Swietenia mahagoni (L.) Jacq. (Meliaceae) leaves", Oriental Pharmacy and Experimental Medicine, 03/31/2009 Publication	<1%
11	id.123dok.com Internet Source	<1%
12	Swaminathan Sundaresan, Michael R. Migden, Sirunya Silapunt. "Stasis Dermatitis: Pathophysiology, Evaluation, and Management", American Journal of Clinical Dermatology, 2017 Publication	<1%
13	"The nutraceutical effect of Scenedesmus dimorphus for obesity and nonalcoholic fatty liver disease–linked metabolic syndrome", Journal of Applied Pharmaceutical Science,	<1%

2020

Publication

14

Macarena Hernández-Jiménez, Carolina Peña-Martínez, María del Carmen Godino, Jaime Díaz-Guzmán, María Ángeles Moro, Ignacio Lizasoain. "Test repositioning for functional assessment of neurological outcome after experimental stroke in mice", PLOS ONE, 2017

Publication

<1%

15

Dian Arsanti Palupi, Fajrunida Nur Hasanah. "PENGARUH PEMBERIAN SUPLEMENTASI MINYAK ZAITUN TERHADAP PENURUNAN KETEBALAN EPITEL BRONKUS PADA MENCT ASMA YANG DIINDUKSI OVALBUMIN", Cendekia Journal of Pharmacy, 2018

Publication

<1%

Exclude quotes On

Exclude matches Off

Exclude bibliography On

Phlebotrophic Effect of Graptophyllum Pictum (L.) Griff on Experimental Wistar Hemorrhoids

GRADEMARK REPORT

FINAL GRADE

/0

GENERAL COMMENTS

Instructor

PAGE 1

PAGE 2

PAGE 3

PAGE 4
