

Effectiveness of nanosilver collagen cream for healing deep dermal burns in Sprague Dawley rats: an overview of neutrophil counts and angiogenesis

by Yan Wisnu Prajoko

Submission date: 10-Aug-2021 10:39AM (UTC+0700)

Submission ID: 1629793040

File name: Effectiveness_of_nanosilver...._artikel_tambh_dr_Yan_w_2.pdf (377.71K)

Word count: 3451

Character count: 18348

Effectiveness of nanosilver collagen cream for healing deep dermal burns in Sprague Dawley rats: an overview of neutrophil counts and angiogenesis



Krisna Muhammad^{1*}, Awal Prasetyo², Yan Wisnu Prajoko², Najatullah², Neni Susilaningsih²

¹Second Degree Student of Biomedical Science, General Surgery Resident of Medical Faculty, Universitas Diponegoro, dr. Kariadi General Hospital, Semarang, Indonesia;

²Biomedical Lecturer of Medical Faculty, Universitas Diponegoro, Semarang, Indonesia;

*Corresponding author:
Krisna Muhammad;

Second Degree Student of Biomedical Science, General Surgery Resident of Medical Faculty, Universitas Diponegoro, dr. Kariadi General Hospital, Semarang, Indonesia;

krisquall8584@gmail.com

Received: 2021-03-09

Accepted: 2021-07-15

Published: 2021-07-30

ABSTRACT

Background: Burn injuries remain the third cause of death in the world. The treatment, management of deep dermal burns is by applying topical medications like nanosilver collagen cream. Collagen is widely used for wound healing, cell development, angiogenesis, and platelets' activation. This study observed the effectiveness of the drug administration of nanosilver collagen cream compared to the silver sulfadiazine cream against the healing of deep dermal burns reviewed based on neutrophils counts and angiogenesis.

Methods: This study represents an experimental study of a laboratory with a randomized post-test with a control group design. The study used the Sprague Dawley mice to be divided equally into four randomly generated groups. Data were analyzed using SPSS version 20 for Windows.

Results: The Post-Hoc Mann Whitney test shows there is a significant difference in the angiogenesis between the 3rd and 6th-day groups such as group I ($p = 0.034$), II ($P = 0.009$), III ($P = 0.009$), and IV ($P = 0.009$). Kruskal-Wallis test also obtained that neutrophil counts decrease but not significant ($p = 0.159$) on day 3rd and ($p = 0.315$) dan day 6th administration of nanosilver collagen.

Conclusion: The administration of nanosilver collagen creams cannot decrease neutrophils counts significantly and administration of nanosilver collagen 2% increase angiogenesis compared to the silver sulfadiazine cream against the healing of deep dermal burns reviewed from the Sprague Dawley mice.

Keywords: Deep Dermal Burn, Collagen Nanosilver, Neutrophil, Angiogenesis.

Cite This Article: Muhammad, K., Prasetyo, A., Prajoko, Y.W., Najatullah., Susilaningsih, N. 2021. Effectiveness of nanosilver collagen cream for healing deep dermal burns in Sprague Dawley rats: an overview of neutrophil counts and angiogenesis. *Bali Medical Journal* 10(2): 648-652. DOI: 10.15562/bmj.v10i2.2313

INTRODUCTION

Injuries remain the third cause of death in the world.¹ One of the causes of injury is burns-the WHO records over 265,000 cases of death by burns worldwide each year. Burns are a primary cause of morbidity and mortality in developing countries.¹ The provision of health care to treat burns varied. It is based on the depth, breadth, and classification of burns.^{2,3} The degree of burns is divided into; 1st degree (epidermal burns), 2nd degree (superficial dermal, mid dermal and deep dermal) and 3rd degree (full-thickness injuries). The 2nd degree of burn case remains the most frequent case in society.²⁻⁴

The wound healing process occurs slowly. There are three phases in healing

burns. The first phase is the inflammatory phase, the second phase is the proliferation phase, and the third phase is the remodeling phase.⁵ In the inflammatory phase, neutrophils become one of the important cells. Neutrophils migrate to the wound area to phagocyte the foreign substance and the existing microbes so that the inflammatory phase occurs and then into the phase of proliferation.⁶ The proliferation phase is the formation of granulation tissue, re-epithelization, and angiogenesis. Angiogenesis plays a vital role in the proliferation phase because the new blood vessels formed will provide the necessary supply of oxygen and nutrients as a metabolic material to form granulation tissues.⁷

The treatment, management of deep

dermal burns is by applying topical medications. The commonly used topical medication is silver sulfadiazine cream. The use of silver sulfadiazine cream in a long time can provide side effects like kidney toxicity, leukopenia, antibiotic resistance, allergic reactions, and delayed wound healing, so topical cream is not advised to use for a long-time.⁸

Another topical drug is nanosilver which has been widely used in the medical field as a coating of surgical equipment and wound dressing. Nanosilver can control bacterial activity on surfaces that are in contact with the silver nanoparticles.⁹ Collagen is a protein that composes about 30% of the total protein in the human body and plays an important role in skin regeneration in wound repair.⁹

Another study also proved that collagen nanosilver contains the potential to improve wound healing through antimicrobial activity and regulate Mitogen Inducible Gen (MIG) fibroblasts and macrophage activations.¹⁰ This research aimed at assessing the effectiveness of the collagen nanosilver cream in specific dosages, especially against the neutrophils and angiogenesis counts in the healing phase of deep dermal burns in Sprague Dawley mice, to prove that the collagen nanosilver Developed by the Laboratory of MIPA Universitas Diponegoro Semarang can remain topical drug alternative to deep dermal burns that are effective and contain minimal side effects.

14 METHODS

This is an experimental research design using a randomized post-test with a control group from October-December 2019. The study used the Sprague Dawley mice to be divided equally into four randomly generated groups. Each group contained 5 mice and got heated for 20 seconds with 150°C Notch heater to induce a deep dermal burn wound. The first group is a negative control group (C) treated with 0.9% NaCl gauze, the second group is a positive control group, which will be treated with silver sulfadiazine cream (SSD). Groups 3 and 4 will be treated with nanosilver collagen ointment at a dose of 1% (NS1) and 2% (NS2). Histopathological examination, counting the number of neutrophils and angiogenesis, will be carried out in each group on the 3rd (D3) and 6th (D6) day after treatment.

According to WHO, the large samples for each group are at least five animals, with a spare sample of 10% (one mouse). In this research, the samples utilized were Sprague Dawley mice with male gender, 12 weeks, and a weight of 250 gram. About 15 mice were divided into three groups, as many as five mice.

The inclusion criteria are Sprague Dawley mice, ages 12 – 14 weeks, weight $\pm 200 - 250$ gram after 1 week of acclimatization in the individual enclosure, and no apparent abnormalities; meanwhile, the exclusion criteria are no maximum thickness of burns on induction. The samples appear sore or die

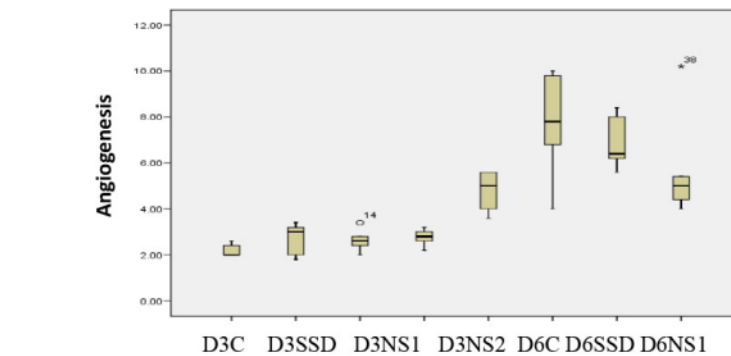


Figure 1. Characteristic of Angiogenesis.

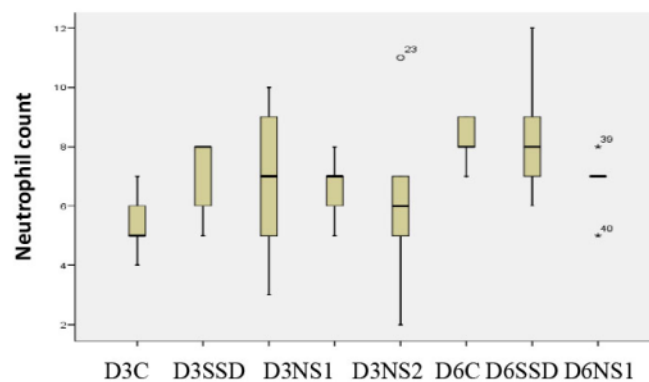


Figure 2. Characteristic of Neutrophil.

during induction or treatment.

The independent variable in this research is nanosilver collagen cream, while the dependent variable in this research is neutrophils count and overview of histopathology angiogenesis. The wound healing process is assessed macroscopically by looking at the wound boundary process with surrounding tissues and histologically with the HE and the degrading van Gieson by measuring the number of neutrophils and angiogenesis on the wound surface. When collected data is done, it will be cleaned, coded, and tabulated.

The morphometric method was used as measurement using software ImageJ in millimeter (mm) units. The data obtained are a comparison of wounds before and after the treatment on the 3rd day and 6th day, which are presented in three graphs of the form with the statistical test, such as Wilcoxon signed-rank test depending

on the normality of data. A network processing method is done by routine paraffin embedding.

The One-Way ANOVA hypothesis test is used if the data distribution is normal. Data analysis will be continued with Post-Hoc Test to identify the differences of every group. A nonparametric test of Kruskal-Wallis will be performed when the data is not as normally distributed. The test is then continued with Mann Whitney Test to test the Mean difference between one group or another. Data analysis is done with computer programs. The limit of the degree of infertility is when $p \leq 0.05$ with a confidence interval of 95%. Data were analyzed using SPSS version 20 for Windows.

RESULTS

The preparation examination is carried out by the veterinarian of the Histologist against the control group and

Table 1. The comparison of neutrophil counts and angiogenesis between treatment group

Variable	Group	Mean \pm SD	P
Neutrophil	D3C	5.40 \pm 1.14	0.159
	D3SSD	7.00 \pm 1.41	
	D3NS1	6.80 \pm 2.86	
	D3NS2	6.60 \pm 1.14	
	D6C	6.20 \pm 3.27	
	D6SSD	8.20 \pm 0.84	
	D6NS1	8.40 \pm 2.30	
Angiogenesis	D6NS2	6.80 \pm 1.10	0.315
	D3C	2.20 \pm 0.28	
	D3SSD	2.68 \pm 0.73	
	D3NS1	2.64 \pm 0.52	
	D3NS2	2.76 \pm 0.38	
	D6C	4.76 \pm 0.92	
	D6SSD	7.68 \pm 2.46	
	D6NS1	6.92 \pm 1.21	0.001*
	D6NS2	5.80 \pm 2.52	

Kruskal-Wallis Test; *Statistically significant if p-value less than 0.05; D=Day; C=Control; SSD=Silver Sulfadiazine; NS=Nanosilver; D3/6C=Day 3/6 Control; D3/6SSD=Day 3/6 Silver Sulfadiazine; D3/6NS1=Day 3/6 Nanosilver Group 1; D3/6NS2=Day 3/6 Nanosilver Group 2.

Table 2. Analysis of the difference of 3rd Day angiogenesis with 6th Day angiogenesis between two treatment groups.

Variable	O2	O3	O4	O5	O6	O7	O8
O1	0.389	0.129	0.034*	0.008*	0.008*	0.008*	0.008*
O2	–	0.916	0.916	0.009*	0.009*	0.009*	0.009*
O3		–	0.599	0.009*	0.009*	0.009*	0.009*
O4			–	0.009*	0.009*	0.009*	0.009*
O5				–	0.059	0.015*	0.752
O6					–	0.465	0.402
O7						–	0.117

Post-Hoc Mann-Whitney Test; *Statistically significant if p-value less than 0.05

treatment. Neutrophils are measured using HE staining from five viewpoints implementing binocular microscopy of 400 times magnification. Data shows an average of angiogenesis branches on burn cases (Figure 1). The highest 3rd-day angiogenesis was obtained in group IV, followed by group II, III, and the lowest group I. Data shows a fork of angiogenesis in burns. In addition, the highest-6th day angiogenesis was obtained in group II, followed by group III, IV, and the lowest in group I (Figure 1).

The data shows the average number of neutrophils in burn cases (Figure 2). The highest neutrophil count on the 3rd day was obtained in group II, then group III, IV and the lowest group I. The highest neutrophil count on the 6th day was obtained in group

III, then group II, IV and the lowest group I (Figure 2).

The Kruskal-Wallis test found a significant difference in evaluating angiogenesis on the 3rd and 6th day of burns ($p=0.001$) between the control and the treatment group (Table 1). Table 1 shows the highest angiogenesis figures in Group II (O6), group III (O7), group IV (O8) and the lowest in group I (O5), i.e., negative control.

However, the Kruskal Wallis test obtained no significant difference ($p=0.159$) in the number of neutrophil counts in all groups on the 3rd day. The One-Way ANOVA test also found no significant difference ($p=0.315$) in the number of neutrophil counts in all groups on the 6th day (Table 1).

The Post-Hoc Mann Whitney Test gained the result that there was a significant difference in the angiogenesis between the 3rd and 6th-day groups, i.e., the group I and IV ($p=0.034$), group I on Day 3 and group I, II, III, and IV on day 6 ($p=0.008$), and the group I to III on Day 6 ($p=0.015$) (Table 2). The Post Hoc Mann-Whitney test was not performed on neutrophils due to the test results of Kruskal-Wallis insignificant neutrophil count, which means there is no influence on administering nanosilver collagen creams against wound healing.

DISCUSSION

Hypotheses on this study were not accepted because the administration of nanosilver collagen cream was not more effective compared to silver sulfadiazine against the healing of deep dermal burns reviewed from neutrophils and angiogenesis counts in Sprague Dawley mice. Nanosilver contains the potential to be used as a wound therapy, including Burns, due to its potent anti-bacterial properties that can reduce recovery time and relieve inflammation.¹¹ Nanosilver can affect and suppress inflammation in the wound and facilitate the initial phases of wound healing. This effect relates to the ability of nanosilver in reducing the local matrix of metalloproteinase in wounds, reducing the impact of pro-inflammatory cytokines, as well as fixing cellular apoptosis.¹²

The research is in line with several previous studies. The collagen sponge of marine fish can regulate the growth of fibroblasts and keratinocytes, proliferation and potential wound healing in mice models. Previous research stated that the collagen dressing of neurotensin significantly reduces inflammation and increases fibroblast migration. In addition, the collagen nanofibers of tilapia can significantly increase the proliferation of keratinocytes, stimulating the epidermis differentiation and facilitating skin regeneration in the skin of the rat who is experiencing burns.^{13,14} These studies have explained that collagen is an excellent biomaterial for use in wound healing.¹³⁻¹⁵

Some studies conducted in correlation with the use of Nanosilver in Burns showed that nanosilver could provide better results when compared to standard therapies such

as silver sulfadiazine cream.¹¹ Previous research showed that nanosilver particles heal 2nd degree deep dermal burns better than the silver sulfadiazine cream, where on 2 deep dermal degree burns with an area of 20-40% healing in the group of nanosilver achieved 10 days earlier compared to the silver Sulfadiazine cream group.¹⁶ In addition, in deep Dermal 2 degree burns with an area of more than 40-60%, healing on the Nanosilver group was reached 13 days earlier compared to the cream group Silver Sulfadiazine. After 4 weeks of therapy, patients can experience perfect healing in the Nanosilver cream group, while there are even no patients experiencing perfect healing in the Silver Sulfadiazine cream Group.¹⁶ Prior research equally found that patients with superficial 2-degree burns who received silver nanoparticle therapy had better healing time than similar burns that received silver sulfadiazine therapy and the control group who Vaseline gauze therapies, while patients with 2-degree burns who received silver nanoparticle therapy suffer a shorter healing time compared to similar burns that barely get vaseline gauze therapy in the control group.¹⁷

The administration of the 1% nanosilver collagen cream against deep dermal burns in Sprague Dawley mice cannot improve angiogenesis better than the administration of silver sulfadiazine cream on the 3rd and 6th day of treatment. It cannot decrease the number of neutrophils on the day of the 6th treatment. Similarly, the administration of nanosilver collagen cream of 2% against deep dermal burns in Sprague Dawley mice cannot improve angiogenesis better than the introduction of silver sulfadiazine cream on the day of the 6th treatment. This is because silver sulfadiazine has been shown to produce inhibitory activity on various microbial species. Silver sulfadiazine does not obstruct the formation of epithelization, although it inhibits the contraction of fibroblasts. Silver sulfadiazine is painless when applied to wounds so that it induces a satisfactory response from the community. Silver sulfadiazine is widely used and has been regarded as a topical "gold standard" treatment for handling burns.¹⁶⁻¹⁸

There is no evidence about the proper dosage for administering nanosilver

collagen creams on deep dermal burns and the length of application that affects its effectiveness. The variation of results emerging from each individual mice experiment was used because the hygienical differences of each mouse were challenging to control, and it can affect the research results. This can be one of the limitations of this study, which can be suggested for subsequent research.

CONCLUSION

The administration of nanosilver collagen cream cannot decrease the number of neutrophils significantly compared to the silver sulfadiazine cream against the healing of deep dermal burns in the Sprague Dawley mice. However, nanosilver collagen cream 2% administration can significantly improve angiogenesis for the healing of deep dermal burns in the Sprague of Dawley mice on the 3rd day of treatment compared to the silver sulfadiazine cream. The administration of nanosilver collagen creams of 1% and 2% also decreased the number of neutrophils and increases angiogenesis compared to the silver sulfadiazine cream against the healing of deep dermal burns in the Sprague Dawley mice.

ACKNOWLEDGMENT

We would like to acknowledge the Medical Faculty of Universitas Diponegoro for supporting this study and the nanotechnology team of Universitas Diponegoro, led by DR. Agus Subagyo, to provide the nanosilver collagen cream for this study.

CONFLICT OF INTEREST

There is no competing interest regarding the manuscript.

ETHICS CONSIDERATION

Ethics approval has been obtained from the Ethics Committee, Medical Faculty, Universitas Diponegoro, dr. Kariadi General Hospital, Semarang, Indonesia, prior to the study being conducted.

FUNDING

None.

AUTHORS CONTRIBUTION

Krisna Muhammad, Awal prasetyo and Yan Wisnu Prajoko conceived of the presented idea. They developed the theory and performed the experiment and computations; they also verified the analytical methods. Najatullah and Neni Susilaningsih contribute as an expert.

REFERENCES

1. Mason SA, Nathens AB, Byrne JP, Gonzalez A, Fowler R, Karanicolas PJ, et al. Trends in the epidemiology of major burn injury among hospitalized patients: A population-based analysis. *J Trauma Acute Care Surg*. 2017;83(5):867-874.
2. Garcia-Espinoza J, Aguilar-Aragon V, Ortiz-Villalobos E, Garcia-Manzano R, Antonio B, Aron J, et al. Burns: Definition, Classification, Pathophysiology and Initial Approach. *International Journal of General Medicine*. 2017;5(5):1-5.
3. Papini R. Management of burn injuries of various depths. *BMJ*. 2004;329(7458):158-160.
4. Nielson CB, Duethman NC, Howard JM, Moncure M, Wood JG. Burns: Pathophysiology of Systemic Complications and Current Management. *J Burn Care Res*. 2017;38(1):e469-e481.
5. Evers LH, Bhavsar D, Mailänder P. The biology of burn injury. *Exp Dermatol*. 2010;19(9):777-783.
6. Qing C. The molecular biology in wound healing & non-healing wound. *Chin J Traumatol*. 2017;20(4):189-193.
7. Velnar T, Bailey T, Smrkolj V. The wound healing process: an overview of the cellular and molecular mechanisms. *J Int Med Res*. 2009;37(5):1528-1542.
8. Mousavi SA, Mousavi SJ, Zamani A, Nourani SZ, Abbasi A, Nasiri E, et al. Comparison of Burn Treatment with Nano Silver-Aloe Vera Combination and Silver Sulfadiazine in Animal Models. 2019;24(3):e79365.
9. Cardoso VS, Quelemes PV, Amorin A, Primo FL, Gobo GG, Tedesco AC, et al. Collagen-based silver nanoparticles for biological applications: synthesis and characterization. *J Nanobiotechnology*. 2014;12:36.
10. Paladini F, Pollini M. Antimicrobial Silver Nanoparticles for Wound Healing Application: Progress and Future Trends. *Materials (Basel)*. 2019;12(16):2540.
11. Abadi AD, Vaheb M, Rakhshani MH, Tofighian T. Comparison of the Effect of Nanosilver Spray and 1% Silver

- Sulfadiazine Cream on the Healing of Second-Degree Burn Wound. *Transl Biomed*. 2018;9(1):1-6.
12. Atiyeh BS, Costagliola M, Hayek SN, Dibo SA. Effect of silver on burn wound infection control and healing: review of the literature. *Burns*. 2007;33(2):139-148.
 13. Liu Z, Zhou A, Zhang X, Zhao C, Li H, Gao L. The efficacy of nanosilver and silver sulfadiazine for degree II burn wound: a meta-analysis. *Biomedical Research*. 2017;28(9):3880-3885.
 14. Chen J, Gao K, Liu S, Wang S, Elango J, Bao B, et al. Fish Collagen Surgical Compress Repairing Characteristics on Wound Healing Process In Vivo. *Mar Drugs*. 2019;17(1):33.
 15. Moura LI, Dias AM, Suesca E, Casadiegos S, Leal EC, Fontanilla MR, et al. Neurotensin-loaded collagen dressings reduce inflammation and improve wound healing in diabetic mice. *Biochim Biophys Acta*. 2014;1842(1):32-43.
 16. Adhya A, Bain J, Ray O, Hazra A, Adhikari S, Dutta G, et al. Healing of burn wounds by topical treatment: A randomized controlled comparison between silver sulfadiazine and nano-crystalline silver. *J Basic Clin Pharm*. 2014 Dec;6(1):29-34.
 17. Chen J, Han CM, Lin XW, Tang ZJ, Su SJ. Effect of silver nanoparticle dressing on second degree burn wound. *Zhonghua Wai Ke Za Zhi*. 2006;44(1):50-52.
 18. Bramardipa AAB, Sukrama IDM, Budayanti NNS. Bacterial pattern and its susceptibility toward antibiotic on burn infection in Burn Unit Sanglah General Hospital. *Bali Medical Journal*. 2019;8(1):328-333.



This work is licensed under a Creative Commons Attribution

Effectiveness of nanosilver collagen cream for healing deep dermal burns in Sprague Dawley rats: an overview of neutrophil counts and angiogenesis

ORIGINALITY REPORT

13%

SIMILARITY INDEX

8%

INTERNET SOURCES

6%

PUBLICATIONS

4%

STUDENT PAPERS

PRIMARY SOURCES

- | | | |
|---|---|----|
| 1 | Submitted to Udayana University
Student Paper | 2% |
| 2 | indriezone.blogspot.com
Internet Source | 1% |
| 3 | Edmar Maciel Lima Júnior, Manoel Odorico de Moraes Filho, Bruno Almeida Costa, Francisco Vagnaldo Fachine et al. "Nile Tilapia Fish Skin-Based Wound Dressing Improves Pain and Treatment-Related Costs of Superficial Partial-Thickness Burns: A Phase III Randomized Controlled Trial", Plastic & Reconstructive Surgery, 2021
Publication | 1% |
| 4 | www.mdpi.com
Internet Source | 1% |
| 5 | Watzke, R.. "Probability of interface imperfections within SEM cross-sections of adhesively luted GFP", Dental Materials, 200910 | 1% |

6

Yuki Enomoto, Masao Iwagami, Asuka Tsuchiya, Kojiro Morita et al.

"Dexmedetomidine use and Mortality in Mechanically-Ventilated Patients with Severe Burns: A Cohort Study Using a National Inpatient Database in Japan", Research Square, 2020

Publication

1 %

7

Submitted to iGroup

Student Paper

1 %

8

Sasan Yousefi, Mehdi Zohoor. "Effect of cutting parameters on the dimensional accuracy and surface finish in the hard turning of MDN250 steel with cubic boron nitride tool, for developing a knowledge base expert system", International Journal of Mechanical and Materials Engineering, 2019

Publication

1 %

9

ejmcm.com

Internet Source

1 %

10

mail.ijsurgery.com

Internet Source

1 %

11

"Handbook of Burns Volume 1", Springer Science and Business Media LLC, 2020

Publication

1 %

12

Internet Source

<1 %

13

Submitted to Mansoura University

Student Paper

<1 %

14

e-journal.unair.ac.id

Internet Source

<1 %

15

www.e-ceo.org

Internet Source

<1 %

16

www.lib.kobe-u.ac.jp

Internet Source

<1 %

17

www.scirp.org

Internet Source

<1 %

18

inajog.com

Internet Source

<1 %

19

www.moh.govt.nz

Internet Source

<1 %

20

"Abstracts from 38th Congress of the Société Internationale d'Urologie Seoul Dragon City, October 4-7, 2018", World Journal of Urology, 2018

Publication

<1 %

21

academic.oup.com

Internet Source

<1 %

22

repository.usu.ac.id

Internet Source

<1 %

23	Pairat Thorncharoensri, Willy Susilo, Yi Mu. "Multi-Level Controlled Signature", 'Springer Science and Business Media LLC', 2012	<1 %
Internet Source		

24	www.ncbi.nlm.nih.gov	<1 %
Internet Source		

25	onlinelibrary.wiley.com	<1 %
Internet Source		

Exclude quotes On

Exclude matches Off

Exclude bibliography On

Effectiveness of nanosilver collagen cream for healing deep dermal burns in Sprague Dawley rats: an overview of neutrophil counts and angiogenesis

GRADEMARK REPORT

FINAL GRADE

/0

GENERAL COMMENTS

Instructor

PAGE 1

PAGE 2

PAGE 3

PAGE 4

PAGE 5