

Hemispherotomy for drug-resistant epilepsy in an Indonesian population

by Yuriz Bakhtiar

Submission date: 17-Feb-2021 03:09PM (UTC+0700)

Submission ID: 1511394477

File name: tomy_for_drug-resistant_epilepsy_in_an_Indonesian_population.pdf (638.48K)

Word count: 3248


Character count: 18010



Contents lists available at ScienceDirect

Epilepsy & Behavior Reports

journal homepage: www.elsevier.com/locate/ebcr



Hemispherotomy for drug-resistant epilepsy in an Indonesian population

Muhamad Thohar Arifin^{a,*}, Zainal Muttaqin^a, Ryosuke Hanaya^b, Yuriz Bakhtiar^a, Aris Catur Bintoro^c, Koji Iida^d, Kaoru Kurisu^d, Kazunori Arita^b, Erie B.P.S. Andar^a, Happy Kurnia B^a, Dody Priambada^a, Ajid Risdianto^a, Gunadi Kusnarto^a, Jacob Bunyamin^a

^a Department of Neurosurgery, Faculty of Medicine, Diponegoro University, Indonesia

^b Department of Neurosurgery, Graduate School of Medical and Dental Sciences, Kagoshima University, Japan

^c Department of Neurology, Faculty of Medicine, Diponegoro University, Indonesia

^d Department of Neurosurgery, Graduate School of Biomedical and Health Sciences, Hiroshima University, Japan

ARTICLE INFO

Article history:

Received 5 August 2019

Received in revised form 3 September 2019

Accepted 20 September 2019

Available online 5 November 2019

Keywords:

Epilepsy

Drug-resistant

Hemispherotomy

ABSTRACT

Hemispherotomy is a surgical treatment indicated in patients with drug-resistant epilepsy due to unilateral hemispheric pathology. Hemispherotomy is less invasive compared with hemispherectomy. We reviewed our experience performing 24 hemispherotomy and report the results of 16 patients with prolonged follow-up of this relatively uncommon procedure in two centers in Indonesia. This is a retrospective observational study conducted from 1999 to July 2019 in two epilepsy neurosurgical centers in Semarang, Indonesia. Surgical techniques included vertical parasagittal hemispherotomy (VPH), peri-insular hemispherotomy (PIH), and modified PIH called the Shimizu approach (SA). The postoperative assessment was carried out using the Engel classification system of seizure outcome. Seizure freedom (Engel class I) outcome was achieved in 10 patients (62.5%), class II in 3 patients (18.7%), class III in 2 patients (12.5%), and class IV in 1 patient (6.3%) with follow-up duration spanning from 24 to 160 months. To the best of our knowledge, this series is the most extensive documentation of hemispherotomy in an Indonesian population.

© 2019 The Authors. Published by Elsevier Inc. This is an open access article under the CC BY-NC-ND license (<http://creativecommons.org/licenses/by-nc-nd/4.0/>).

1. Introduction

Hemispherotomy is a potential surgical treatment indicated for patients with drug-resistant epilepsy due to unilateral hemispheric pathology [1,2]. The underlying etiology for unilateral hemispheric pathology may include conditions such as Rasmussen syndrome, Sturge-Weber syndrome, porencephaly, perinatal stroke and disturbances in neuronal migration (e.g., hemimegalencephaly, cortical dysplasia, and hemiconvulsion-hemiplegia-epilepsy syndrome) [3,4].

As it does not involve cerebral artery ligation and hemisphere removal, hemispherotomy has relatively lower complications compared with more invasive hemispherectomy which may result in higher rates of hemorrhage, hydrocephalus, subdural fluid collections, and cerebral hemosiderosis [5,6]. In functional hemispherotomy, neural

pathways between hemispheres are disconnected without compromising the vasculature in either hemisphere. Since its first description, there have been two major techniques for hemispherotomy: the vertical parasagittal hemispherotomy (VPH), initially described by Delalande [7,8] and the peri-insular hemispherotomy (PIH) detailed by Villemure [9,10]. Other authors have described modifications of either approach, including PIH modification by Shimizu and Maehara [11] who also reported satisfactory results [12].

We report our experience performing hemispherotomy in selected cases and present the result of this relatively uncommon procedure in our center. To the best of our knowledge, this is the most extensive report of hemispherotomy for patients with drug-resistant epilepsy in Indonesia.

2. Methods

This study is a retrospective observational study based on medical records reviewed from two epilepsy centers (Department of Neurosurgery Kariadi and Telogorejo Hospital) in Semarang, Indonesia. We identified patients with drug-resistant focal epilepsy who underwent hemispherotomy from 1999 to July 2019. The study was approved by the institution review boards.

* Corresponding author.

E-mail addresses: thohar@fkundip.ac.id (M.T. Arifin),

hanaya@m2.kufm.kagoshima-u.ac.jp (R. Hanaya), iidak@hiroshima-u.ac.jp (K. Iida),

kuka422@hiroshima-u.ac.jp (K. Kurisu), karita@m2.kufm.kagoshima-u.ac.jp (K. Arita).

2.1. Surgical approach

Pre-surgical evaluation included review of history and physical examination findings, seizure semiology, scalp-EEG recordings, and brain magnetic resonance imaging (MRI). Each patient completed the pre-surgical evaluation, and then a decision to proceed with hemispherotomy was made by consensus among epileptologists, neurosurgeons, and a neuropsychologist. The consideration to perform either VPH or PIH approach (including PIH modification called the Shimizu approach [SA]) was decided based on the underlying pathology and clinical judgment. All surgeries were performed by an epilepsy neurosurgeon (Z.M.).

Our PIH approach was composed of three main steps: the supra-insular window, infra-insular window, and insular resection. Callosotomy is performed from the supra-insular window via the frontal and parietal cortex (cortico-thalamic tract) which is then extended posteriorly to the hippocampal tail and anteriorly to the fronto-basal portion anterior to the basal ganglia. Mesial temporal resection is done via the infra-insular window. Insular resection is performed by subpial aspiration or undermined by incising at the level of the claustrum [10].

In the SA approach, the frontal operculum was resected en bloc including the upper half of the insula. The callosotomy is performed through the lateral ventricle. The resection cavity extends to the inferior ventricle, and the medial temporal structures are resected. In the final step, the horizontal fibers emerging from the frontal lobe are sectioned along the posterior edge of the minor wing of the sphenoid bone.

Our indications for VPH included the presence of ventriculomegaly and the distance between the vertex and temporal horn. One author favored VPH if the distance was less than 10 cm or in small children as the incision was smaller compared with PIH [13].

2.2. Postoperative assessment

The primary outcome of this study was the postsurgical seizure outcome at 12 months compared to baseline seizure frequency. Seizure outcome was assessed based on the Engel's classification system [14] as class I (free of disabling seizures), class II (rare disabling seizures), class III (worthwhile improvement), and class IV (no worthwhile improvement). The outcome was documented on the patient's last visit or through phone call interview.

3. Results

3.1. Demography of patients

A total of twenty-four hemispherotomies were performed from 723 cases operated for drug-resistant epilepsy (see Table 1). Patients' age at surgery ranged from 2 to 28 years old (mean 12.82 ± 6.3 years) with 11 males and 13 females. The onset of seizures started from 0 to 7 years old (mean 2.08 ± 2.1 years). The seizure frequency ranged from 1 to 2 seizures per month to more than 20 seizures daily. Twelve patients had right-sided weakness, 11 had left-sided weakness, and 1 had bilateral weakness (Fig. 1).

3.2. Surgical procedure and underlying pathology

The underlying pathology was congenital porencephaly in 12 cases, hemispheric hemiatrophy in 4, Rasmussen syndrome in 2, hemimegalencephaly in 1, middle cerebral artery (MCA) infarction in 1, polymicrogyria in 1, hemispheric encephalomalacia in 1, Sturge-Weber syndrome in 1, and mesial temporal sclerosis (MTS) with bilateral encephalomalacia in 1 patient. Only one patient was operated with VPH approach while the rest (23 cases)

underwent PIH, including 4 cases treated with SA. Thirteen patients were operated from the left side, including one patient with bilateral weakness.

3.3. Outcomes

Seizure freedom is reported for 16/24 patients. Engel class I outcome was achieved in 10 patients (62.5%), class II in 3 patients (18.7%), class III in 2 patients (12.5%), and class IV in 1 patient (6.3%) with follow-up duration spanning from 24 to 160 months. Among the remaining eight operated patients six patients had less than 12 months of follow-up and two had inadequate records to obtain follow-up information. We noted transient worsening of pre-existing hemiparesis in five patients, who subsequently underwent physiotherapy and improved. No major complication or postoperative mortality was encountered.

4. Discussion

We report the largest surgical series involving hemispherotomy performed to treat drug-resistant epilepsy in Indonesia to date with follow-up duration reaching more than five years. Since hemispherotomy is a relatively rare procedure, we only identified 24 cases from more than 700 patients operated in our centers. This figure is similar to other single-center reports [13,15].

Hemispherotomy is mainly indicated for drug-resistant infantile hemispheric epilepsy. Most of our patients had a unilateral weakness with varied severity (87.5%). Other symptoms such as hemianopsia was not recorded. Seizure-free outcome from hemispherotomy is good with reports ranging from 68 to 94% [13]. In our study, 10 (62.5%) patients obtained an Engel class I outcome and 13 (81.3%) patients experienced improvement (Engel classes I and II). The seizure-free outcome in PIH was reported to be 90% in a 9-year follow-up period [10], while the seizure-free outcome in VPH was reported to be 74% [8]. However, both authors stated that the underlying etiology may influence the success of the surgery. A favorable outcome was reported in 75% of 12 patients operated with SA [12]. In this series, of the 10 patients achieving Engel Class I outcome, 9 were operated using the PIH approach while 1 underwent the SA. We also documented the VPH approach in a 6-year-old girl with Sturge-Weber syndrome.

Acquired lesions such as porencephaly are known to have a better prognosis, along with Rasmussen syndrome' and Sturge-Weber syndrome when compared to neuronal migration disorders creating cortical malformation probably due to potential involvement of the contralateral hemisphere [8]. Patients with cortical malformations tend to be operated at a young age. Poor prognosis predictors include a contralateral hemispheric abnormality and patients with an abnormal hemisphere involving extensive insular and subcortical heterotopic gray matter on imaging studies [16–17]. In this series, among patients with seizure freedom, 6 (60%) was diagnosed with porencephaly, 2 with hemispheric hemiatrophy, 1 with Rasmussen syndrome' and 1 with large MCA infarction.

Seizure frequency reduction may improve the quality of life of patients and cognitive capability. Delaying surgical procedures is associated with worsening abilities as a consequence of ongoing seizures especially relative to verbal communication [18]. The average delay of surgery in our case series was 10.43 ± 5.9 years (range 2–23 years), with an average age of seizure onset ranging from 0 to 7 years old (mean 2.08 ± 2.1 years).

Compared with anatomical and functional hemispherectomy, modified PIH had a lower risk of surgical complications and rate of reoperation, although the seizure outcome did not significantly

Table 1
Seizure outcomes after hemispherotomy.

| No. | Sex | Age at onset | Age at surgery | Seizure frequency (daily) | Clinical semiology | Neuroimaging (MRI) | EEG | Surgical approach | Engel outcome score | FU length (MO) | Neuropsychological assessment | Complications |
|-----|-----|--------------|----------------|---------------------------|---|---|---|-------------------|--|----------------|---|-----------------------|
| 1 | M | 5 | 28 | 1–2 | R infantile hemiplegia, focal to bilateral tonic-clonic seizures | L hemispheric hemiatrophy | L hemispheric continuous slow, epileptiform background | L, PIH | I | 160 | N/A | Worsening hemiplegia |
| 2 | M | 6 | 12 | N/A | R infantile hemiplegia | L hemispheric neonatal MCA infarction | L frontotemporal (ictal) | L, PIH | I | 145 | FIQ 50 | |
| 3 | F | 1 | 6 | 10–15 | R infantile hemiplegia | L congenital porencephalic cyst | Bilateral slow waves | L, SA | II | 138 | FIQ 82 | Worsening hemiplegia |
| 4 | F | 5 | 21 | 6–7 | Focal to bilateral tonic-clonic seizures | R severe atrophy | R temporal and frontal independently then generalization | R, SA | III | 124 | N/A | |
| 5 | F | 1 | 11 | 4–5 | R infantile hemiparesis | L hemispheric congenital porencephaly | L hemisphere (ictal) | L, PIH | I | 119 | N/A | |
| 6 | F | 4 | 7 | 1–2 | L infantile hemiparesis | R severe atrophy | L hemisphere | L, PIH | III | 118 | N/A | Worsening paresis |
| 7 | M | 3 | 15 | 1–2 | L infantile hemiparesis | R congenital porencephalic cyst | R frontocentral PLED | R, SA | I | 117 | FIQ 65 | Worsening paresis |
| 8 | F | 1 | 6 | N/A | L infantile hemiparesis | R Sturge-Weber syndrome | R slow activity, no epileptiform | R, VPH | N/A | N/A | FIQ 66 | |
| 9 | M | 1 | 5 | >10 | Bilateral hemiplegia | Bilateral encephalomalacia, enlarged L ventricle, L mesial temporal sclerosis | Bilateral temporal epileptiform, low amplitude | L, PIH | II | 99 | N/A | |
| 10 | F | 1 | 14 | 2–3 | R infantile hemiparesis | L porencephalic cyst | L fronto-centro-temporal PLED, continuous slow | L, PIH | I | 98 | FIQ 64 | |
| 11 | F | 0.25 | 23 | N/A | R infantile hemiparesis | L porencephalic cyst, damaged insula | L hemisphere continuous slow | L, PIH | I | 88 | IQ gr 5 | |
| 12 | M | 4 | 14 | 3–4 | bilateral tonic-clonic seizures | R hemispheric porencephaly | R frontal (ictal) | R, PIH | I | 83 | FIQ 99 | |
| 13 | M | 2 | 22 | 5 | L infantile hemiparesis | R congenital porencephaly | R hemisphere slow waves | R, PIH | IV | 76 | IQ gr 5 | |
| 14 | F | 2 | 13 | 1–2 | L hemiparesis, focal to bilateral tonic-clonic seizures | R large porencephaly, large intracerebral hemorrhage | R continuous slow waves | R, PIH | I | 54 | FIQ 51 | |
| 15 | M | 5 | 18 | 0–1 | R hemiparesis, focal to bilateral tonic-clonic seizures | L hemispheric hemiatrophy | Biparietal spikes | L, PIH | I | 53 | FIQ 75 | Worsening hemiparesis |
| 16 | M | N/A | 24 | N/A | R infantile hemiparesis | L fronto-parieto-temporal porencephaly | | L, PIH | N/A | N/A | Wada test: no memory function at L hemisphere | |
| 17 | F | 7 | 11 | 3–4 weekly | L infantile hemiparesis, focal to bilateral tonic clonic seizures | R Rasmussen's encephalitis | R slow hemisphere | R, PIH | I | 29 | N/A | |
| 18 | F | 3 | 12 | 3–5 | R infantile hemiparesis | L hemispheric porencephaly | (ictal) L hemisphere, interictal epileptic discharges | L, SA | II | 26 | FIQ 59 | |
| 19 | M | 0.3 | 12 | N/A | Hemispheric epilepsy | L congenital porencephaly | L continuous slow waves | L, PIH | N/A (reported seizure freedom after surgery) | 8 | Cerebral palsy | |
| 20 | F | 0 | 2 | >20 | R infantile hemiparesis | L polymicrogyria, cortical dysplasia | L temporo-central with diffuse electrophysiological disturbance | R, PIH | N/A (reported seizure freedom after surgery) | 8 | N/A | |
| 21 | M | N/A | 10 | >20 | L infantile hemiparesis | R hemimegalencephaly | R slow waves | R, PIH | N/A | 5 | N/A | |
| 22 | M | N/A | 14 | N/A | R infantile hemiparesis | L hemispheric large encephalomalacia | N/A | L, PIH | N/A | 5 | N/A | |
| 23 | F | 1 | 9 | N/A | L hemiparesis | R fronto-temporo-parietal porencephaly, encephalomalacia | (ictal) R hemisphere | R, PIH | N/A | 3 | FIQ 46 | |
| 24 | F | 3 | 10 | N/A | L infantile hemiparesis, focal to bilateral tonic-clonic seizures | R Rasmussen's encephalitis | R occipital PLED, R epileptiform frontal, R temporal slow waves | R, PIH | N/A (reported seizure freedom after surgery) | 1 | FIQ 83 | |

M = male; F = female; L = left; R = right; EEG: electroencephalography; N/A = not available; MCA = middle cerebral artery; MTS = mesial temporal sclerosis; MRI = magnetic resonance imaging; PIH = peri-insular hemispherotomy; SA = Shimizu's approach; VPH = ventricular parasagittal hemispherotomy; FIQ = full intelligence quotient; PLED = periodic lateralized epileptic discharges; FU = follow-up.

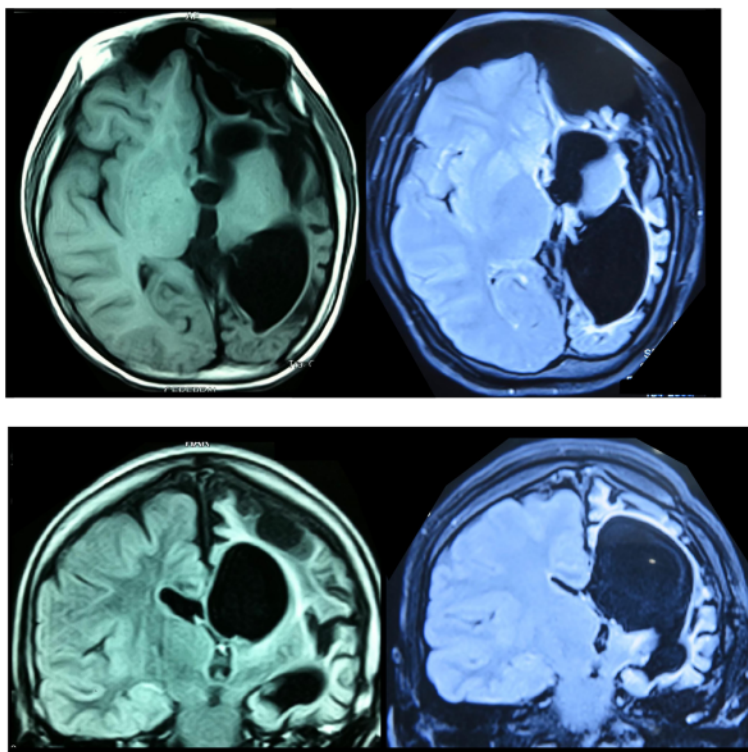


Fig. 1. Preoperative (left) and postoperative (right) axial and coronal MRI slices of a 14-year-old female (Pt. no. 10) with right-sided infantile hemiparesis showed large porencephalic cysts in her left hemisphere. Left-sided hemispherotomy was performed (PIH). Postoperative observation resulted in complete seizure freedom (Engel class I) at 98 months.

differ between techniques [6]. Hydrocephalus is a common sequel after hemispherectomy and has been correlated with anatomical hemispherectomy [19]. Transient postoperative hemiparesis or hemiplegia is also seen in patients who undergo hemispherotomy. However, this phenomenon does not persist [18]. In our series, five patients developed temporary worsening of their baseline hemiparesis, which recovered with therapy.

5. Conclusion

Hemispherotomy is a surgical procedure to treat patients with drug-resistant hemispheric epilepsy and involves hemispheric disconnection. Hemispherotomy has favorable seizure-free outcomes and a lower rate of postoperative complications compared with anatomic hemispherectomy. To our knowledge this is the largest series of patients operated for drug-resistant epilepsy using hemispherotomy in an Indonesian population with a seizure-free outcome in 62.5% of 16 patients with 81.3% of patients improved regarding reduction in pre-operative seizure frequency.

Declaration of competing interest

All authors declare no conflict of interest.

Acknowledgements

The authors would like to acknowledge a research grant from Ministry of Research, Technology and Higher Education Republic

of Indonesia (Kemenristekdikti) for the funding support of the research project.

References

- [1] Kim J, Park Ek, Shim KW, Kim DS. Hemispherotomy and functional hemispherectomy: indications and outcomes. *J Epilepsy Res* 2018;8:1–5.
- [2] Kishima H, Oshino S, Tani N, Maruo Y, Morris S, Khoo HM, et al. Which is the most appropriate disconnection surgery for drug-resistant epilepsy in childhood? *Med Chir* 2013;53:814–20.
- [3] Harvey AS, Cross JH, Shinnar S, Mathem G. Defining the spectrum of international practice in pediatric epilepsy surgery patients. *Epilepsia* 2008;49:149–55.
- [4] Cross JH, Jayakar P, Nordli D, Delalande O, Duchowni M, Wieser HG, et al. Proposed criteria for referral and evaluation for epilepsy surgery: recommendations of the subcommission for pediatric epilepsy surgery. *Epilepsia* 2006;47:952–9.
- [5] Oppenheimer DR, Griffith HB. Persistent intracranial bleeding as a complication of hemispherectomy. *J Neurol Neurosurg Psychiatry* 1966;29:229–40.
- [6] Cook SW, Nguyen ST, Hu B, Yudovin S, Shields WD, Vinters HV, et al. Cerebral hemispherectomy in pediatric patients with epilepsy: comparison of three techniques by pathological substrate in 115 patients. *J Neurosurg* 2004;100(2 Suppl):125–4.
- [7] Delalande O, Pinard JM, Basdevant C, Gauthier M, Plouin P, Dulac O. Hemispherotomy: a new procedure for central disconnection. *Epilepsia* 1992;33:99–100.
- [8] Delalande O, Bulteau C, Dellatolas G, Fohlen M, Jalin C, Buret V, et al. Vertical parasagittal hemispherotomy: surgical procedures and clinical long-term outcomes in a population of 83 children. *Neurosurgery* 2007;60.
- [9] Villemure JG, Mascott CR. Peri-insular hemispherotomy: surgical principles and anatomy. *Neurosurgery* 1995;37:975–81.
- [10] Villemure JG, Daniel RT. Peri-insular hemispherotomy in panti-seizure drugs. *Epilepsia Child Ner Syst* 2006;22:967–81.
- [11] Shimizu H, Maehara T. Modification of peri-insular hemispherotomy and surgical results. *Neurosurgery* 2000;47:367–72.
- [12] Shimizu H. Surgical treatment for pediatric drug-resistant epilepsy—focusing on modified functional hemispherectomy in infants. *No To Hattatsu* 33, 153–158.
- [13] Chandra PS, Padma VM, Shailesh G, Chandreshkar B, Sarkar C, Tripathi M. Hemispherotomy for drug-resistant epilepsy. *Neurol India* 56, 127–132.

- [14] Engel J, Cascino GD, Ness PC, Rasumssen TB. Seizures, Outcome with respect to epileptic. In: Engel J, editor. *Surgical Treatment of the Epilepsies*. NY: Raven Press; 1993.
- [15] Marras CE, Granata T, Franzini A, Freri E, Villani F, Casazza M, et al. Hemispherotomy and functional hemispherectomy: indications and outcome. *Epilepsy Res* 89, 104–112.
- [16] Carreño M, Wyllie E, Bingaman W, Kotagal P, Comair Y, Ruggieri P. Malformations, Seizure outcome after functional hemispherectomy for malformations of cortical development. *Neurology* 2001;57:331–3.
- [17] Cats EA, Kho KH, Van Nieuwenhuizen O, Van Veelen CW, Goselaar PH, Van Rijen PC. Seizure freedom after functional hemispherectomy J, and a possible role for the insular cortex: the Dutch experience. *Neurosurg* 2007;107:275–80.
- [18] Battaglia D, Di Rocco C, Iuvone L, Acquafondata C, Iannelli A, Lettori D, et al. Neurocognitive development hemimegalencephaly, and epilepsy outcome in children with surgically treated. *Neuropediatrics* 1999;30:307–13.
- [19] Lew SM, Matthews AE, Hartman AL, Haranhalli N. Posthemispherectomy hydrocephalus: results of a comprehensive, multiinstitutional review. *Epilepsia* 2012;54:383–9.

Hemispherotomy for drug-resistant epilepsy in an Indonesian population

ORIGINALITY REPORT

19%
SIMILARITY INDEX

12%
INTERNET SOURCES

14%
PUBLICATIONS

6%
STUDENT PAPERS

PRIMARY SOURCES

1 tsukuba.repo.nii.ac.jp 2%
Internet Source

2 www.j3.jstage.jst.go.jp 2%
Internet Source

3 ir.ymlib.yonsei.ac.kr 1%
Internet Source

4 "Textbook of Pediatric Neurosurgery", Springer Science and Business Media LLC, 2020 1%
Publication

5 Pinto, Anna L.R., Subash Lohani, Ann M.R. Bergin, Blaise F.D. Bourgeois, Peter M. Black, Sanjay P. Prabhu, Joseph R. Madsen, Masanori Takeoka, and Annapurna Poduri. "Surgery for Intractable Epilepsy Due to Unilateral Brain Disease: A Retrospective Study Comparing Hemispherectomy Techniques", Pediatric Neurology, 2014. 1%
Publication

| | | |
|----|---|-----|
| 6 | I D Kumalasari, I Santosa, E Sulistiawati. "Coconut Oil Production with Various Roasting Temperatures and Dried Grated Coconut as A By-Product", IOP Conference Series: Earth and Environmental Science, 2020 Publication | 1 % |
| 7 | "December 8, 2003", Epilepsia, 10/2003 Publication | 1 % |
| 8 | www.techuniq.com Internet Source | 1 % |
| 9 | Submitted to University of Newcastle Student Paper | 1 % |
| 10 | docplayer.net Internet Source | 1 % |
| 11 | coek.info Internet Source | 1 % |
| 12 | Roberto Caraballo, Marcelo Bartuluchi, Ricardo Cersósimo, Alejandra Soraru, Hugo Pomata. "Hemispherectomy in pediatric patients with epilepsy: a study of 45 cases with special emphasis on epileptic syndromes", Child's Nervous System, 2011 Publication | 1 % |
| 13 | www.hindawi.com Internet Source | 1 % |

14

Internet Source

1 %

15

Daniel Staemmler. "Publisher's Note", Epilepsy & Behavior Reports, 2019

Publication

1 %

16

Submitted to Medizinischen Universität Wien

Student Paper

<1 %

17

digital.library.unt.edu

Internet Source

<1 %

18

onlinelibrary.wiley.com

Internet Source

<1 %

19

"21st IEC Proceedings. 21 st International Epilepsy Congress Sydney, Australia, September 3-8, 1995", Epilepsia, 3/1995

Publication

<1 %

20

Cristina V. Torres. "The role of magnetoencephalography in children undergoing hemispherectomy : Clinical article", Journal of Neurosurgery Pediatrics, 12/2011

Publication

<1 %

21

www.jci.org

Internet Source

<1 %

22

"FREE COMMUNICATIONS POSTER COMMUNICATIONS", Nephrology, 6/2005

Publication

<1 %

- | | | |
|----|---|------|
| 23 | "Island of Reil (Insula) in the Human Brain", Springer Science and Business Media LLC, 2018 Publication | <1 % |
| 24 | Miguel Angel Lopez-Gonzalez, Jorge Alvaro Gonzalez-Martinez, Lara Jehi, Prakash Kotagal, Ann Warbel, William Bingaman. "Epilepsy Surgery of the Temporal Lobe in Pediatric Population: A Retrospective Analysis", Neurosurgery, 2012 Publication | <1 % |
| 25 | www.scribd.com Internet Source | <1 % |
| 26 | www.thieme-connect.com Internet Source | <1 % |
| 27 | "Textbook of Stereotactic and Functional Neurosurgery", Springer Science and Business Media LLC, 2009 Publication | <1 % |
| 28 | Josef Zentner. "Surgical Treatment of Epilepsies", Springer Science and Business Media LLC, 2020 Publication | <1 % |
| 29 | Ju-seong Kim, Eun-Kyung Park, Kyu-Won Shim, Dong Seok Kim. "Hemispherotomy and Functional Hemispherectomy: Indications and | <1 % |

Outcomes", Journal of Epilepsy Research, 2018

Publication

Exclude quotes On

Exclude matches Off

Exclude bibliography On

Hemispherotomy for drug-resistant epilepsy in an Indonesian population

GRADEMARK REPORT

FINAL GRADE

/0

GENERAL COMMENTS

Instructor

PAGE 1

PAGE 2

PAGE 3

PAGE 4

PAGE 5