

Ten Years Neglected Chronic Subdural Hematoma of Pediatric in Rural Area

by Yuriz Bakhtiar

Submission date: 17-Feb-2021 03:32PM (UTC+0700)

Submission ID: 1511400871

File name: glected_Chronic_Subdural_Hematoma_of_Pediatric_in_Rural_Area.pdf (766.8K)

Word count: 2066

Character count: 11283

CASE REPORT

Ten Years Neglected Chronic Subdural Hematoma of Pediatric in Rural Area

Yuriz Bakhtiar¹, Lathifa Putry Fauzia², Adrian Pratama³

¹ Department of Neurosurgery, Faculty of Medicine Diponegoro University, Jl. Prof. Soedarto SH, Tembalang, 50275 Semarang, Indonesia

² Faculty of Medicine Diponegoro University, Jl. Prof. Soedarto SH, Tembalang, 50275 Semarang, Indonesia,

³ Salatiga Regency Hospital, Jl.Osamaliki No. 19, 50721 Salatiga, Indonesia

ABSTRACT

The most common cause of chronic subdural hematoma in pediatric is head trauma. Many cases are not diagnosed immediately due to subclinical course, insignificant signs and symptoms, or delayed admission to the hospital. Here, we reported a rare case of 10 years neglected traumatic subdural hematoma in 11-year-old child due to history of falling and head injury when she was 1.5 years old. No altered mental state or focal neurological deficit was observed; the child presented with moderate headache, deterioration of concentration, and deformity of the cranium. A plain CT head revealed a predominant hyperdense subdural collection mixed with hypodense collection overlying the left cerebral convexity. Craniotomy and membranectomy were performed, then followed by a satisfactory improvement of the cognitive skill of the patient.

Keywords: Chronic subdural hematoma, Pediatrics, Craniotomy

Corresponding Author:

Yuriz Bakhtiar, PhD

Email: yurizbakhtiar@fk.undip.ac.id

Tel: +6224-76928010

INTRODUCTION

Chronic subdural hematoma (CSDH) rarely happens in children (1). Trauma is an important factor in developing CSDH especially in children (2). The rupture of bridging vein initially starts the mechanism of traumatic CSDH (3). Depends on the location and size of the hematoma, the patient can present with focal clinical syndrome or signs and symptoms of intracranial hypertension (1). Pediatric patients often unaware of the signs and symptoms until they become clinically evident, which can be last for months to years (1,2). Although many reports have recorded traumatic CSDH in pediatric, we could not find any report of neglected CSDH that last for more than five years. Here we report a case of ten years neglected traumatic subdural hematoma in 11-year-old child in rural area due to history of falling and head injury when she was 1.5 years old.

CASE REPORT

An 11-year-old girl was presented with moderate headache for one month. She had history of falling from a bicycle and hitting her left side of the head when she was 1.5 years old. For several years, there was only a sign of left cranial deformity without any other significant symptoms. Therefore, their parents did not admit her to the healthcare facility at that time. Recently, she complained of moderate headache and deterioration of concentration especially when she was studying which made her parents admit her to the hospital. On examination, there was no altered mental state (GCS score 15) or any neurological deficit (motor strength grade 5 on extremities and normal neurological reflex), with only a deformity on the left temporoparietal cranium without any tenderness. All blood tests and coagulation profiles showed normal results. A plain brain computed tomography (CT) scan (Fig. 1) revealed a predominant hyperdense subdural collection mixed with hypodense collection overlying the left cerebral convexity. She was managed by craniotomy and membranectomy to evacuate the subdural collection

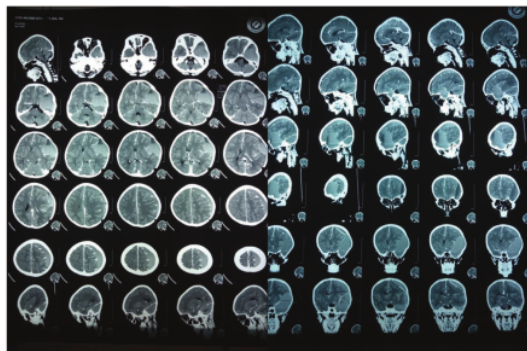


Fig. 1 : Axial, sagittal, and coronal computed tomography brain demonstrating thick left hemispheric subdural collection.

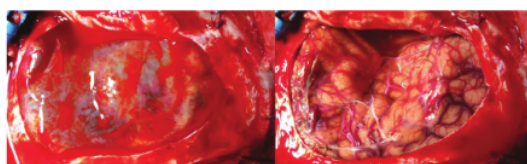


Fig. 2 : Photograph: craniotomy and membranectomy to evacuate subdural hematoma.

(Fig. 2). The pathologic anatomy examination of the tissue membrane indicated an arachnoid cyst with unspecified chronic inflammation. A follow-up assessment after one month (Table 1) showed that the headache symptom had alleviated; the concentration had improved; and a complete resorption of the known hematoma with a slight left cranial deformity had revealed in brain CT scan (Fig. 3).

Table 1 : The Comparison of Clinical Presentation Before and After the Treatment

Before the Treatment	After the Treatment
Moderate headache	No headache
Difficulty in concentrating caused the average mathematic score in school was 75 out of 100 from 2 nd grade until 4 th grade	Concentration had improved caused increasing of mathematic score of 90 in the 5 th grade
Deformity of the left cranium (as shown in figure 1)	Deformity of the left cranium had reduced (as shown in figure 3)

DISCUSSION

Chronic subdural hematoma (CSDH) is an accumulation of blood, fluid (i.e cerebrospinal fluid), and blood degradation products located between the arachnoid mater and the dura mater for more than three weeks which sometimes loculated, divided into chambers, by neomembranes (1–3). The most common cause of CSDH is head trauma (4). It is frequently happened in children under two years old and may lead to lethal outcome (2). However, many cases are not diagnosed

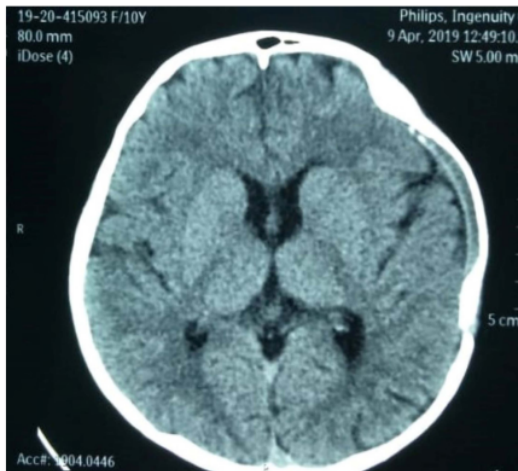


Fig. 3 : Axial computed tomography brain (post craniotomy and membranectomy) showing complete resorption of hematoma with a slight left cranial deformity.

immediately due to subclinical course, insignificant signs and symptoms, or delayed admission to the hospital (2). The clinical presentations of CSDH have wide range from asymptomatic to symptomatic, such as headaches, nausea and vomiting, seizure, mental status change, cognitive impairment, motoric and sensory disturbance, stroke, and the worst case is coma (1,4,5).

Our patient only had deformity of the cranium without any significant symptom for almost ten years after falling from a bicycle and hitting her left side of the head when she was 1.5 years old. The parents might already notice this deformity, but because she did not complain of any symptoms and they lived in rural area, they delayed to do medical check-up. Recently, she complained of moderate headache and deterioration of concentration especially when she was studying which made her parents admit her to the hospital. The difficulty of studying caused her mathematic score was only 75 out of 100 on average since 2nd grade until 4th grade in school. Wright, et al also reported a pediatric CSDH case of 13-year-old boy with a 1-month history of global headache after an injury of falling and hitting his head on a chair (6) and Shrestha, et al summarized that headache was the commonest symptom of CSDH with arachnoid cyst case in children (7).

There are three phases in the clinical progression of CSDH, they are initial phase, latency phase, and clinical phase (5). The initial phase usually starts with the traumatic events causing formation of the hematoma due to rupture of bridging vein that cross subdural space (2,4,5). The bridging vein portion in the subdural space is assumed to be more vulnerable because it's thickness is only about one tenth

compared to bridging vein in the subarachnoid space (2).

The second phase, latency phase, is characterized by the maturation and enlargement of hematoma gradually (5). The key feature of maturation of hematoma is the dural border cells, which can develop into fibro-cellular connective tissue to form neomembrane along the dural and arachnoid side which encapsulate the hematoma (3,5). Damage to the dural border cell will initiate the inflammatory response which then recruits inflammatory cells to the subdural space to proliferate and form neomembrane (5). In this membrane, sinusoidal vessels with poor endothelial junction are developed which become the source of recurrent bleeding in the subdural space accompanied by clotting prevention and hemolysis (3,4). These leaky vessels enable micro-hemorrhage and fluid exudation into the subdural space, and causes the enlargement of CSDH (2,5). Patients may be asymptomatic during this phase for several weeks to years (5), which also happened to our patient for almost ten years.

Continuous enlarging of the hematoma induces progressive decompensation of intracranial capacity which will manifest as symptoms of increased intracranial pressure or mass effect (5). This is the hallmark of clinical phase (5). In our case, the patient had moderate headache and deterioration of concentration. We assumed that headache was caused by increase intracranial pressure. However, the mechanism of deterioration of concentration in pediatric CSDH is not clearly understood because most of the pathophysiologic data regarding CSDH rely on adult studies.

A plain brain CT scan of CSDH usually shows a crescent-shaped heterogeneous mass encased by the neomembrane (2). The density of the mass is slightly above the CSF's density because it is a mixture of blood components (2). It usually happens on the most arched in frontal or occipital convexity, which is more frequently on the left side (4). In our case, CT scan revealed a predominant hyperdense subdural collection mixed with hypodense collection overlying the left parietal to temporal convexity. This heterogeneous collection was indicated as a subdural hematomahygroma, which was a mixture of blood (or blood degradation products) and CSF (or CSF-like fluid) (2).

Other case report of pediatric CSDH showed an isodense subdural collection from a plain CT head which then revealed as an arachnoid cyst (6). The isodense appearance was due to intra- and extra-cystic hemorrhage which occurred simultaneously (6). An arachnoid cyst, which is considered congenital, can rupture spontaneously or due to head injury. The injury can cause the detachment of cyst membrane from the dura and eventually bleeding episode occur (6,7). In our case, the recurrent bleeding in the subdural space

accompanied by clotting prevention and hemolysis caused a heterogeneous subdural collection.

The most preferred management of CSDH is surgery, especially in moderate to large hematoma with neurodeficit (4,5). Three most commonly performed surgical techniques are twist-drill craniostomy (TDC), burr-hole craniostomy (BHC), and craniotomy (4,5). We managed the patient by craniotomy and membranectomy. They were selected due to the extensive and chronicity of the hematoma. The fluid evacuated had xanthochrome color, which was estimated as the mixture of blood and CSF. Pathological anatomy examination of the membrane revealed that it was an arachnoid cyst with unspecified chronic inflammation. This finding was consistent with Shresta et al which also reported a xanthochromic fluid from the resection of subdural hematoma with arachnoid cyst from a 5-year old patient (7).

Previous studies reported favorable prognosis after surgical treatment, with more than 80% of treated patients obtaining a satisfactory outcome at follow-up (5). Prognosis is superior in better preoperative GCS and in younger patients.(4) Since our patient had full GCS score and young age, a follow-up assessment after one month showed that her headache had alleviated; the concentration had improved (her mathematic score became 90 on the 5th grade); and a complete resorption of the known hematoma with a slight left cranial deformity had revealed in brain CT scan.

CONCLUSION

The diagnosis of chronic subdural hematoma in pediatric is highly possible to be neglected due to lack of its significant symptoms and signs. The socio-demographic status also influences the decision to do medical check-up. In fact, early diagnosis and treatment will reveal excellent prognosis. CSDH should be considered when assessing children with cranial deformity even without any symptoms therefore early neuroimaging such as plain brain CT scan should be performed.

ACKNOWLEDGEMENT

The authors claim to have no conflict of interest in publishing this study. In addition, special thanks to those who had involved in managing this patient.

REFERENCES

1. Emamhadi M, Chabok SY, Alijani B, Behzadnia H, Rasouljan J, Andalib S. Chronic Subdural Hematoma in Pediatrics: A Case Report and Literature Review of Rare Cases. *Trauma Mon.* 2017;22(6).
2. Wittschieber D, Karger B, Pfeiffer H, Hahnemann ML. Understanding subdural collections in

- pediatric abusive head trauma. *Am J Neuroradiol.* 2019;40(3):388–95.
3. Edlmann E, Giorgi-Coll S, Whitfield PC, Carpenter KLH, Hutchinson PJ. Pathophysiology of chronic subdural haematoma: Inflammation, angiogenesis and implications for pharmacotherapy. *J Neuroinflammation.* 2017;14(1):1–13.
 4. Yadav Y, Parihar V, Namdev H, Bajaj J. Chronic subdural hematoma. *Asian J Neurosurg.* 2016 Oct 1;11(4):330–42.
 5. Yang W, Huang J. Chronic Subdural Hematoma: Epidemiology and Natural History. *Neurosurg Clin N Am.* 2017 Apr;28(2):205–10.
 6. Wright D, Pereira EC, Magdum S. A pediatric chronic subdural hematoma: More than meets the eye. *J Pediatr Neurosci.* 2016;10(4):376.
 7. Shrestha R, You C. Spontaneous chronic subdural hematoma associated with arachnoid cyst in children and young adults. *Asian J Neurosurg.* 2014;9(3):168–72.

Ten Years Neglected Chronic Subdural Hematoma of Pediatric in Rural Area

ORIGINALITY REPORT

5%

SIMILARITY INDEX

4%

INTERNET SOURCES

2%

PUBLICATIONS

1%

STUDENT PAPERS

PRIMARY SOURCES

1	worldwidescience.org Internet Source	1%
2	medic.upm.edu.my Internet Source	1%
3	psasir.upm.edu.my Internet Source	1%
4	www.repository.cam.ac.uk Internet Source	1%
5	Serge Weis, Michael Sonnberger, Andreas Dunzinger, Eva Voglmayr, Martin Aichholzer, Raimund Kleiser, Peter Strasser. "Chapter 19 Vascular Disorders: Hemorrhage", Springer Science and Business Media LLC, 2019 Publication	<1%
6	talenta.usu.ac.id Internet Source	<1%
7	Ye Yuan, Qiang-ping Wang, Yu-lin Cao, Hongri Zhang, Mohammad Shah Nayaz Burkutally, Kamile Budryte, Nanxiang Xiong. "Burr hole	<1%

drainage and burr hole drainage with irrigation to treat chronic subdural hematoma", Medicine, 2018

Publication

Exclude quotes On

Exclude matches Off

Exclude bibliography On

Ten Years Neglected Chronic Subdural Hematoma of Pediatric in Rural Area

GRADEMARK REPORT

FINAL GRADE

/0

GENERAL COMMENTS

Instructor

PAGE 1

PAGE 2

PAGE 3

PAGE 4
