



***Spondyloarthropathy***

**Hermina Sukmaningtyas**

**Musculoskeletal Divion, Department of Radiology, Faculty of Medicine, Diponegoro University- dr  
Kariadi Hospital Semarang**

**ABSTRACT**

*Seronegative spondyloarthropathies (SpA) have the most peculiar feature which involved the spine and sacroiliac joints inflammatory. SpA consist of ankylosing spondylitis, psoriatic arthritis, reactive arthritis (Reiter's syndrome), enteropathic spondylitis (related to inflammatory bowel diseases) and undifferentiated spondyloarthropathies. SAPHO syndrome may also be considered a SpA, but there is no clear agreement. Imaging, along with clinical and laboratory evaluation, has crucial role to diagnosis and monitoring to provide a precise grading of disease progression, influencing both clinical management and therapy. Conventional radiography, which is often the first-step imaging modality, does not allow an early diagnosis. Computed tomography (CT) demonstrates with a very high spatial resolution the tiny structural alterations of cortical and spongy bone before they become evident on plain film radiographs. Computed tomography and conventional radiography can also identify structural changes, such as subchondral sclerosis, erosions, fat deposits, and ankyloses. Magnetic resonance imaging (MRI) is the only modality that provides demonstration of bone marrow oedema, which reflects vasodilatation and inflammatory hyperaemia, osteoitis, synovitis, enthesitis and capsulitis.*

## Pendahuluan

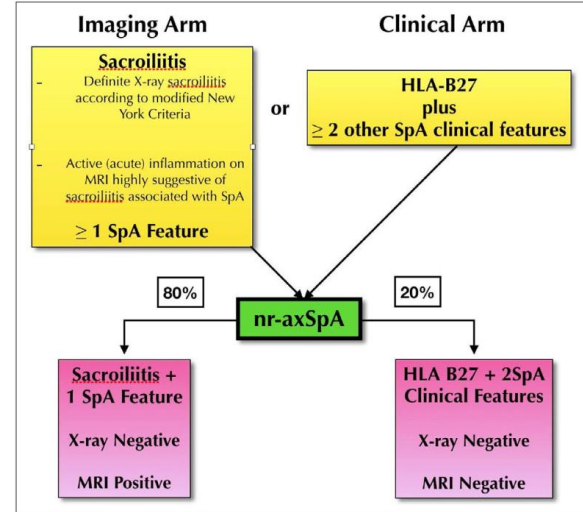
Spondyloarthritis (SpA) merupakan spektrum penyakit inflamasi kronik yang dimediasi oleh sistem imun. Kelompok SpA terdiri dari ragam penyakit rematik seperti Ankylosing Spondylitis (AS), psoriatic arthritis (PsA), reactive arthritis (ReA) dahulu disebut Reiter's syndrome, enteropathic spondylitis (related to inflammatory bowel diseases/ IBD-SpA) dan undifferentiated spondyloarthropathies. SAPHO (synovitis, acne, pustulosis, hyperostosis and osteitis) kemungkinan termasuk SpA meskipun belum ada kesepakatan.

SpA dibedakan menjadi Axial SpA dan Peripheral SpA. Axial SpA terdiri dari AS dan non radiographic axial SpA (nr-axSpA), sedangkan peripheral SpA terdiri dari PsA, ReA, IBD-SpA, Juvenile Onset SpA dan Undifferentiated Spondyloarthritis.

### 1. Axial Spondyloarthritis

Axial SpA merupakan spondyloarthritis yang melibatkan spine dan tulang axial lainnya, dengan keluhan utama nyeri pinggang disertai bukti proses inflamasi. Ax SpA juga disertai manifestasi extraarticular seperti uveitis, colitis and skin lesions. Berdasarkan Assessment of Spondyloarthritis (ASAS) kriteria diagnosis SpA berdasarkan temuan klinis dan imaging. Secara klinis SpA ditentukan dengan HLA-B27 (+) dan secara imaging ditentukan dengan ditemukannya gambaran sacroiliitis aktif pada pemeriksaan MRI. Dengan penggunaan MRI, dikenal subgroup non-radiographic SpA (nr-SpA). nr-SpA adalah LBP inflammatory back pain tanpa disertai kerusakan struktural pada pemeriksaan radiografi konvensional. Pasien-pasien nr-SpA 40% menunjukkan tanda-tanda inflamasi pada pemeriksaan MRI dan 10-20% berkembang menjadi ankylosing spondylitis dalam lebih dari 2 tahun. Tabel 1, 2 menjelaskan secara ringkas menjelaskan kriteria diagnosis klinis dan radiologis ax SpA. Tabel 3 menjelaskan definisi klinis dan radiologis SpA.

Tabel 1. Ringkasan kriteria ASAS dan nr-SpA



Tabel 2. Kriteria klinis dan radiografi AS (axSpA)

### The Modified New York Criteria (MNY) [11]

#### Clinical criteria:

- Low back pain and stiffness for more than three months that improves with exercise, but is not received by rest.
- Limitation of motion of the lumbar spine in the sagittal and frontal planes.
- Limitation of chest expansion relative to normal values correlated for age and sex.

#### Radiological criteria:

- Sacroiliitis grade > or = 2 bilaterally or 3-5 unilaterally.

Tabel 3. Definisi klinis menurut ESSG

Variable	Definition
Inflammatory spinal pain*	History or present symptoms of spinal pain in back, dorsal, or cervical region, with at least four of the following: (a) onset before age 45, (b) insidious onset, (c) improved by exercise, (d) associated with morning stiffness, (e) at least three months duration.
Synovitis	Past or present asymmetric arthritis or arthritis predominantly in the lower limbs.
Family history	Presence in first-degree or second-degree relatives of any of the following: (a) ankylosing spondylitis, (b) psoriasis, (c) acute uveitis, (d) reactive arthritis, (e) inflammatory bowel disease.
Psoriasis	Past or present psoriasis diagnosed by a doctor.
Inflammatory bowel disease	Past or present Crohn disease or ulcerative colitis diagnosed by a doctor and confirmed by radiographic examination or endoscopy.
Alternating buttock pain	Past or present pain alternating between the right and left gluteal regions.
Enthesopathy	Past or present spontaneous pain or tenderness at examination at the site of the insertion of the Achilles tendon or plantar fascia.
Acute diarrhoea	Episode of diarrhoea occurring within 1 month before arthritis.
Urethritis/cervicitis	Non-gonococcal urethritis or cervicitis occurring within one month before arthritis.
Sacroiliitis	Bilateral grade 2-4 or unilateral grade 3-4, according to the following radiographic grading system: 0 = normal, 1 = possible, 2 = minimal, 3 = moderate and 4 = ankylosis.

Secara MRI kelainan SpA pada vertebra dan sendi sacroiliaca dapat berupa kelainan struktural dan lesi inflamasi. (Tabel 4 dan 5)

Tabel 4. Temuan radiologi lesi struktural dan inflamasi pada vertebra

Corner Inflammatory Lesion (CIL)	This presents as bone marrow oedema and appears as a triangular or L shape in one quadrant of the vertebra, commonly along the anterior or posterior margin on mid sagittal imaging. Related to the entheses of the anterior and posterior longitudinal ligaments with the annulus fibrosis and the cerebral body.
Central Inflammatory Lesion	Anderson lesion, typically appears as a semi-circular area of bone marrow oedema, related to the vertebral end plate adjacent to the intervertebral discs and can be associated with erosions.
Costovertebral Joint Inflammation (CTJ)	Adjacent bone marrow oedema on the far lateral sagittal images, related to the junction of the rib and the transverse process of the adjacent thoracic vertebra. Absent at T11 and T12.
Costovertebral joint inflammation (CVJ)	Can affect any joint from T1 to T12. Circular pattern of bone marrow oedema related to the posterior intervertebral disc and middle column of the vertebral body. It can extend to the adjacent soft tissue, rib margin and posterior aspect of vertebral bodies.
Enthesitis of spinal ligaments supraspinous ligament and interspinous ligaments	Supraspinous, interspinous ligament inflammation, seen along the spinous processes in the mid sagittal slices, along the posterior elements.
Syndesmophytes/ankylosis	Manifests as a linear continuous marrow signal between vertebral bodies on MRI. May occur on para sagittal slices and not on the central sagittal imaging.

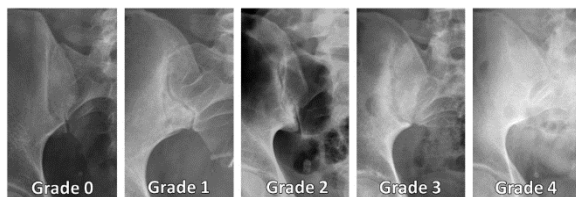
Tabel 5. Temuan radiologi lesi struktural dan inflamasi pada sendi sacroiliaca pada MRI

Erosions	Most varied in presentation. Visible on T1 images as loss of cortical bone associated with adjacent low bone marrow signal intensity. If active, manifests as a hyper intense lesion or with extensive adjacent bone marrow oedema on STIR. (Figure 2)
Fat Infiltration	Can be difficult to diagnose in young active adults with patchy marrow fat. If at least two these criteria are followed, may be easier to diagnose accurately. Juxta-articular – in contact with the articular surface. (Figure 1) Geographical – sharp margins Signal – Uniform marrow signal intensity on T1-W images.
Sclerosis	Uniform Low signal intensity on T1 and STIR imaging, in the subchondral region. (Figure 3)
Ankylosis	Continuous marrow signal intensity across the joint. Can also manifest as marrow across parallel sclerotic tram-track lines believed to be residual joint lines from previous long erosive changes affecting the SJ.

Tabel 6. Gambaran Sacroiliitis pada Pemeriksaan MRI

<b>Acute phase</b>	
– Intra-articular fluid	
– Subchondral bone marrow edema	
– Articular and periarticular post-gadolinium enhancement	
– Soft tissues edema	
<b>Chronic phase</b>	
– Periarticular bone marrow reconversion	
– Replacement of articular cartilage by pannus	
– Bone erosion	
– Subchondral sclerosis	
– Joint space widening or narrowing	
– Ankylosis	

Grading Sacroiliitis secara radiografi sbb:



Gambar 1. Radiographic grading of sacroiliitis according to the modified New York criteria. (a) Grade 0: normal findings. (b) Grade 1: suspicious

changes of questionable sclerosis or joint margin blurring. (c) Grade 2: small localized areas with erosion or sclerosis, without alteration in joint width. (d) Grade 3: unequivocal abnormality with widening, erosions, and sclerosis. (e) Grade 4: total ankylosis.

## 2. Peripheral Spondyloarthropathy

Peripheral SpA ditandai utamanya adanya inflamasi pada extremitas, entheses dan jari tanda disertai keluhan low back pain. peripheral SpA terdiri dari PsA, ReA, IBD-SpA, Juvenile Onset SpA dan Undifferentiated Spondyloarthropathy.

Tabel 7. Kriteria Klasifikasi ASA pada SpA

Axial Spondyloarthritis Criteria*	Peripheral Spondyloarthritis Criteria <sup>†</sup>
In patients with $\geq 3$ months of back pain and age at onset <45 years	In patients with <i>only</i> peripheral symptoms
Sacroiliitis at imaging plus one or more spondyloarthritis features	Arthritis or enthesitis or dactylitis <i>plus</i>
<b>Or</b>	One or more of the following spondyloarthritis features:
HLA-B27 plus two or more other spondyloarthritis features	Psoriasis
Spondyloarthritis features (SPINEACHE) <sup>‡</sup>	Crohn disease or colitis
Sausage digit (dactylitis)	Preceding infection
Psoriasis	HLA-B27
Positive family history of spondyloarthritis	Uveitis
Inflammatory back pain	Sacroiliitis on radiographs or MR images
NSAID therapy: good response	<b>Or</b>
Enthesitis (heel)	Two or more of the following spondyloarthritis features:
Arthritis	Arthritis
Crohn disease or colitis	Enthesitis
C-reactive protein level elevation	Dactylitis
HLA-B27	Inflammatory back pain in the past
Eye (uveitis)	A family history of spondyloarthritis

Note.—HLA-B27 = human leukocyte antigen B27, NSAID = nonsteroidal anti-inflammatory drug.

### 2.1. Psoriatic spondyloarthritis

Keterlibatan tulang axial pada psoriatic spondyloarthritis meliputi:

#### 2.1.1 Pada Vertebra

(a) syndesmophytes yang berbeda dari AS (nonmarginal) bulky syndesmophytes atau disebut juga para-syndesmophytes (b) involvement of the sacroiliac joints, which may be bilateral and symmetrical, or unilateral (c) sparing or modest involvement of interapophyseal joints. Syndesmophyte sering dijumpai pada thoracolumbal, bentuk linier, curvilinear, tebal dan fluffy serta parallel terhadap permukaan lateral corpus vertebra dan diskus intervertebralis. Syndesmophyte ini dapat menyatu massif membentuk seperti bridging osteophyte, tetapi biasanya terisolasi 1-2 corpus tidak memberi gambaran bamboo spine, serta unilateral.



### 2.1.2 Pada sendi sacroiliaca

Sacroiliitis psoriasis, bias tanpa disertai spondylitis memberikan gambaran: erosi (sering terjadi pada aspek iliac), osteosklerosis, penyempitan sendi, jarang terjadi ankyloses. Sering melibatkan sendi interapophyseal vertebra cervical dan kadang kadang menjadi ankyloses, jarang dijumpai anterior atlo-axial subluxation.

Tabel 8. Kriteria Klasifikasi Psoriatic Arthritis (CASPAR) 2006

To meet the CASPAR criteria, a patient must have inflammatory articular disease (joint, spine, or enthesal) with  $\geq 3$  points from the following five categories:

- Evidence of current psoriasis, a personal history of psoriasis, or a family history of psoriasis
  - Current psoriasis: defined as psoriatic skin or scalp disease present today, as judged by a rheumatologist or dermatologist
  - A personal history of psoriasis: defined as a history of psoriasis that may be obtained from a patient, family physician, dermatologist, rheumatologist, or other qualified health care provider
  - A family history of psoriasis: defined as a history of psoriasis in a first- or second-degree relative according to the patient report
- Typical psoriatic nail dystrophy, including onycholysis, pitting, and hyperkeratosis, observed at current physical examination
- A negative test result for the presence of rheumatoid factor by any method except latex but preferably by enzyme-linked immunosorbent assay or nephelometry, according to the local laboratory reference range
- Either current dactylitis, defined as swelling of an entire digit, or a history of dactylitis recorded by a rheumatologist
- Radiographic evidence of juxta-articular new bone formation, appearing as ill-defined ossification near joint margins (but excluding osteophyte formation) on radiographs of the hand or foot

### 2.2 Reactive spondyloarthritis (Reiter's syndrome)

Reiter's syndrome adalah sindroma klinis yang ditandai conjunctivitis, urethritis atau gastroenteritis, dan diikuti onset aseptic arthritis setelah interval 1-4 minggu. Keterlibatan appendicular skeleton ditandai asymmetrical oligoarthritis, biasanya unilateral, dengan predileksi pada sendi synovial besar pada extremitas bawah. Keterlibatan sendi sacroiliaca pada awal 5-10% sedangkan pada fase lanjut dapat mencapai 40-60%. Gambaran sacroiliitis pada Reiter's syndrome hampir sama dengan psoriatic sacroiliitis.

Keterlibatan pada vertebra juga menunjukkan gambaran yang hamper sama dengan Psoriatic SpA.

### 2.3 Enteropathic spondyloarthritis (enteroarthritis)

Kondisi ini berhubungan dengan 2 bentuk Inflammatory Bowel Disease yaitu ulcerative colitis dan Crohn's disease, dengan manifestasi extraintestinal berupa axial dan peripheral arthritis. Manifestasi peripheral arthritis berupa oligoarticular, asymmetrical, sering transient dan

berpindah-pindah, melibatkan sendi besar maupun kecil, terutama pada extremitas bawah. Manifestasi axial skeleton berupa spondylitis dan sacroiliitis mirip dengan gambaran ankylosing spondylitis primitive.

### 2.4 SAPHO syndrome

Sindroma ini meliputi synovitis, acne, pustulosis, hyperostosis dan osteitis. Osteitis berupa reactive osteitis. Pada SAPHO syndrome melibatkan axial skeleton dan enthesis, dengan seronegative dan dapat disertai gejala psoriasis dan enteroarthritis yang diduga berkaitan dengan SpA. Tulang yang sering terlibat adalah regio sterno-costo-clavicular (70-90 %), spine (30 %) dan sendi sacroiliac (13-52 %). Pada fase awal osteitis yang tampak berupa focal osteosclerosis yang disertai erosi pada tulang dan korteks serta edema soft tissue.

Fase selanjutnya akan dijumpai hyperostosis (diffuse osteosclerosis dengan penambahan volume) dan synovitis. Synovitis yang terjadi merupakan akibat primer maupun sekunder dari perluasan intraartikuler dari osteoitis didekatnya. Synovitis sering dijumpai pada sendi sacroiliac, biasanya unilateral, serta pada sendi sterno-costo-clavicular. Sedangkan vertebra yang sering terlibat adalah anterior vertebral corners vertebra thoracolumbal.

### Simpulan

Radiografi konvensional masih merupakan modalitas pilihan dalam mengevaluasi awal dan follow up pasien dengan sacroiliitis. MRI berperan dalam mendiagnosis perubahan awal dan aktifitas inflamasi, sedangkan CT scan unggul dalam menilai perubahan kronik.

### Pustaka

- Ramdin D, Moorthy A, Rennie WJ. Classification Terminology and Definitions in Reporting of MRI in Axial Spondyloarthritis. Journal of the Belgian Society of Radiology. 2017; 101(S2): 11, 1-7.
- Tsoi C, Griffith JF, Lee RKL, Wong PCH, Tam LS. Imaging of sacroiliitis: Current status,



- limitations and pitfalls. *Quant Imaging Med Surg* 2019;9(2):318-335
3. Paparo F, Revelli M, Semprini A, Campellino D, Cimmino MA, Garlaschi A, et al. Seronegative spondyloarthropathies: what radiologists should know. *Radiol med* 2013. DOI 10.1007/s11547-013-0316-5
  4. de Castro Jr. MR, Mitraud SAV, Francisco MC, Fernandes ARC, Fernandes EA. Spondyloarthropathy: diagnostic imaging criteria for the detection of sacroiliitis. *Radiol Bras*. 2017;50(4):258-262
  5. Eric Y. Chang EY, Chen KC, Huang BK, Kavanaugh A. Adult Inflammatory Arthritides: What the Radiologist Should Know. *RadioGraphics* 2016; 36:1849-1870
  6. Robinson PC, Sengupta R, Siebert S. Non-Radiographic Axial Spondyloarthritis (nr-axSpA): Advances in Classification, Imaging and Therapy. *Rheumatol Ther* (2019) 6:165-177
  7. Montandon C, Costa MAB, Carvalho TN, Montandon Júnior ME, Teixeira KS. Sacroiliitis: Imaging Evaluation. *Radiol Bras* 2007;40(1):53-60