

Effect of Carbogen to Chemoradiation in Volume of Rectal Cancer

by Hermina Sukmaningtyas

Submission date: 14-Jul-2020 11:55AM (UTC+0700)

Submission ID: 1357294553

File name: 30_Turnitin.pdf (371.58K)

Word count: 3519

Character count: 19586

Effect of Carbogen to Chemoradiation in Volume of Rectal Cancer

Christina Hari Nawangsih¹, Soehartati Gondhowiardjo², Sofia Mubarika Haryana³, Soeharyo Hadisaputro⁴, Catharina Suharti⁴, Edi Dharmana⁵, Hermina Sukmaningtyas¹, Fifi Luthfia Rahmi⁶, Ignatius Riwanto^{7,8}

¹ Department of Radiology, Faculty of Medicine, Diponegoro University, Semarang, Indonesia

² Department of Radiology, Faculty of Medicine, Universitas Indonesia, Jakarta, Indonesia

³ Department of Histology, Faculty of Medicine, Universitas Gadjah Mada, Yogyakarta, Indonesia

⁴ Department of Internal Medicine, Faculty of Medicine, Diponegoro University, Semarang, Indonesia

⁵ Department of Parasitology, Faculty of Medicine, Diponegoro University, Semarang, Indonesia

⁶ Department of Ophthalmology, Faculty of Medicine, Diponegoro University, Semarang, Indonesia

⁷ Department of Surgery, Faculty of Medicine, Diponegoro University, Semarang, Indonesia

⁸ Kariadi General Hospital, Semarang, Indonesia

Received: 11 Aug. 2019; Accepted: 03 Jan. 2020

Abstract- The outcome of inoperable rectal cancer treatment by chemotherapy, radiotherapy, and targeted therapy are still unfavorable. Carbogen is a combination of 98% oxygen and 2% carbon dioxide proven effective as chemoradiosensitizer. The aim of this study is to know the effect of concurrent carbogen and chemoradiotherapy in locally advanced rectal cancer by measuring the shrinkage of the tumor volume. The design of this study was *randomized true experimental 2 groups pre and post-test-controlled design*. Samples were patients with locally advanced rectal cancer. MRI of the pelvis before and 4-8 weeks after the chemoradiation were examined. A total of 28 subjects were randomized to 14 patients who received concurrent chemoradiation with carbogen (treatment group) and 14 patients chemoradiation (control) The tumor shrinkage in the treatment group (13.08 to 6.08 cm³) was significantly higher compared to the control group (18.00 to 12.83 cm³). Supplementation of carbogen to standard treatment chemoradiation for locally advanced rectal cancer significantly shrinkage the tumor volume.

© 2020 Tehran University of Medical Sciences. All rights reserved.

Acta Med Iran 2020;58(1):15-20.

Keywords: Rectal cancer; Carbogen; Chemoradiation; Volume

Introduction

Rectal cancer is the eighth most common cancer worldwide and also in Indonesia, according to the latest GLOBOCAN (1). Reliable statistics on deaths from colon and rectal cancers separately were not available due to 40% of deaths from rectal cancer are misclassified as colon cancer on death certificates (2). In 2017, there will be an estimated 39,910 cases of rectal cancer diagnosed in the US (3). About 43% of rectal cancer patients were diagnosed during an early stage with life expectancy 67%, and more than 50% were diagnosed at locally advanced (4). Surgery alone in rectal cancer treatment has resulted in a 25% local failure rate and 40 to 50% long-term survival for T3/T4 with positive lymph node, whereas adding chemoradiation still local failure rates of 10 to 15% and long-term survival rates of 50 to 60% (5). reduce life

expectancy to be 47-65 % on stage III and 6-48% on stage IV (6). There is no data on rectal cancer life expectancy in Indonesia until nowadays.

Chemoradiation is the standard therapy for inoperable locally advanced rectal cancer before surgery. Chemotherapy, given together with radiation, aims to increase the effectiveness of radiation (7,8). Improving surgical technique by using the concept of total excision of the mesorectum rectal cancer patient has improved the outcome. However, the risk of local relapse is still 5-20% (9,10), while preoperative chemoradiation with capecitabine achieved pathologic complete response in 16-28%, and 39-50% downstaging of patients (11).

Many efforts have been given to improve the effectiveness of chemoradiation, *i.e.*, preoperative chemoradiation by using capecitabine and oxaliplatin. The result was not significantly improved even though

Corresponding Author: C.H. Nawangsih

Department of Radiology, Faculty of Medicine, Diponegoro University, Semarang, Indonesia
Tel: +62 24 8312017, Fax: +62 24 76928010, E-mail address: cnawangsih@yahoo.com

Effect of carbogen to chemoradiation

there is a higher side effect from radiation with capecitabine and oxaliplatin, and pathologic complete response was 19.2% compared to 13.9% for patients with chemoradiation only (12). Preoperative chemoradiation capecitabine with targeted therapy bevacizumab showed pathologic complete response in 25% patients and 37.5% downstaging, with adverse effect, *i.e.*, grade 3 intestinal bleeding (in 25% of patients), diarrhea (25%), perianal pain (25%) and anemia (12.5%) (13).

Tumor hypoxia has been considered the cause of radiotherapy failure. Oxygen is necessary for free radicals such as hydroxyl radicals (-OH), hydrated electrons, hydrogen atoms (H+), and hydrogen peroxide (H₂O₂) caused by radiation to facilitate the free radicals entering the nucleus and disrupting the DNA. The free radicals from peroxides resulting in cell death or apoptosis (14,15). In the absence of oxygen, DNA can be restored to its preirradiated condition by hydrogen donation from endogenous antioxidants causing bad tissue response from radiation (14,16,17). Improving oxygen concentration in tumor tissue by using hyperbaric oxygen (HBO) was evidently beneficial; however, the application of HBO concurrently with radiotherapy is not yet available (18,19).

Carbogen, a gas combination of oxygen 98% and carbon dioxide 2%, has been investigated as a modulator of hypoxia in the tumor models. Carbogen is simple and easy to be administered simultaneously with fractionated radiotherapy and could improve tumor oxygenation by increasing the amount of dissolved oxygen in plasma and raise the systemic blood pressure. The study showed that (chemo) radiation combined with carbogen as radiosensitizer and nicotinamide as a vasodilator is effective in increasing response therapy and safe as a cervical cancer treatment (20). This idea was supported by a study on the mouse sarcoma model showing that concurrent 6 liters/hour of carbogen for 5-15 minutes during radiation treatment increased tumor oxygenation and radiation response (21).

The aim of this study is to evaluate the effectiveness of supplementation carbogen ²⁰in vivo as chemoradiosensitizer to standard chemoradiation in locally advanced rectal cancer by measuring the shrinkage of the tumor volume.

Materials and Methods

This study was a clinical randomized controlled trial using pre and post-test design comparing the effect of carbogen supplementation on the shrinkage of the tumor

²⁰ volume in locally advanced rectal cancer patients treated with standard chemoradiation. All the stage II and III rectal cancer patients that had not yet undergone the surgical resection were randomly grouped as treatment group or control group. All the participants' age ranged from 18 to 70-year-old with clinical stage II and III rectal cancer with normal hemoglobin level (minimum 10 gr%), had a good physical examination, and were eligible for MRI examination. While the exclusion criteria were patients that underwent resection directly or presented with metastatic disease or exhibited disease recurrence, had distant metastasis, had an allergy to capecitabine, and had radiotherapy interruption more than 1 month. Ethical clearance was obtained from The Medical Research Ethical Committee of the Faculty of Medicine Diponegoro University and Dr. Kariadi General Hospital. All participants gave written informed consent in accordance with Institutional Review Board guidelines.

The treatment group received standard chemoradiation with carbogen, while the control group received only standard chemoradiation. Carbogen with flow 8 liters per minute was given through facemask for 10-11 minutes, starting 4 minutes before the radiation and continued during the radiation in the treatment room. Radiation with dose 2 Gy/fraction was given with a total dose of 50Gy. Capecitabine 825 mg/m² orally was given during the radiation and followed by repeated capecitabine 1250 mg/m²/day for 2 weeks, followed by one week without capecitabine until MRI examination. The outcome of the therapy response was measured by the shrinkage of tumor volume on 4-8 weeks after complete chemoradiation among two groups.

MRI examination was done before and after the treatment to measure the tumor volume using Modified Response Evaluation Criteria in Solid Tumors (RECIST) 1.1. on a treatment planning system, Eclipse® (Varian) tools. The percentage shrinkage of tumor volume was the difference between volume tumor pre-irradiation with post-irradiation divided by pre-irradiation volume X 100% (22).

Data were analyzed using SPSS, version 20.0 for Windows (SPSS Inc., and Chicago, Illinois, USA). The level of significance was pre-set at 0.05. Normally distributed variables were summarized using means and standard deviations (SD), while skewed data in volume were reported as median and inter-quartile range and statistical analysis was done using non-parametric chi-square and Mann-Whitney. Categorical variables were presented using proportions and percentages.

Results

A total of 40 patients with locally advanced rectum cancer were enrolled in this study from February 2017 - December 2018. However, twelve patients were excluded from the current study (two patients exhibited metastasis, three patients showed progressive disease, one patient exhibited capecitabine allergy, and six patients had no MRI data due to emergency radiation indicated by tumor bleeding. A total of 28 (15 males and 13 females) patients with locally advanced rectum cancer were included in this study. There were no adverse effects, *i.e.*, dyspnea, nausea, vomitus, and diarrhea during chemoradiation in both groups. A delay to treatment time more than 15 days was unexpectedly occurred due to anemia in three patients in the treatment group and five patients in the control group. The

characteristic of the patients was displayed in table 1.

The shrinkage of the tumor volume, as the main therapy response, was obtained in the majority of patients in the treatment group. Both groups showed significant shrinkage of tumor volume after the treatment, as shown in Table 2. The shrinkage of the tumor volume in the control group was significantly lower compared to the treatment group ($P=0.024$). Furthermore, the tumor volume after the treatment was significantly lower in the treatment group (Figure 1 and Table 2).

Only one patient (6.7%) from the treatment group achieved complete response while none from the control group. Furthermore, there were more patients who had a partial response in the treatment group (60%) compared to the control group (40%), as described in Table 3.

Table 1. Characteristics of the patients

		Treatment Group (n=14)	Control Group (n=14)	P
Sex n (%)	Male	7 (50.0%)	8 (57.1%)	1.000 ^a
	Female	7 (50.0%)	6 (42.9%)	
Age (years)		52.14 ± 12.08	45 ± 11.79	0.153 ^b
Histopathology of the cancer n (%)	Well differentiated Adenocarcinoma	11 (78.6%)	6 (42.9%)	
	Moderate differentiated Adenocarcinoma	2 (14.3%)	5 (35.7%)	0.149 ^c
	Mucinous adenocarcinoma	1 (7.1%)		
	Clear cell carcinoma Signet cell carcinoma		2 (14.3%) 1 (7.1%)	
Hemoglobin		12.74 ± 1.10	12.06 ± 1.09	0.376 ^b
Overall Treatment Time (OTT)		43.71 ± 9.77	43.86 ± 9.01	0.968 ^b

^aFischer's Exact test, ^bindependent t-test, ^cChi-square test

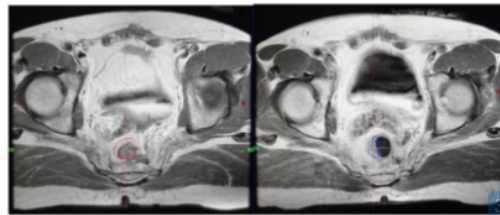


Figure 1. MRI imaging of pre (red circle) and post (blue circle) chemoradiation with carbogen inpatient with locally advanced rectal cancer.

Table 2. The tumor volume difference between groups before and after the treatment

Tumor Volume, Median (min-max) cm ³	Treatment Group (n=14)	Control Group (n=14)	P
• Pre Chemoradiation	12.73 (2.88-26.16)	15.37 (1.78 – 53.44)	0.198 ^a
• Post Chemoradiation	3.41; 0.1-23.57	10.28 (1.68-39.19)	0.046 ^a
P	0.001 ^b	0.116 ^b	
Shrinkage Volume (%)	63.53 (1.71-97.91)	30.03 (-150.50 – 78.50)	0.024 ^a

^a Mann-Whitney test; ^bWilcoxon test

Table 3. Treatment Response.

Treatment Response	Treatment Group (n=14)	Control Group (n=14)
Complete Response	1 (6.7%)	0
Partial Response	9 (60%)	5 (40%)
No Response	4 (26.7%)	8 (53.3%)
Progressive	0	1 (6.7%)

Discussion

Preoperative chemoradiotherapy is the standard treatment in rectal cancer with the mesorectal or surrounding organ involvement. In our institution, the standard chemoradiotherapy is external radiotherapy with a total dose of 50 Gy within 25 fractions, delivered concurrently with capecitabine (7,8). Tumor volume shrinkage is one of the successful indicators in response to radiotherapy (22). In the present study, we found that the treatment group exhibits a significant shrinkage of tumor volume compared to the control group.

Increased chemoradiotherapy response was provided by adding carbogen in rectal cancer patients who received standard chemoradiotherapy. To our knowledge, this is the first study of the effect of carbogen as an adjuvant in radiotherapy for locally advanced rectal cancer. Several studies using carbogen and nicotinamide were performed in cervical cancer, bladder cancer, colorectal cancer, and head and neck cancer. The addition of carbogen and nicotinamide in radiotherapy showed the improvement of the treatment response, especially in patients that have a contraindication for chemotherapy. Therapy with carbogen and nicotinamide was safe, although, some patients exhibited the nicotinamide intolerance (10,19,20). Nausea and vomiting appeared in patients who underwent head and neck radiation in conjunction with nicotinamide (23). Our study showed a significantly higher tumor volume shrinkage in the treatment group without additional toxicity. Subjects were comfortable after underwent chemoradiotherapy with additional carbogen, as also shown in several previous studies (20,24).

Various efforts have been made to improve radiotherapy response, such as oral 5-Fluorouracil (5-FU) chemotherapy administration (11,25). An oxygen diffusion modifier by carbogen administration and tissue perfusion enhancer by drugs such as nicotinamide were also performed to improve the radiotherapy response (19,20). Another modality that was shown to be effective in improving radiotherapy response was anemia correction (26). Carbogen has been reported to

modulate a re-oxygenation event that resulted in an increased radiation response during radiotherapy (27). Apoptosis due to single-strand breaks (SSBs) and double-strand breaks (DSBs) of DNA was postulated as the effect of radiation that improved with carbogen administration (27,28). In the presence of DNA damage response (DDR), DNA damage due to reactive free radical occurred by radiation were fixed by oxygen and resulted in cell death, which is the target of cancer treatment (29). Fractionated irradiation with carbogen supplementation, may reduce the tumor volume, and also increase the tumor blood flow and facilitate drug access to the tumor (30).

Capecitabine is a prodrug of 5-FU, is a well-known radiosensitizer that can be given together with radiation to increase radiation sensitivity. The incorporation of 5-FU into DNA and RNA as fluorodeoxyuridine contributes to its cytotoxicity (31). 5-FU inhibits thymidylate synthase and depletes the pool of nucleotide triphosphates, leading to cell cycle redistribution, DNA fragmentation, and cell death. Radiosensitization also correlates with a decrease in the rate and extent of repair of radiation-induced DSB and the susceptibility to radiation (30). Indeed, the reduction in tumor volume after treatment with multimodality may result in improved blood supply to the tumor, leading to reoxygenation of the tumor and increased radiosensitivity and chemosensitivity. This study becomes relevant because most of the patients came in a locally advanced stage, and the recurrence rate after treatment is still high.

Our study limitations were the small sample size and a long waiting time for MRI examination, on average, 1 month. However, we managed to perform the MRI examination before chemoradiation and 4 until 8 weeks after chemoradiation. A further study to determine the survival rate and disease recurrences is needed.

In summary, carbogen represents a great opportunity to increase chemoradiation responses. The administration of supplementation carbogen and chemoradiation in rectal cancer was safe and significantly reduced the tumor volume in locally advanced rectal cancer.

Acknowledgments

We thank H. Kodrat and D. Respatika for technical support in manuscript editing, M. Nuriya for helping in the MRI interpretation, and all the Therapeutic Radiographers for delivering the radiation therapy to the patients.

References

1. Bray F, Ferlay J, Soerjomataram I. Global Cancer Statistics 2018: GLOBOCAN Estimates of Incidence and Mortality Worldwide for 36 Cancers in 185 Countries. *CA Cancer J Clin* 2018;68:394-424.
2. Yin D, Morris CR, Bates JH, German RR. Effect of Misclassified Underlying Cause of Death on Survival Estimates of Colon and Rectal Cancer. *J Natl Cancer Inst* 2011;103:1-4.
3. American Cancer Society. Colorectal Cancer Facts & Figures 2017-2019. Atlanta: American Cancer Society, 2017.
4. Siegel RL, Miller KD, Fedewa SA, Ahnen DJ, Meester RGS, Barzi A, et al. Colorectal cancer statistics, 2017. *CA Cancer J Clin [Internet]* 2017;67:177-93.
5. Willett CG, Czito BG. Neoadjuvant Chemoradiation for Rectal Cancer. *Seminars in Colon and Rectal Surgery*. Elsevier Inc 2008;19:197-202.
6. Wang SJ, Fuller CD, Emery R, Thomas CR. Conditional Survival in Rectal Cancer: A SEER Database Analysis. *Gastrointest Cancer Res* 2007;1:84-9.
7. Menteri Kesehatan Republik Indonesia. National Guidelines For Colorectal Cancer Health Care. *Pedoman Nasional Pelayanan Kesehatan Kanker Kolorektal*. 1st ed. Jakarta: Kementerian Kesehatan Republik Indonesia, 2017.
8. National Comprehensive Cancer Network.org. Rectal Cancer [Internet]. USA: National Comprehensive Cancer Network, 2018.
9. Adam JJ, Mohamdee MO, Martin IG, Scott N, Finan PJ, Johnston D, et al. Role of circumferential margin involvement in the local recurrence of rectal cancer. *Lancet* 1994;344:707-11.
10. Ais Conde G, Fadrique Fernández B, Vázquez Santos P, López Pérez J, Picatoste Merino M, Manzanares Sacristán J. Rectal cancer: Which patients benefit from radiotherapy. *Cirugía Española (English Ed [Internet])*. Elsevier 2010;87:350-5.
11. Bedi M, Das P, Skibber JM, Rodriguez-Bigas MA, Chang GJ, Eng C, et al. Capecitabine and timing of radiotherapy during preoperative chemoradiation for rectal cancer. *Gastrointest Cancer Res* 2007;1:44-8.
12. Gérard J-P, Azria D, Gourgou-Bourgade S, Martel-Laffay I, Hennequin C, Etienne P, et al. Comparison of Two Neoadjuvant Chemoradiotherapy Regimens for Locally Advanced Rectal Cancer: Results of the Phase III Trial ACCORD 12/0405-Prodige 2. *J Clin Oncol* 2010;28:1638-44.
13. Wong SJ, Winter K, Meropol NJ, Anne PR, Kachnic L, Rashid A, et al. Radiation Therapy Oncology Group 0247: a randomized Phase II study of neoadjuvant capecitabine and irinotecan or capecitabine and oxaliplatin with concurrent radiotherapy for patients with locally advanced rectal cancer. *Int J Radiat Oncol Biol Phys* 2012;82:1367-75.
14. Leonard GL, Tepper JE. *Clinical Radiation Oncology*. In: Gunderson L, Leonard; Tepper E, Joel, eds. *Clinical Radiation Oncology*. 4th ed. Philadelphia: Elsevier Inc, 2016:6-30.
15. William C Dewey JSB. radiobiologic principles. In: Phillips L, eds. *Textbook of Radiation Oncology*. 2nd ed. Philadelphia: Saunders Elsevier Inc, 2004:3-76.
16. Edward C. Halperin, David E. Wazer, Carlos A. Perez LWB, eds. *Perez and Brady's Principles and Practice of Radiation Oncology*. 7th ed. Philadelphia: Wolters Kluwer, 2018:282-300.
17. G. Gordon Steel. Clonogenic Cells and the concept of cell survival. In: Steel GG, editor. *Basic Clinical Radiobiology*. 2nd ed. New York: Oxford University Press Inc, 1997:40-51.
18. Moen I, Stuhr LEB. Hyperbaric oxygen therapy and cancer—a review. *Target Oncol* 2012;7:233-42.
19. Hoskin PJ, Rojas AM, Bentzen SM, Saunders MI. Radiotherapy with concurrent carbogen and nicotinamide in bladder carcinoma. *J Clin Oncol* 2010;28:4912-8.
20. van Weelden WJ, Sekarutami SM, Bekkers RLM, Kaanders JH, Bussink J, Gondhowiardjo S, et al. The effect of carbogen breathing and nicotinamide added to standard (chemo)radiation treatment of advanced cervical cancer in Indonesia. *Int J Gynecol Cancer* 2014;24:1628-35.
21. Zhan HW, Liu HB, Bao CK, Ye XJ, Zhang H, He GQ. Effect of carbogen on tumour oxygenation and ³²P-colloid interstitial irradiation response. *Med Sci Monit* 2010;16:11-6.
22. Ramaiya NH, Ad A. Revised RECIST Guideline Version 1.1: What Oncologists Want to Know and What Radiologists Need to Know. *AJR* 2010;195:281-9.
23. Zackrisson B, Franzén L, Henriksson R, Littbrand B, Dennis M, Rojas AM, et al. Acute Effects of Accelerated Radiotherapy in Combination with Carbogen Breathing and Nicotinamide Arcon With Carbogen Breathing And Nicotinamide ARCON. *Acta Oncol* 2009;33:377-81.
24. Alonzi R, Padhani AR, Maxwell RJ, Taylor NJ, Stirling

Effect of carbogen to chemoradiation

- JJ, Wilson JI, et al. Carbogen breathing increases prostate cancer oxygenation : a translational MRI study in murine xenografts and humans. *Br J Cancer* 2009;100:644-8.
25. Resch G, Vries A De, Öfner D, Eisterer W, Rabl H. Preoperative treatment with capecitabine, bevacizumab and radiotherapy for primary locally advanced rectal cancer – A two stage phase II clinical trial q. *Radiother Oncol* 2012;102:10-3.
26. Louis B, Harrison, Manjeet Chadha, Richard J. Hill, Hu, Kenneth, Daniel S. Impact of Tumor Hypoxia and Anemia on Radiation Therapy Outcomes. *Oncologist* 2002;7:492-508.
27. Schuurin J, Bussink J, Bernsen HJJA, Peeters W, Van Der Kogel AJ. Effect of carbogen breathing on the radiation response of a human glioblastoma xenograft: Analysis of hypoxia and vascular parameters of regrowing tumors. *Strahlenther Onkol* 2006;182:408-14.
28. Wang L, Gao S, Jiang W, Luo C, Xu M, Bohlin L, et al. Antioxidative dietary compounds modulate gene expression associated with apoptosis, DNA repair, inhibition of cell proliferation and migration. *Int J Mol Sci* 2014;15:16226-45.
29. Tian H, Gao Z, Li HZ, Zhang BF, Wang G, Zhang Q, et al. DNA damage response - A double-edged sword in cancer prevention and cancer therapy. *Cancer Lett.* 2015;358:8-16.
30. Hennequin C, Favaudon V. Biological basis for chemo-radiotherapy interactions. *Eur J Cancer* 2002;38:223-30.
31. Miura K, Kinouchi M, Ishida K, Fujibuchi W, Naitoh T, Ogawa H, et al. 5-FU metabolism in cancer and orally-administrable 5-FU drugs. *Cancers (Basel)* 2010;2:1717-30.

Effect of Carbogen to Chemoradiation in Volume of Rectal Cancer

ORIGINALITY REPORT

19%

SIMILARITY INDEX

12%

INTERNET SOURCES

15%

PUBLICATIONS

10%

STUDENT PAPERS

PRIMARY SOURCES

- 1** C. Hennequin, V. Favaudon. "Biological basis for chemo-radiotherapy interactions", European Journal of Cancer, 2002
Publication 3%
- 2** bmccancer.biomedcentral.com
Internet Source 2%
- 3** clincancerres.aacrjournals.org
Internet Source 1%
- 4** www.bartleby.com
Internet Source 1%
- 5** hdl.handle.net
Internet Source 1%
- 6** Christopher G. Willett, Brian G. Czito. "Neoadjuvant Chemoradiation for Rectal Cancer", Seminars in Colon and Rectal Surgery, 2008
Publication 1%
- 7** Hennequin, C.. "Biological basis for chemo-

radiotherapy interactions", European Journal of
Cancer, 2002

Publication

1%

8

www.nature.com

Internet Source

<1%

9

faculty.psau.edu.sa

Internet Source

<1%

10

Miriam Marangon, Vittorio Stefoni, Alessia
Castellino, Carlo Visco et al. "Lenalidomide
Combination Therapy in Relapsed/Refractory
Diffuse Large B Cell Lymphoma: The Italian
Real-Life Experience", Clinical Lymphoma
Myeloma and Leukemia, 2019

Publication

<1%

11

Submitted to Sheffield Hallam University

Student Paper

<1%

12

www.mdpi.com

Internet Source

<1%

13

www.ema.europa.eu

Internet Source

<1%

14

Submitted to Queen's University of Belfast

Student Paper

<1%

15

epubs.surrey.ac.uk

Internet Source

<1%

16

Submitted to Mid-America Christian University

17

studylibfr.com

Internet Source

<1%

18

Submitted to Universiti Brunei Darussalam

Student Paper

<1%

19

D. Hess. "Capecitabine and vinorelbine in elderly patients (≥ 65 years) with metastatic breast cancer: a phase I trial (SAKK 25/99)", *Annals of Oncology*, 12/01/2004

Publication

<1%

20

www.ncbi.nlm.nih.gov

Internet Source

<1%

21

Diandra N Ayala, Suzanne M Russo, A William Blackstock. "Multidisciplinary treatment of resectable rectal cancer", *Expert Review of Gastroenterology & Hepatology*, 2014

Publication

<1%

22

www.jcancer.org

Internet Source

<1%

23

Dietmar Öfner, Alexander F. DeVries, Renate Schaberl-Moser, Richard Greil et al. "Präoperative kombinierte Radiochemotherapie mit Oxaliplatin und Capecitabin beim lokal fortgeschrittenen, primär operablen, cT3NxM0,

<1%

tiefen Rektumkarzinom – eine Phase-II-Studie", Strahlentherapie und Onkologie, 2011

Publication

24

www.oncotarget.com

Internet Source

<1%

25

Submitted to Leiden University

Student Paper

<1%

26

Submitted to University of St Andrews

Student Paper

<1%

27

jgo.amegroups.com

Internet Source

<1%

28

Verstraete Maud, Debucquoy Annelies, Sagaert Xavier, Van Eric, Haustermans Karin. "Anti-Angiogenic Therapy Combined with Chemoradiotherapy for Patients with Localized Advanced Rectal Cancer", Advances in Cancer: Research & Treatment, 2013

Publication

<1%

29

"GASTROINTESTINAL CANCERS", Cancer Investigation, 2009

Publication

<1%

30

journals.sagepub.com

Internet Source

<1%

31

Vermeer, Thomas A., Miranda Kusters, and Harm J. T. Rutten. "T4 Rectal Cancer: Do We

<1%

Always Need an Exenteration?", Recent Results in Cancer Research, 2014.

Publication

32

Pelvic Cancer Surgery, 2015.

Publication

<1%

33

Vaneja Velenik. "Neoadjuvant capecitabine, radiotherapy, and bevacizumab (CRAB) in locally advanced rectal cancer: results of an open-label phase II study", Radiation Oncology, 2011

Publication

<1%

34

"Combination chemotherapy versus single-agent chemotherapy during preoperative chemoradiation for resectable rectal cancer", Cochrane Database of Systematic Reviews, 2015.

Publication

<1%

35

Klaassen, R.A.. "Treatment of locally advanced rectal cancer", Surgical Oncology, 200408/11

Publication

<1%

36

Claus Rödel, Dirk Arnold, Heinz Becker, Rainer Fietkau et al. "Induktionschemotherapie vor Radiochemotherapie und Operation beim lokal fortgeschrittenen Rektumkarzinom: Zeit für eine randomisierte Phase-III-Studie?", Strahlentherapie und Onkologie, 2010

Publication

<1%

Exclude quotes On

Exclude matches Off

Exclude bibliography On

Effect of Carbogen to Chemoradiation in Volume of Rectal Cancer

GRADEMARK REPORT

FINAL GRADE

/0

GENERAL COMMENTS

Instructor

PAGE 1

PAGE 2

PAGE 3

PAGE 4

PAGE 5

PAGE 6
